MESA 4 | **REPERCUSIONES SISTÉMICAS DE LAS INFECCIONES CARDIOVASCULARES**

Moderadores:

Antonio Ramos
Hospital Universitario Puerta de Hierro, Madrid

Josune Goikoetxea
Hospital Universitario Cruces, Bilbao

17.50 a 18.10 h | **El riñón y la endocarditis infecciosa**
Eduardo Verde
Hospital Universitario Gregorio Marañón, Madrid

18.10 a 18.30 h | **El sistema nervioso central y la endocarditis infecciosa**
César Aristides de Alarcón
Hospital Universitario Virgen del Rocío, Sevilla

18.30 a 18.50 h | **PET, infección cardiovascular y metástasis a distancia**

FDG PET/CT

Mª José García Velloso
Servicio de Medicina Nuclear
Clínica Universidad de Navarra

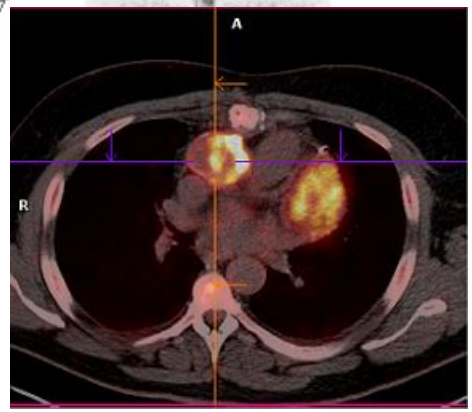

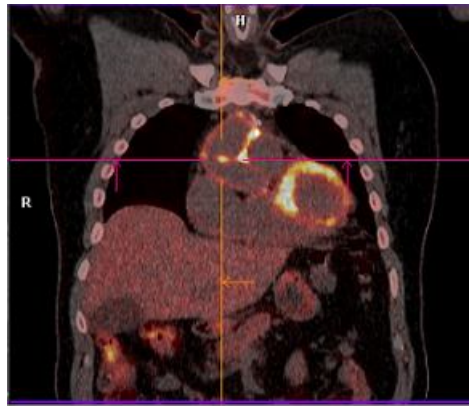

Fukuchi K, Journal of vascular surgery 2005

Detection of aortic graft infection by FDG-PET: Comparison with CT findings

CT

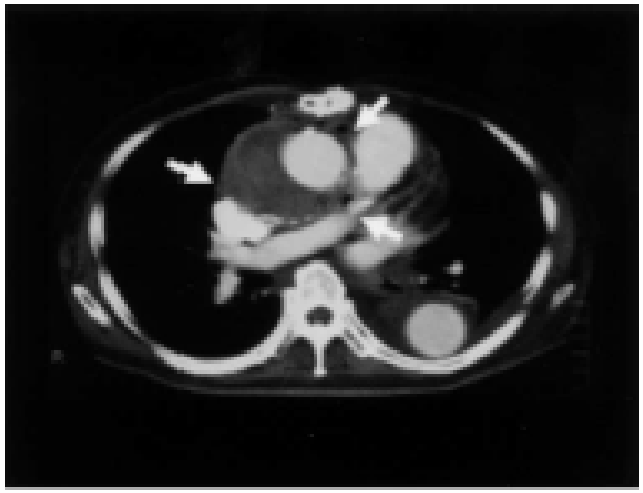

FDG-PET

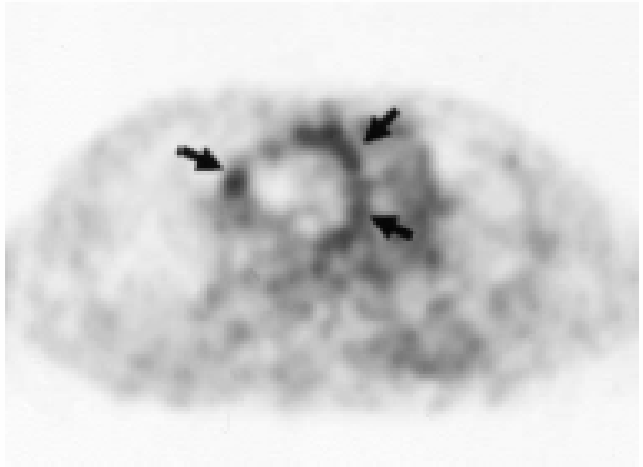

Table III. Diagnostic performances of CT and FDG-PET for differentiation between infected and noninfected vascular grafts

		Visual assessment of FDG-PET	
Variable	*CT findings*	*Positive/negative*	*Focal/not*
Sensitivity	0.64 (0.48-0.80)	0.91 (0.81-1.00)*	0.91 (0.81-1.00)*
Specificity	0.86 (0.74-0.98)	0.64 (0.48-0.80)	0.95 (0.88-1.02)†
Accuracy	0.79 (0.65-0.93)	0.73 (0.58-0.88)	0.94 (0.86-1.02)
PPV	0.70 (0.54-0.86)	0.56 (0.39-0.73)	0.91 (0.81-1.01)‡
NPV	0.83 (0.70-0.96)	0.93 (0.84-1.02)	0.95 (0.88-1.02)

Keidar Z. J Nucl Med 2007

Prosthetic Vascular Graft Infection: The Role of ^{18}F-FDG PET/CT

Bypass femoro-poplíteo

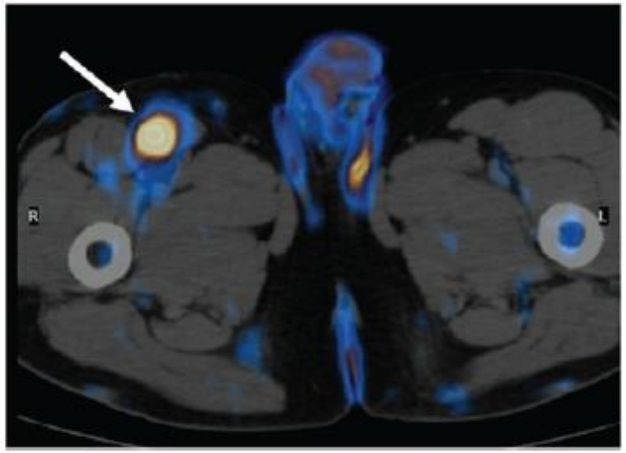

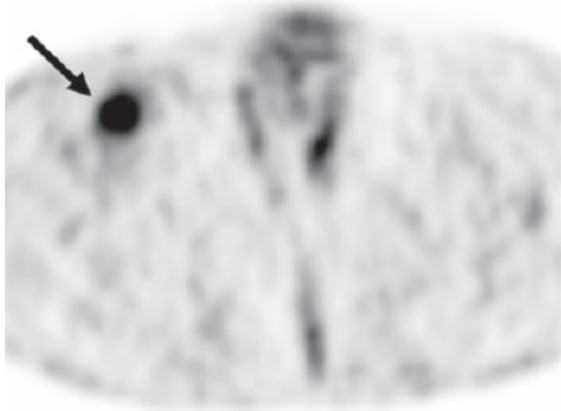

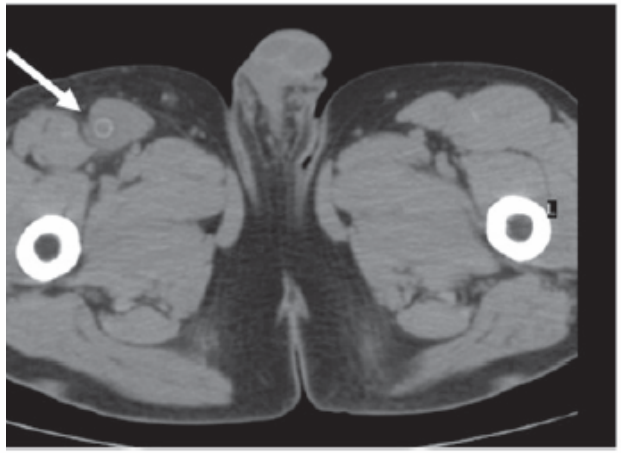



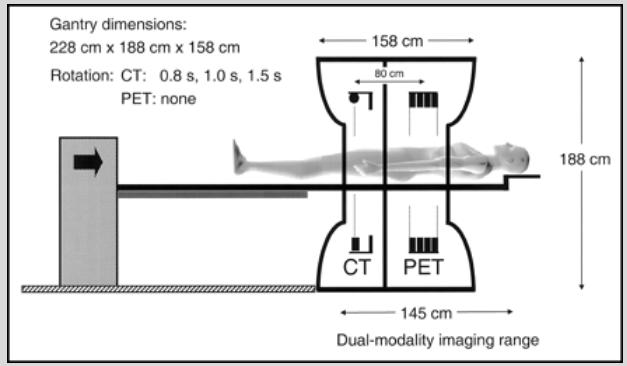

Keidar Z. J Nucl Med 2007

Prosthetic Vascular Graft Infection: The Role of ^{18}F-FDG PET/CT

Bypass femoro-poplíteo

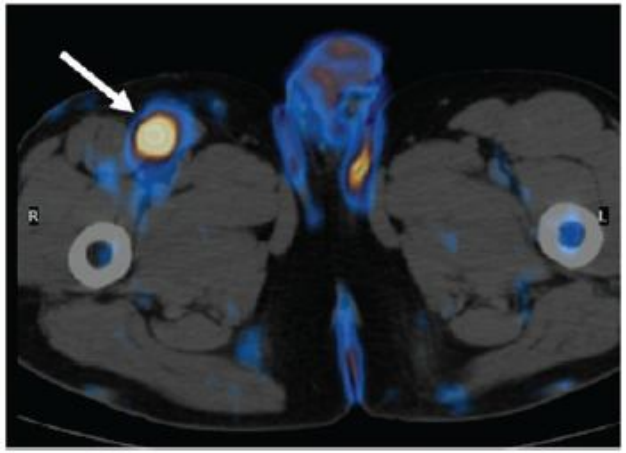

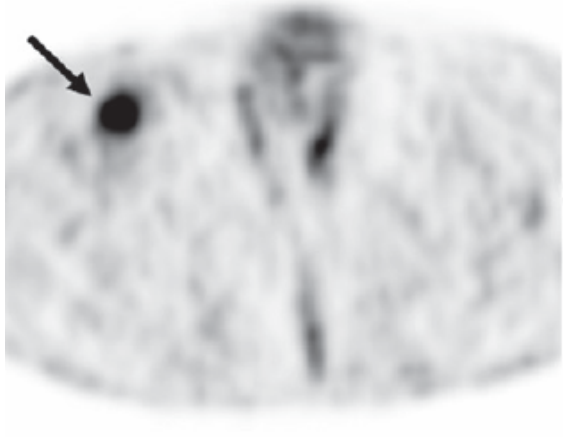

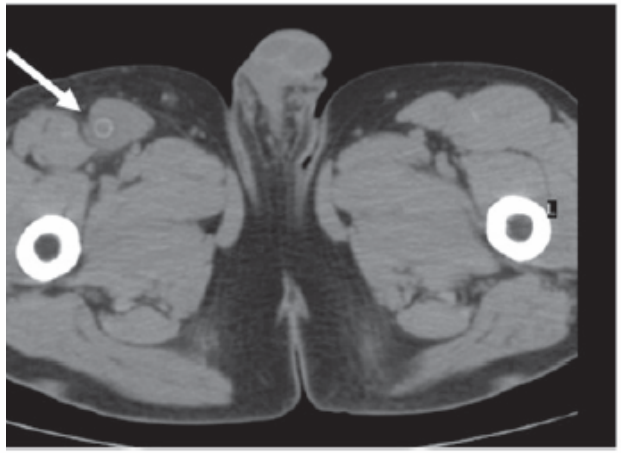

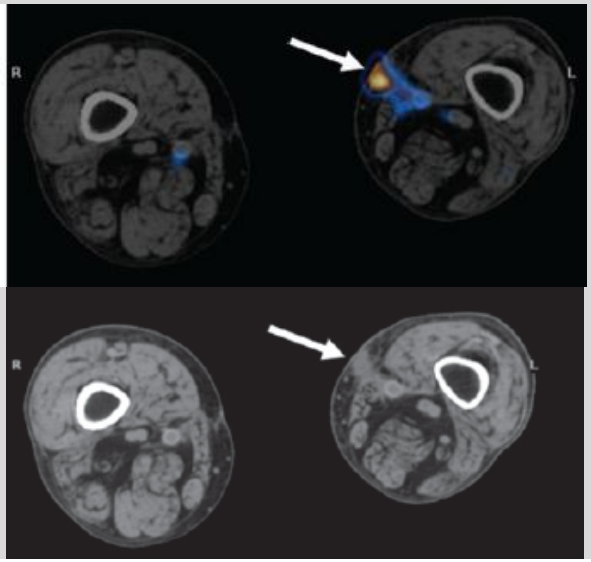

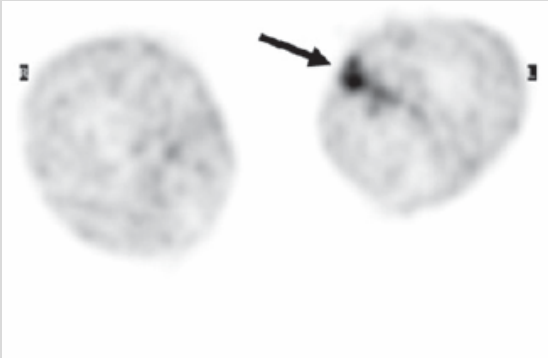

Herida infectada

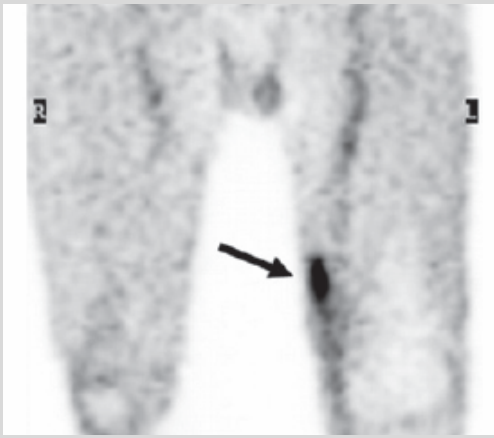

Varón de 47 años. Disección de aorta torácica. Recambio de válvula aórtica (prótesis metálica) e implantación de dos tubos de Dacron aórticos.

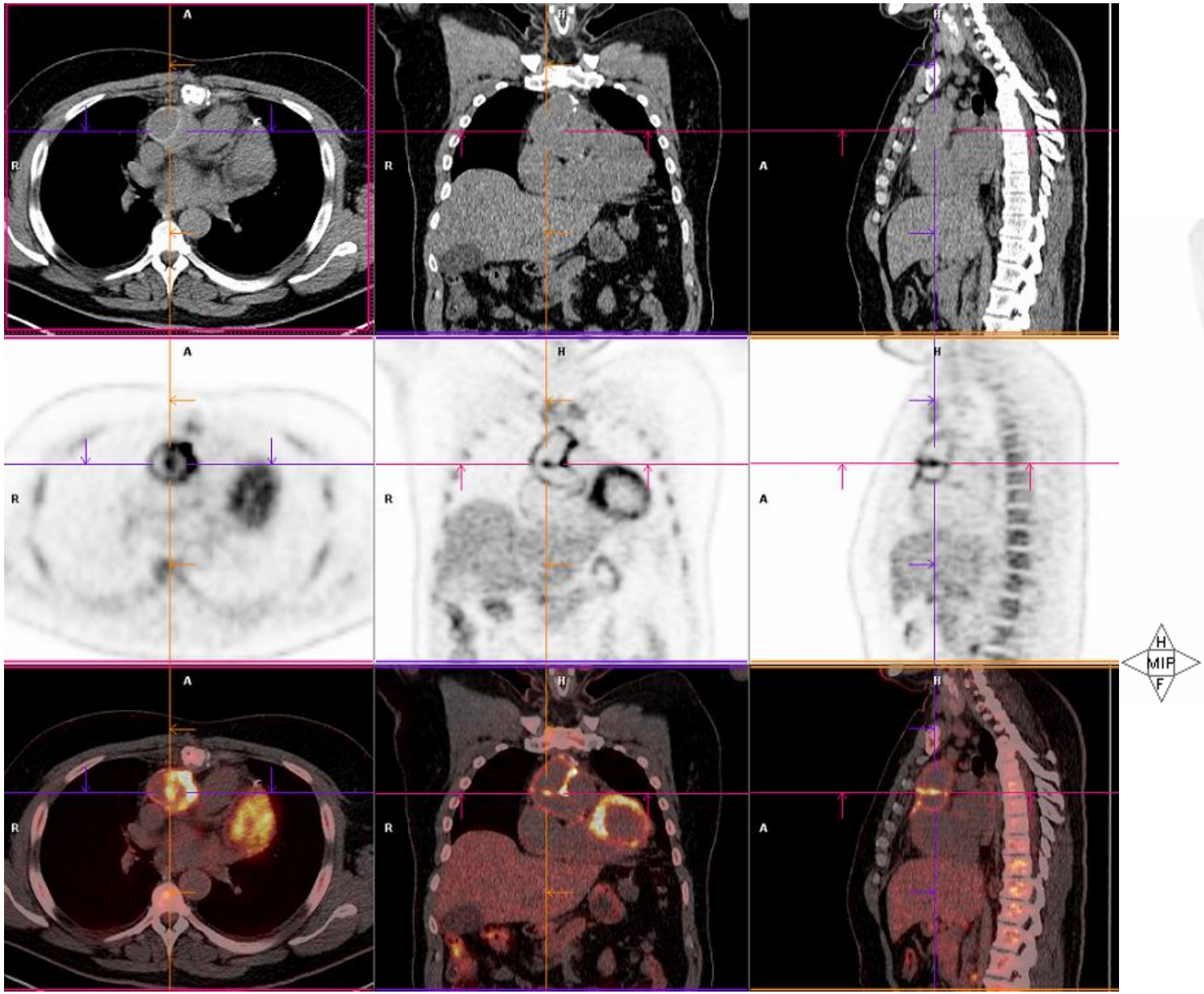

Varón de 47 años. Disección de aorta torácica. Recambio de válvula aórtica (prótesis metálica) e implantación de dos tubos de Dacron aórticos.

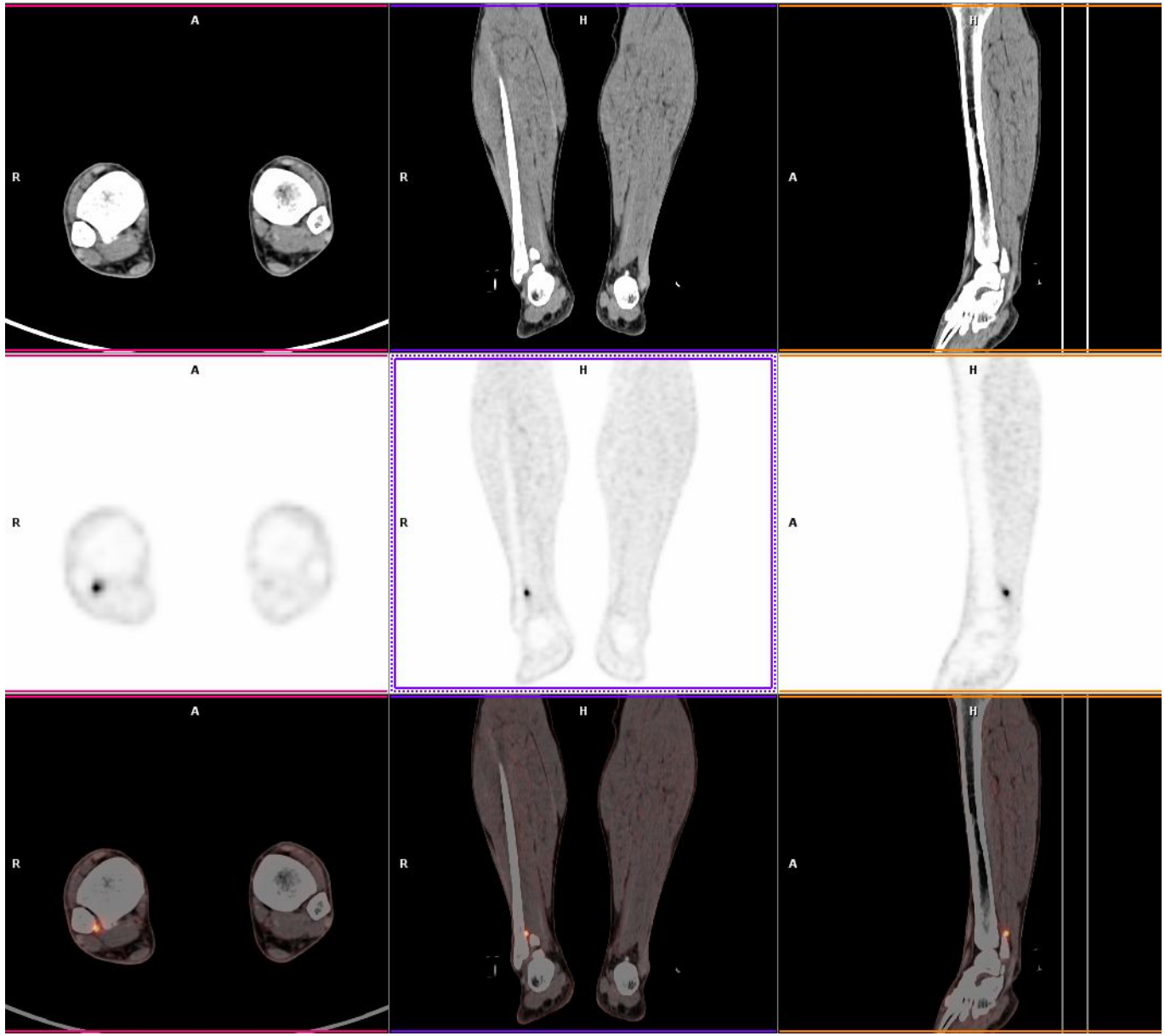

Wassélius J. J Nucl Med 2008

High ^{18}F-FDG Uptake in Synthetic Aortic Vascular Grafts on PET/CT in Symptomatic and Asymptomatic Patients

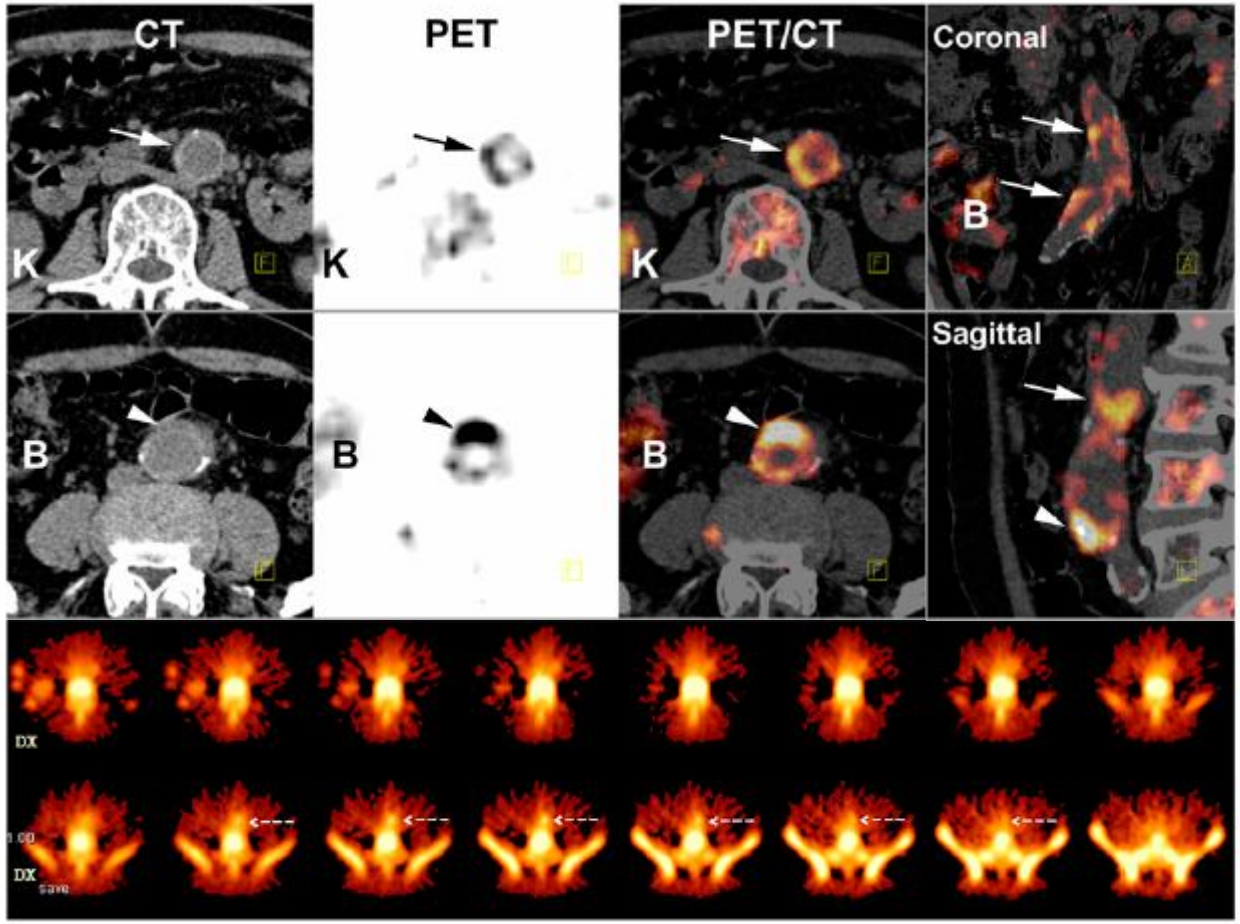

U. Karolinska

Wassélius J. J Nucl Med 2008

High ^{18}F-FDG Uptake in Synthetic Aortic Vascular Grafts on PET/CT in Symptomatic and Asymptomatic Patients

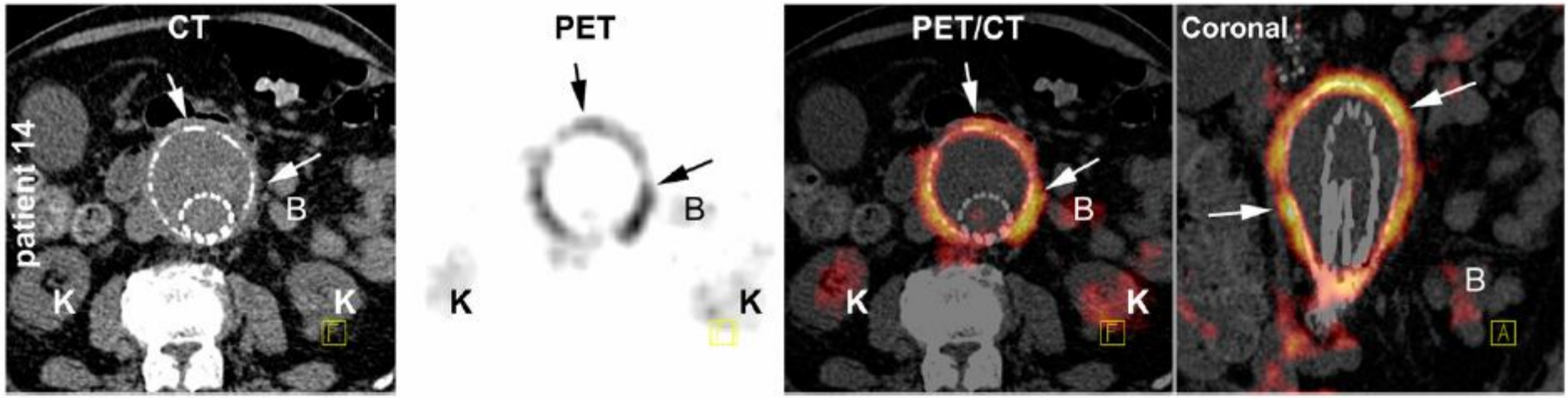

FDG uptake in 15/16 vascular grafts without graft infection.

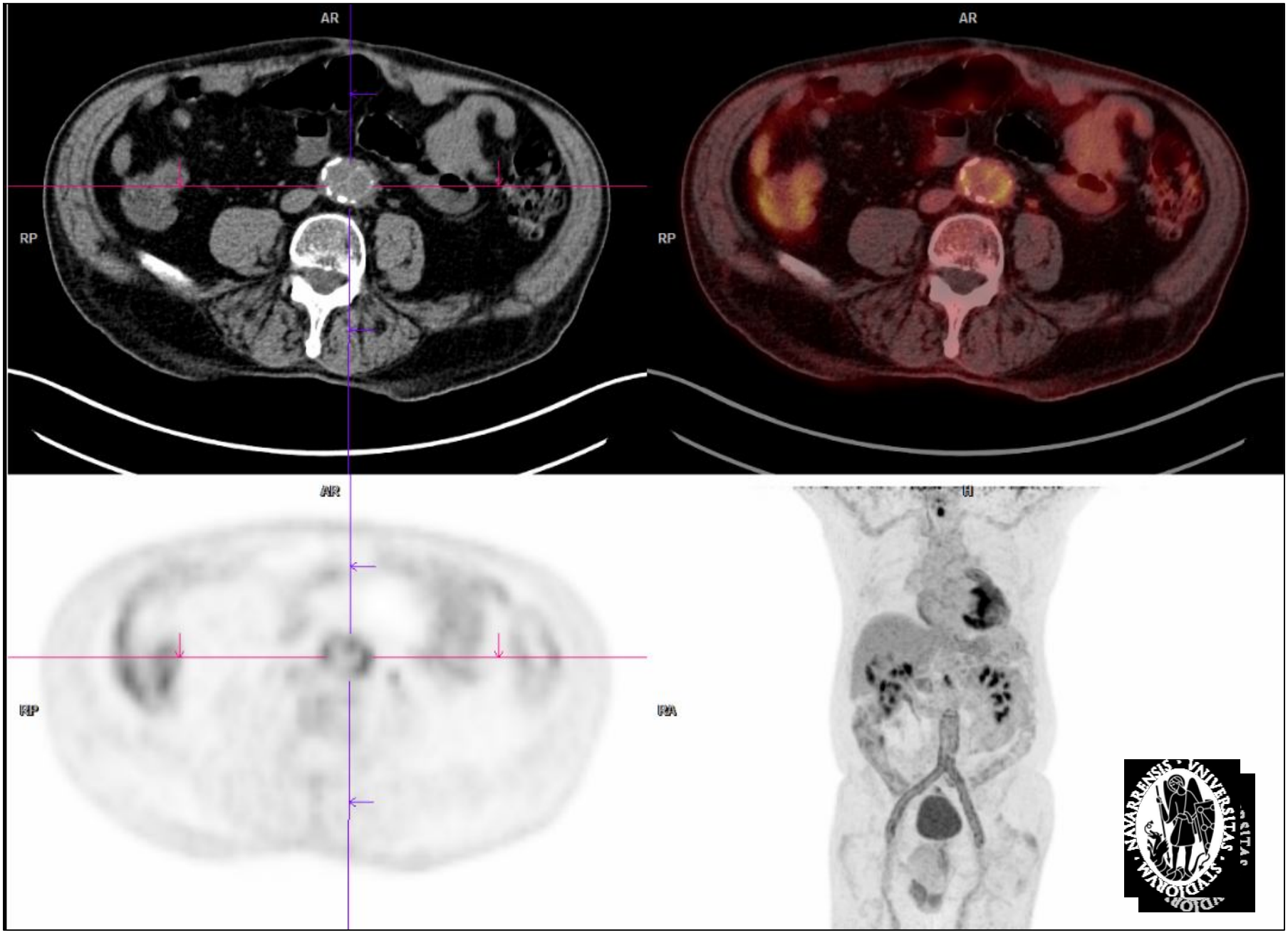
AR
RP
AR
RP
AR
RP
RA
H

Spacek M. Eur J Nucl Med Mol Imaging 2009

Diagnostics of "non-acute" vascular prosthesis infection using ^{18}F-FDG PET/CT: our experience with 96 prostheses

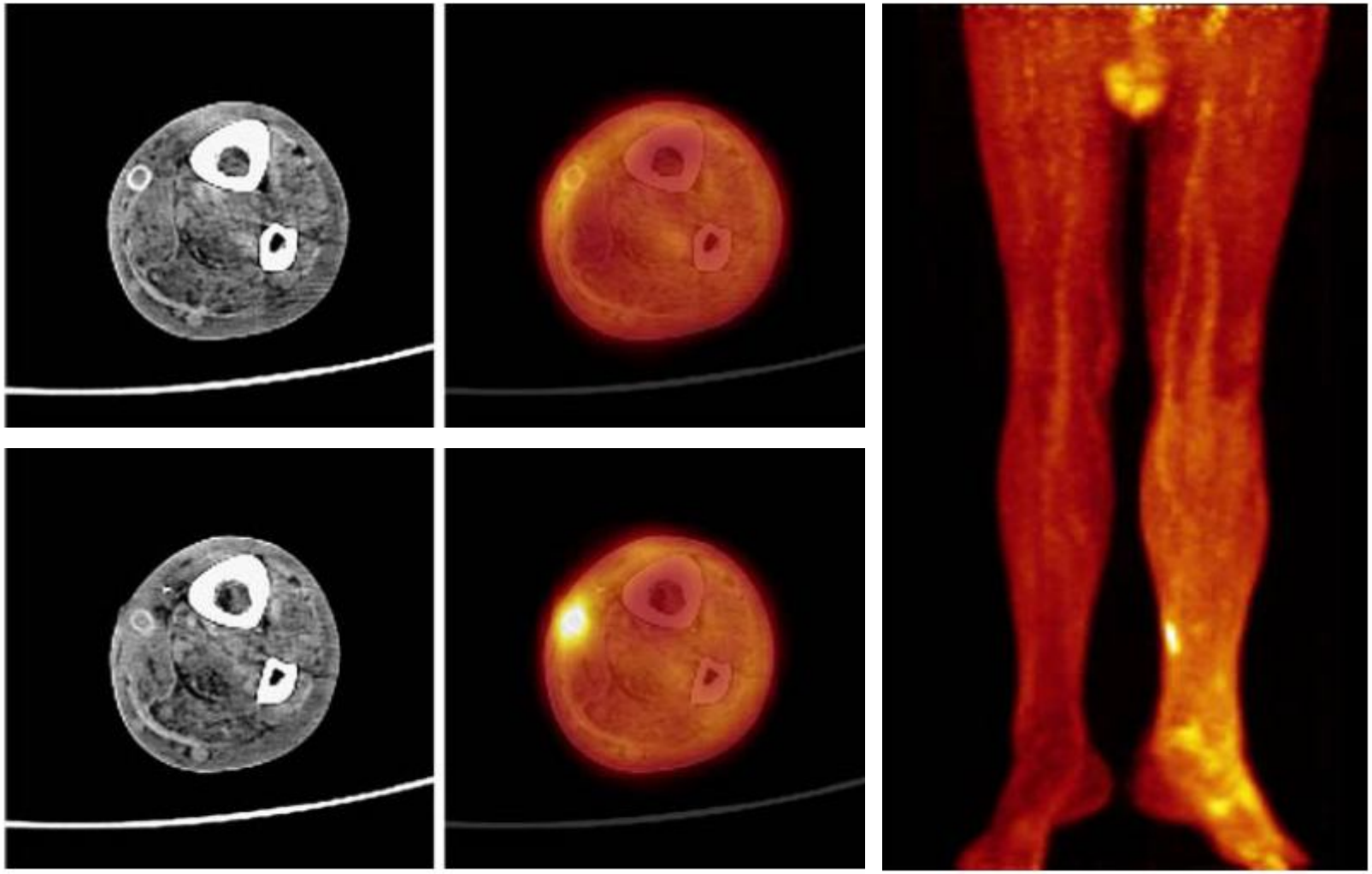

Bonfiglioli R. Eur J Nucl Med Mol Imaging 2013

^{18}F-FDG PET/CT diagnosis of unexpected extracardiac septic embolisms in patients with suspected cardiac endocarditis

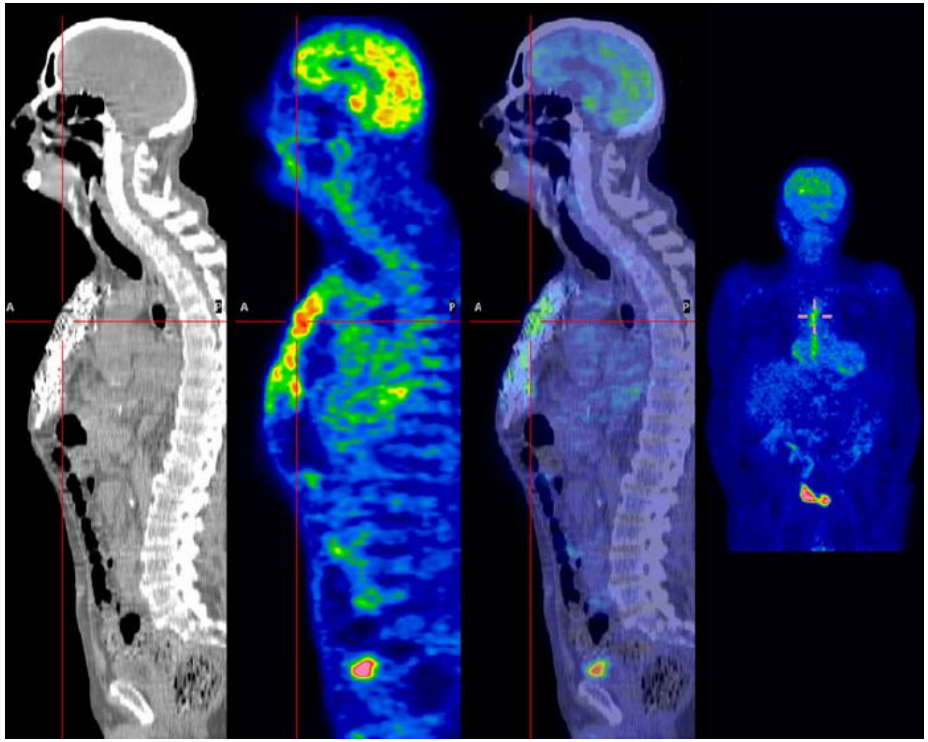

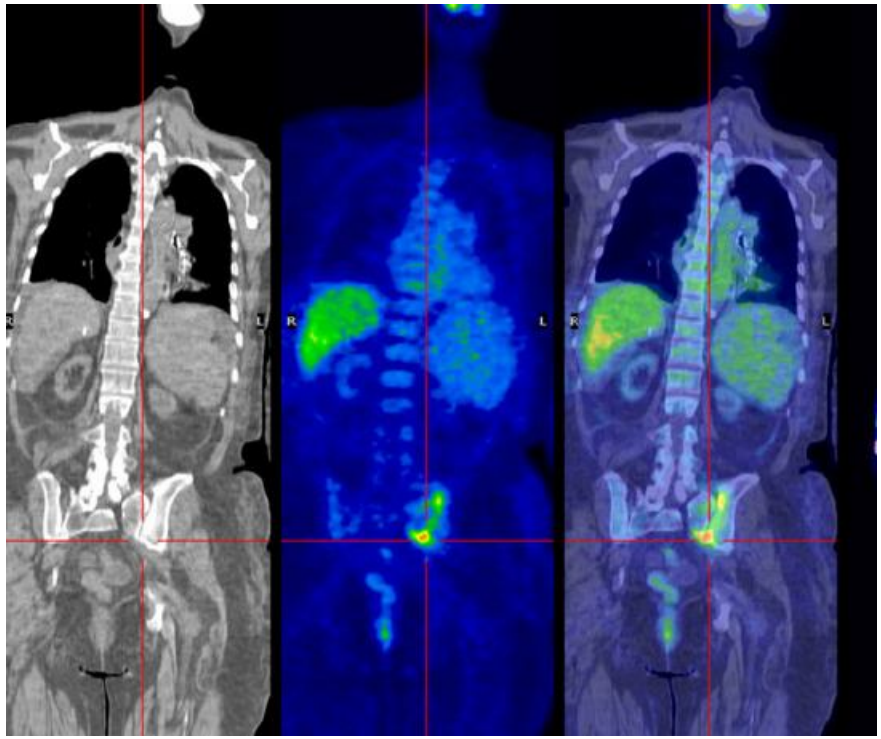

U. Bolonia

Bonfiglioli R. Eur J Nucl Med Mol Imaging 2013

^{18}F-FDG PET/CT diagnosis of unexpected extracardiac septic embolisms in patients with suspected cardiac endocarditis

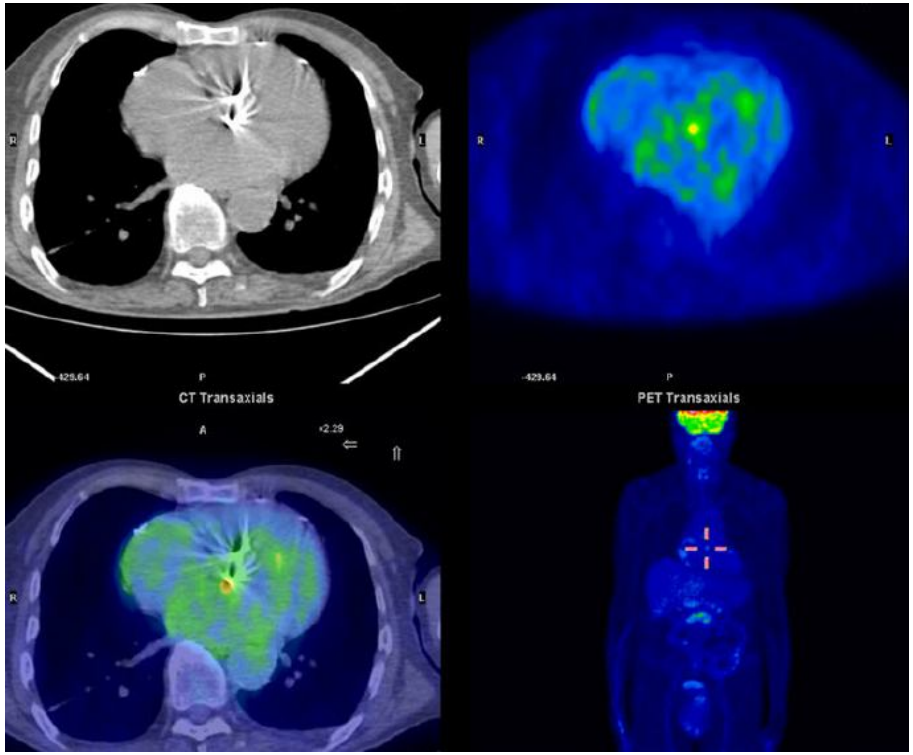

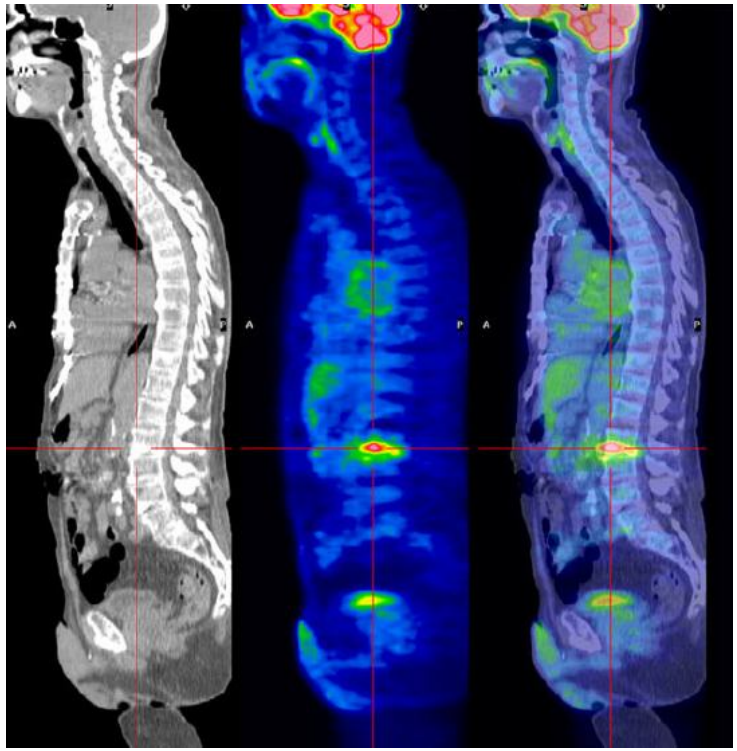

Bruggink JLM. Eur J Vasc Endovasc Surg 2010

Accuracy of FDG-PET–CT in the Diagnostic Work-up of Vascular Prosthetic Graft Infection

CT **FDG PET** **FDG PET/CT**

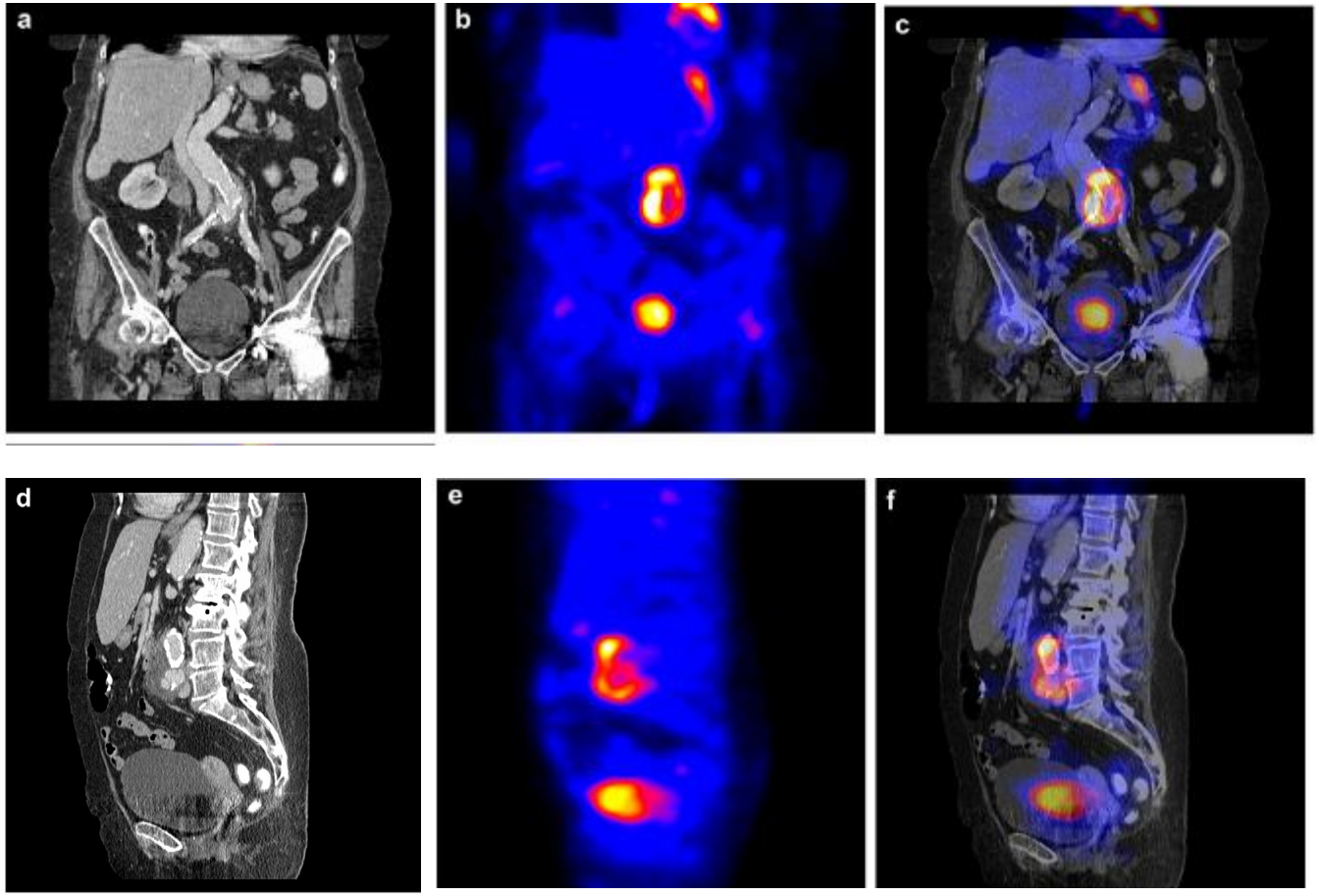

U. Groningen

Van Riet J. Eur J Nucl Med Mol Imaging 2010

^{18}F-FDG PET/CT for early detection of embolism and metastatic infection in patients with infective endocarditis

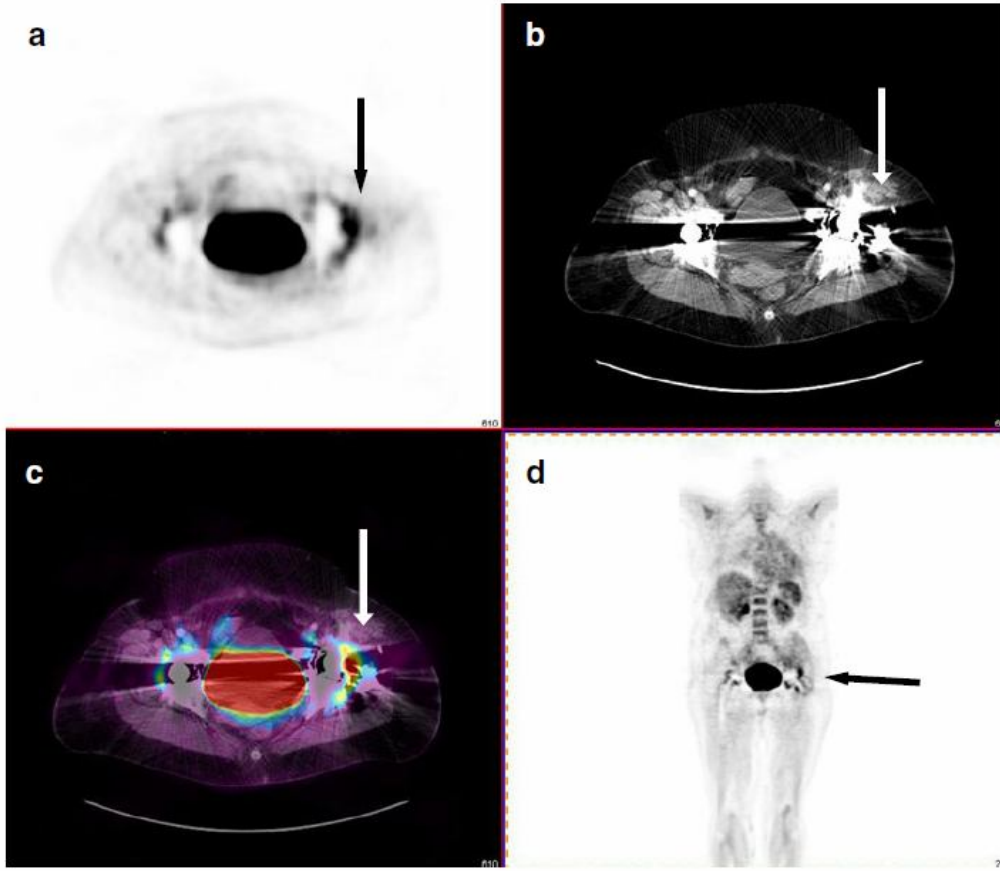

U. Lovaina

Van Riet J. Eur J Nucl Med Mol Imaging 2010

^{18}F-FDG PET/CT for early detection of embolism and metastatic infection in patients with infective endocarditis

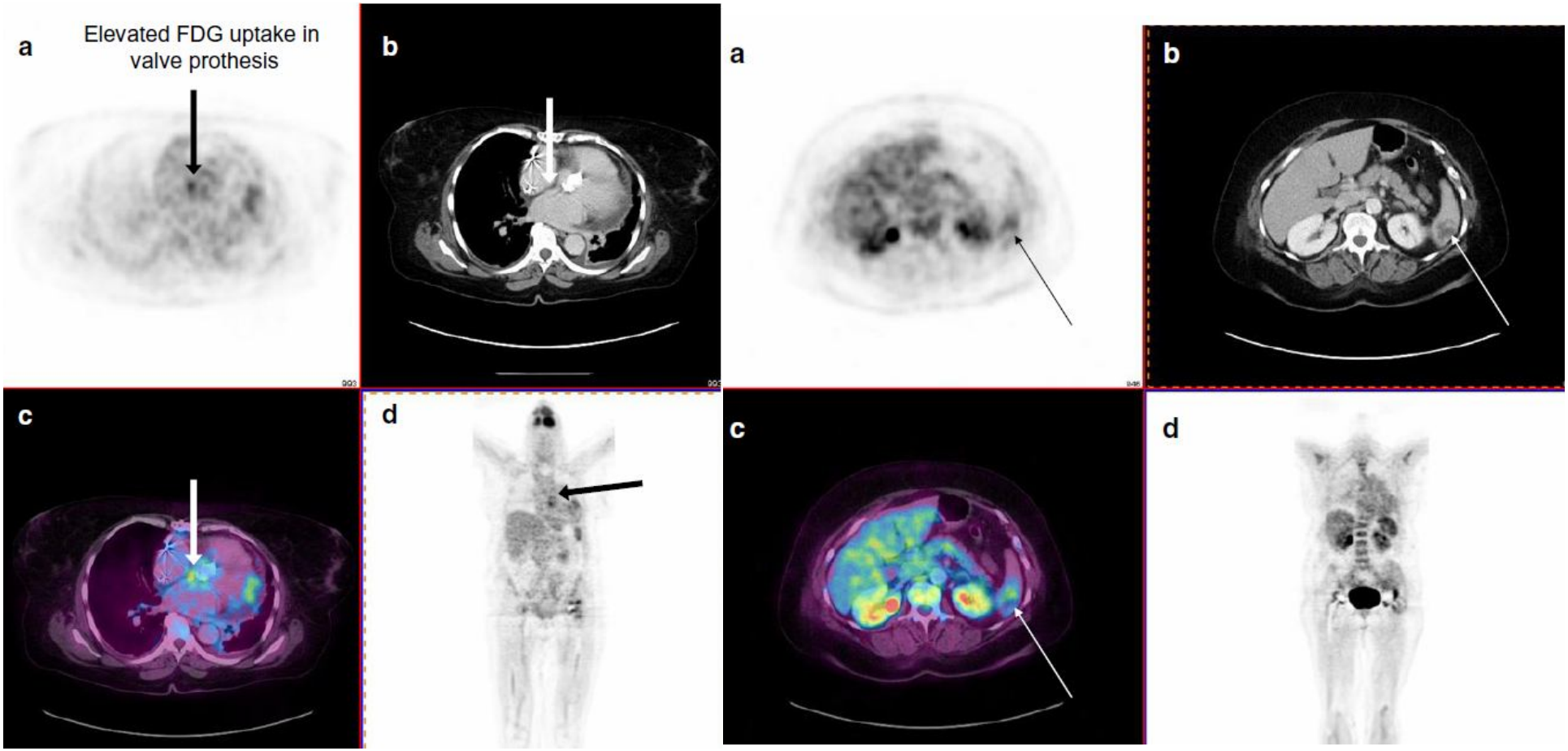

Gheysens O. Eur J Nucl Med Mol Imaging 2012

Septic pulmonary embolisms and metastatic infections from methicillin-resistant *Staphylococcus aureus* endocarditis on FDG PET/CT

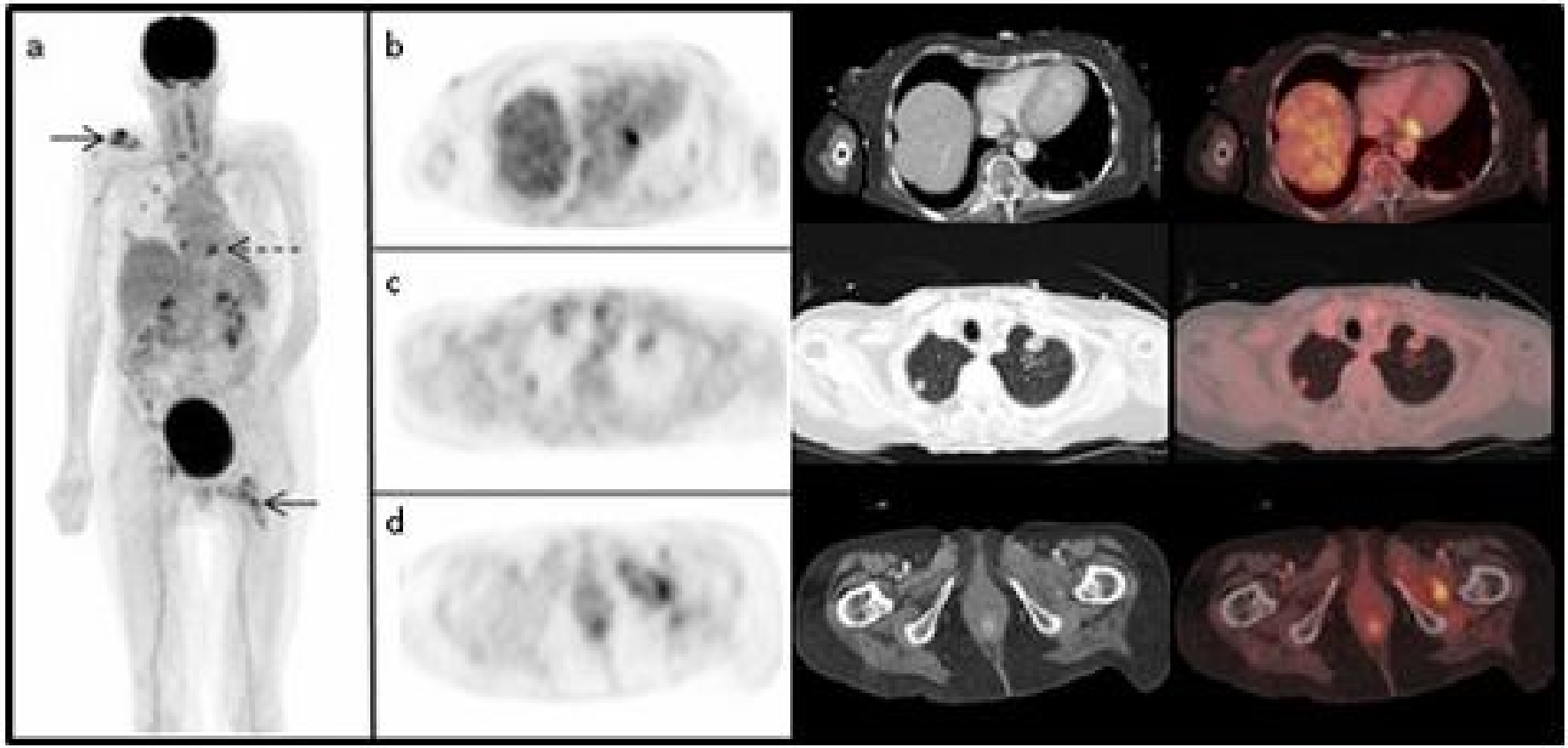

U. Lovaina

Kouijzer IJ. Eur J Nucl Med Mol Imaging 2013

ORIGINAL ARTICLE

The value of ^{18}F-FDG PET/CT in diagnosing infectious endocarditis

Preparación convencional:
S: 39%
E=93%

Varón 65 a.
Fiebre
Bacteriemia Estreptococo B
FDG PET/CT: v. aórtica

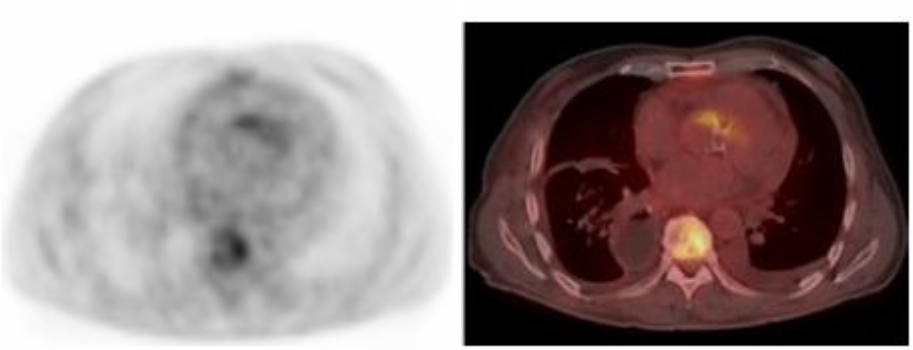

Varón 71 a.
Fiebre
Bacteriemia S. aureus
FDG PET/CT: v. mitral

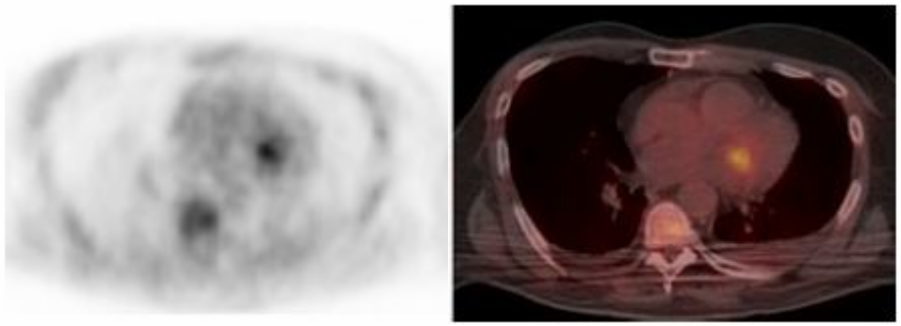

U. Rabdoud

FDG PET/CT - VARIABILIDAD EN LA CAPTACIÓN CARDÍACA

Preparación convencional

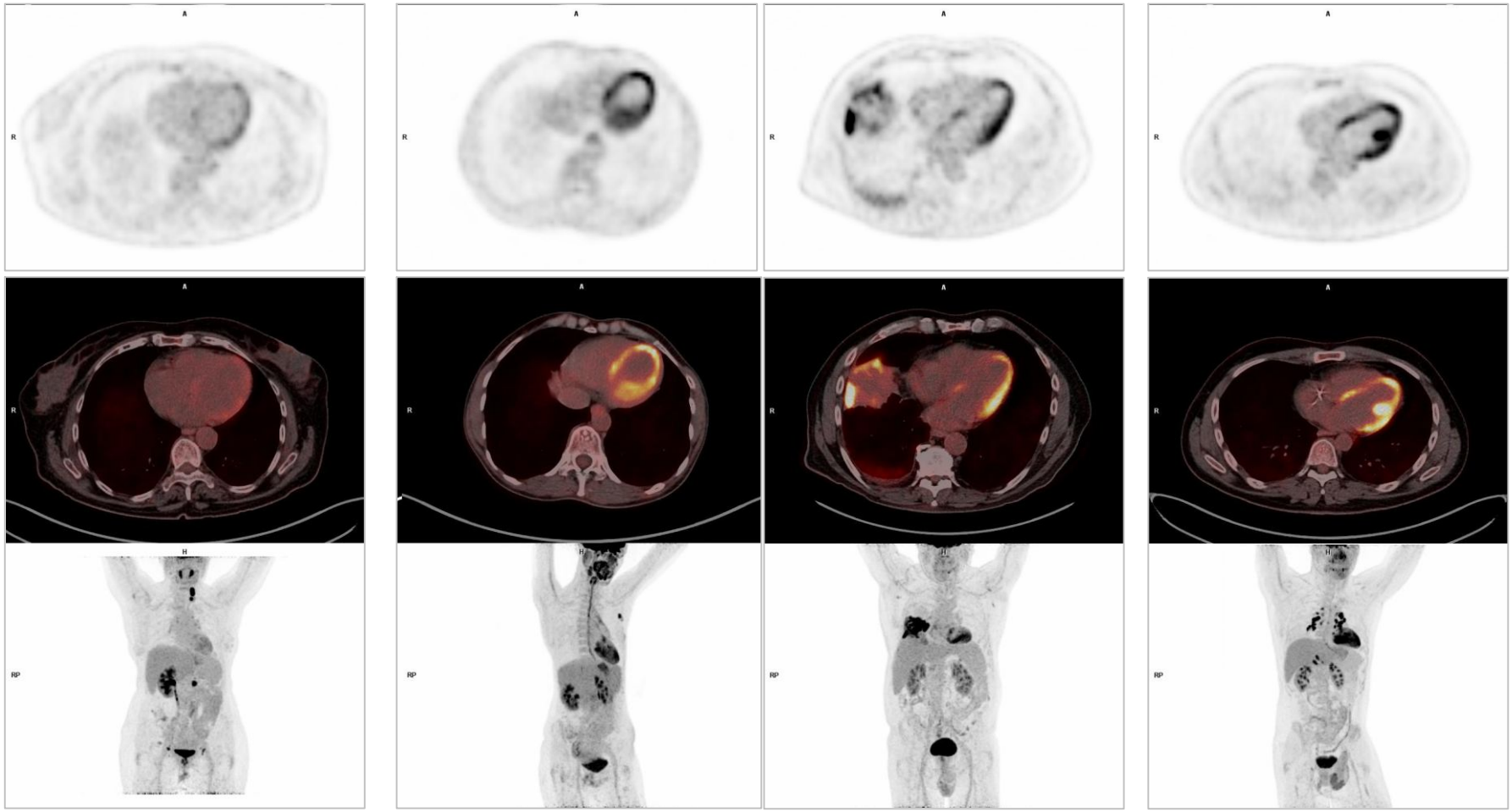

Bertagna F. Int J Cardiovasc Imaging 2012

Possible role of F18-FDG-PET/CT in the diagnosis of endocarditis: preliminary evidence from a review of the literature

Paciente mujer, 50 años, prótesis mitral. Endocarditis.

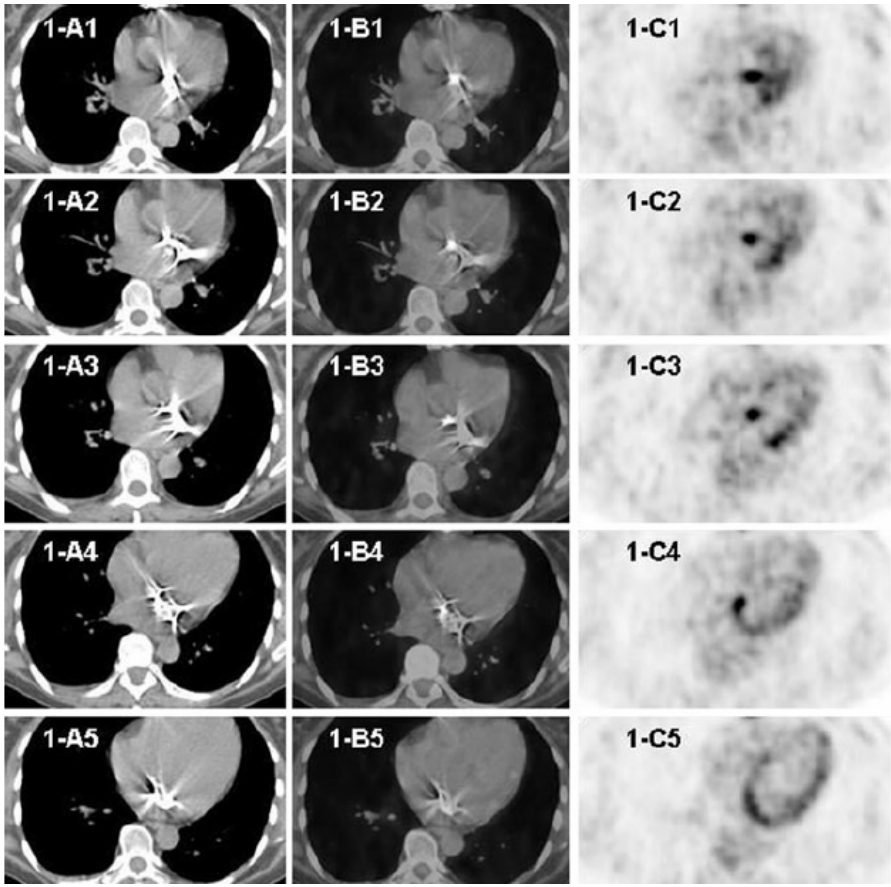

PREPARACIÓN:
- Día previo: dieta rica en grasa y baja en carbohidratos.
- 1 hora antes: bebida rica en grasa y baja en carbohidratos.

CONSENSO:

1)Valoración clínica + LAB + EC

2)FDG PET/CT en casos concretos

3)Total body: metástasis a distancia

4)SUV para valorar respuesta a tto.

U. Brescia

Treglia G. Eur J Nucl Med Mol Imaging 2012

LETTER TO THE EDITOR

Factors influencing the sensitivity of ^{18}F-FDG PET/CT in the detection of infective endocarditis

Giorgio Treglia · Francesco Bertagna

Avances técnicos: TOF – PSF

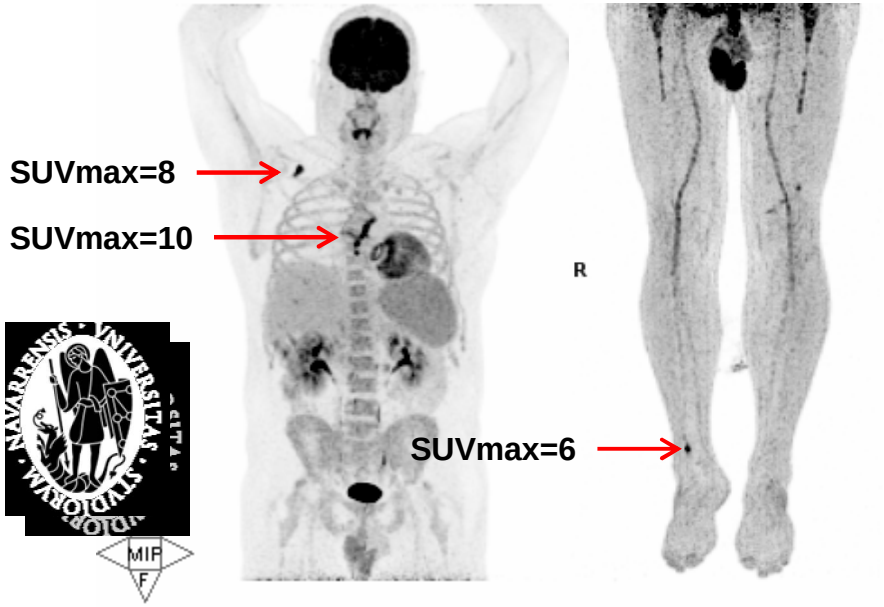

Tiempo de incorporación de FDG:
1 hora *vs* 2-3 horas (tardías)

PREPARACIÓN:
- Día previo: dieta rica en grasa y baja en carbohidratos.
- 1 hora antes: bebida rica en grasa y baja en carbohidratos.

CONSENSO:

1)Valoración clínica + LAB + EC

2)FDG PET/CT en casos concretos

3)Total body: metástasis a distancia

4)SUV para valorar respuesta a tto.

Millar BC. International J Cardiol. 2013

^{18}FDG-positron emission tomography (PET) has a role to play in the diagnosis and therapy of infective endocarditis and cardiac device infection

B. Cherie Millar [a], Bernard D. Prendergast [b], Abass Alavi [c], John E. Moore [a,*]



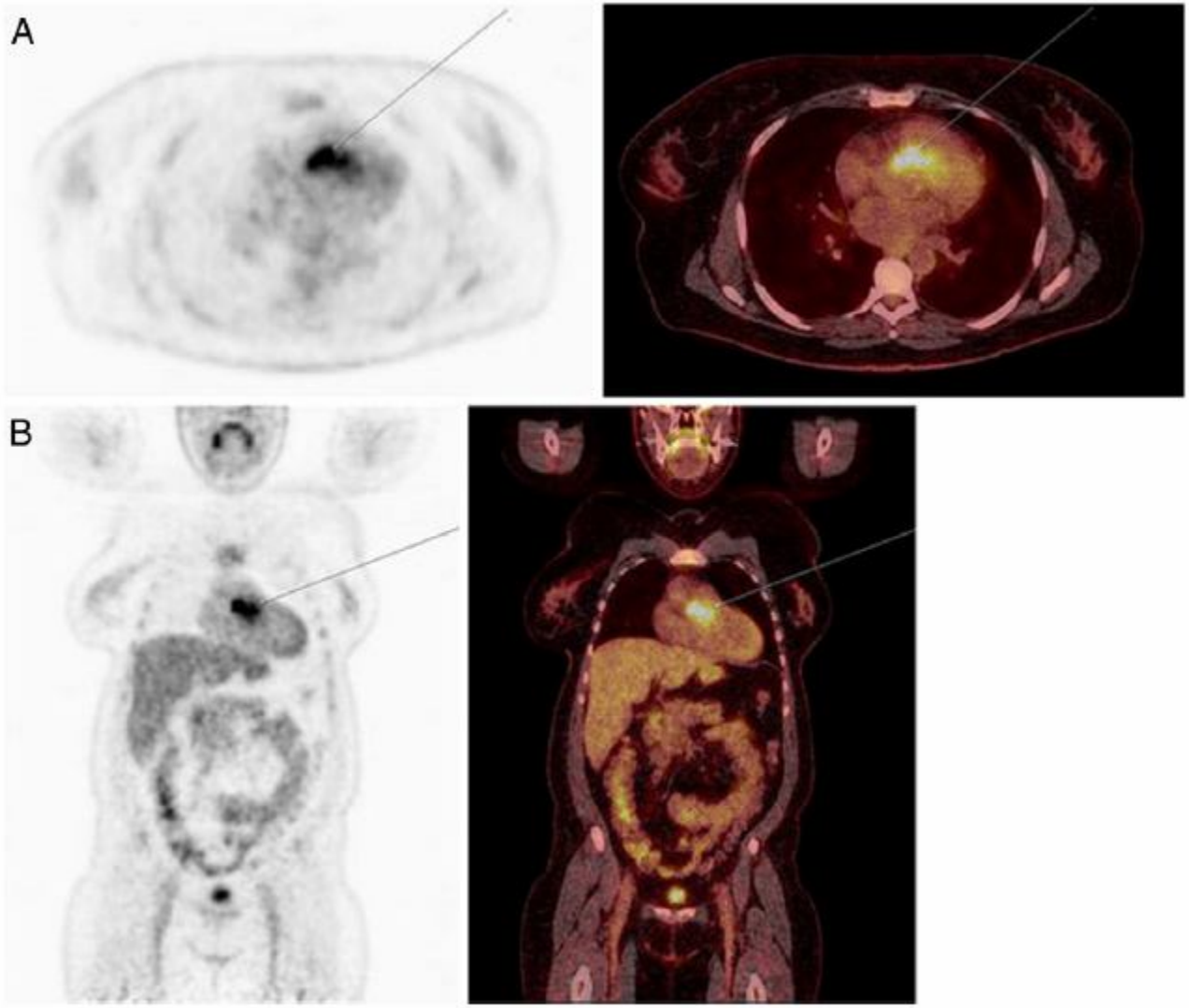

U. Pensilvania

Millar BC. International J Cardiol. 2013

^{18}FDG-positron emission tomography (PET) has a role to play in the diagnosis and therapy of infective endocarditis and cardiac device infection

B. Cherie Millar [a], Bernard D. Prendergast [b], Abass Alavi [c], John E. Moore [a,*]



Table 2
A summary of papers selected for review which used positron emission tomography (PET) to investigate infective endocarditis and cardiac device related infection.

Focus of paper	No. of papers	Type of paper
Valvular IE and related cardiac infection	12	Case report
	1	Preliminary Investigation
	4	Case within a paper focusing on the use of PET imaging in infectious diseases
Cardiac device infection	7	Case report
	1	Case within an original study focusing on septic shock of unknown origin
	3	Original study
Complications associated with IE (emboli & metastatic Infection)	1	Original study
	1	Case report
Basic Science (an animal model to study IE)	1	Original study
Total	31	

Diagnostic Category	Definition
Primary	PET imaging result positive for cardiac infection, in the absence of echographical evidence of vegetations and/or clinical evidence. Infection confirmed by valve culture, surgical evidence or a second echocardiograph post a positive PET finding
Contributory	PET imaging result positive for cardiac infection, in the presence of positive blood culture or echographical evidence of vegetations or clinical evidence.
Confirmatory	PET imaging result positive for cardiac infection at the time the patient diagnosed by the Duke Criteria.
Retrospective	PET imaging result positive for cardiac infection, however this finding was retrospective of the patient being diagnosed by the Duke Criteria.
Incidental	PET imaging result positive for cardiac infection, however this finding was made coincidentally following investigation of another unrelated infectious site.
Missed	PET imaging findings did not reveal any evidence of cardiac infection however infection was confirmed by microbiological investigation either pre- or post surgery.

APLICABILIDAD FDG PET/CT:
- Endocarditis
- Infección de CIED
- Émbolos
- Metástasis sépticas
- Monitorización de respuesta

U. Pensilvania

Usefulness of Fluorine-18 Positron Emission Tomography/ Computed Tomography for Identification of Cardiovascular Implantable Electronic Device Infections

Sarrazin JF. JAAC 2013

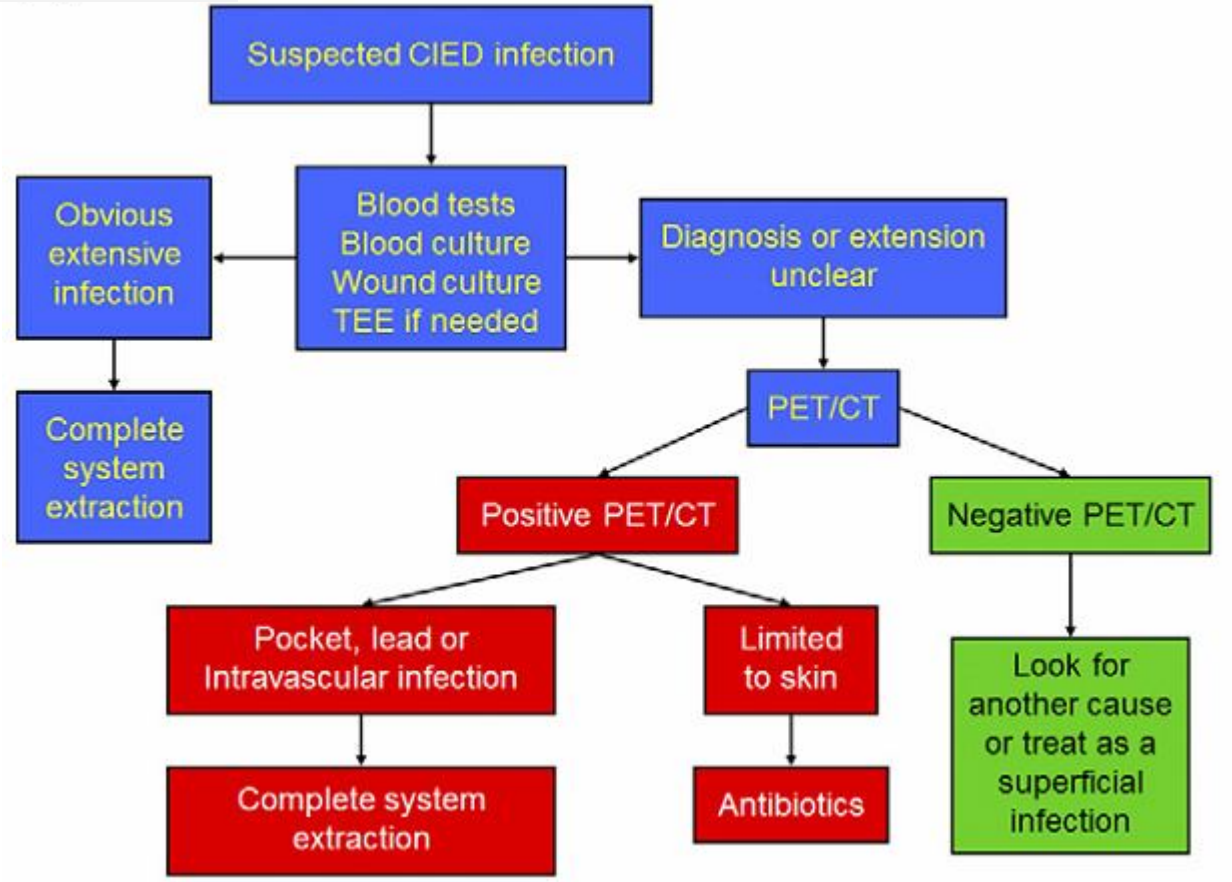

U. Quebec

Usefulness of Fluorine-18 Positron Emission Tomography/ Computed Tomography for Identification of Cardiovascular Implantable Electronic Device Infections

Sarrazin JF. JAAC 2013

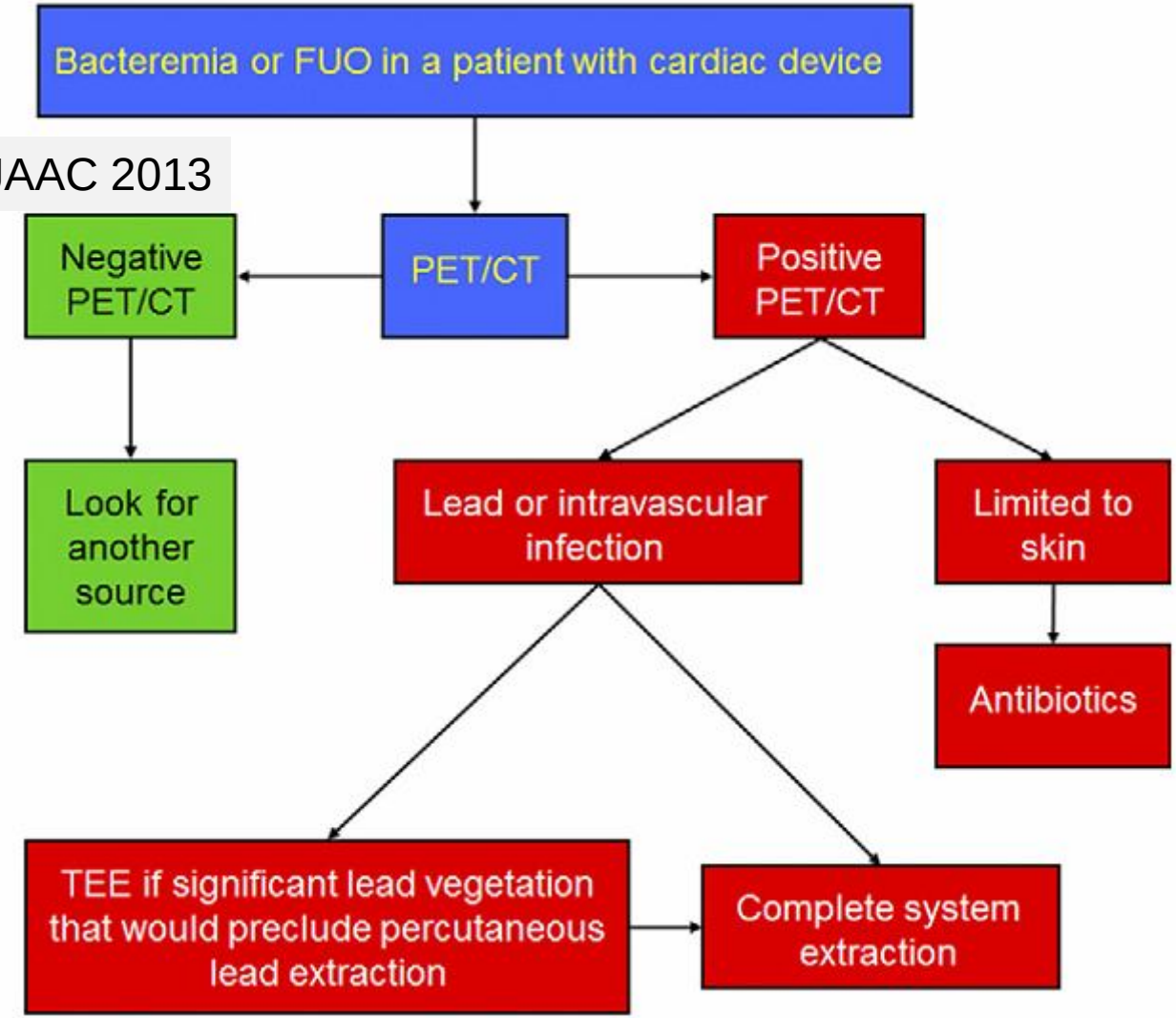

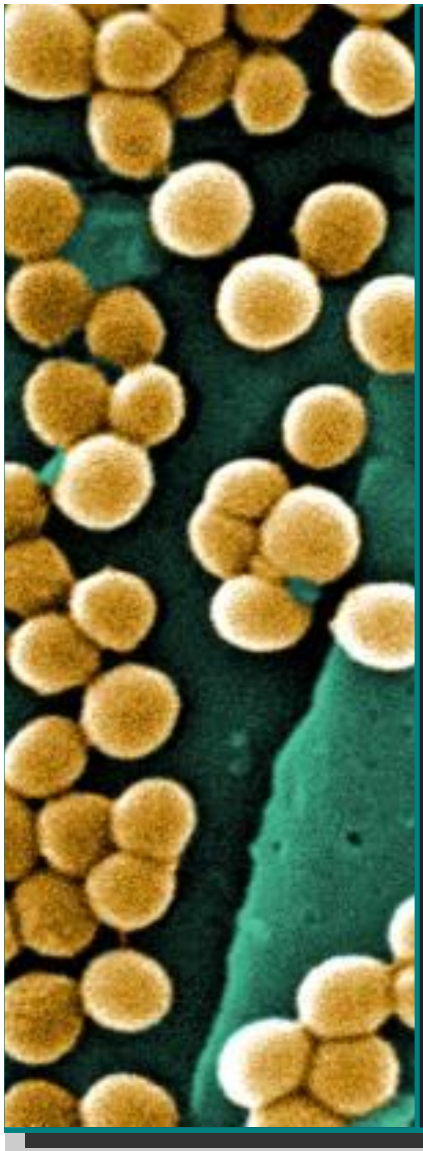

ASSESSMENT OF TREATMENTS AGAINST *STAPHYLOCOCCUS AUREUS* BIOFILMS USING *IN VIVO* ^{18}F-FDG-PET IN AN ANIMAL MODEL

Collantes M[1], Garrido V[2], Barberán M[3], Arbizu J[4], Amorena B[2], Abadía S[1], Grilló MJ[2], Peñuelasl[1,5]

1. Unidad de Investigación MicroPET, CIMA-CUN, Universidad de Navarra, Spain.
2. Grupo de Sanidad Animal, Instituto de Agrobiotecnología, CSIC-UPNA-Gobierno de Navarra, Spain.
3. Departamento de Patología Animal, Universidad de Zaragoza, Spain.
4. Servicio de Medicina Nuclear, Clínica Universidad de Navarra, Spain.
5. Unidad de Radiofarmacia, Clínica Universidad de Navarra, Spain.

EANM´13
Lyon, France

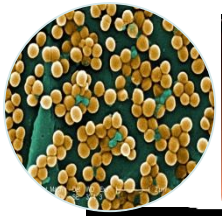

ANIMAL MODEL

Animals

- ✓ CD1 ♀ mice

Biofilm model

- ✓ Subcutaneous implantation of sealed catheters of Vialon™ biomaterial pre-colonized with *Staphylococcus aureus* ATCC15981

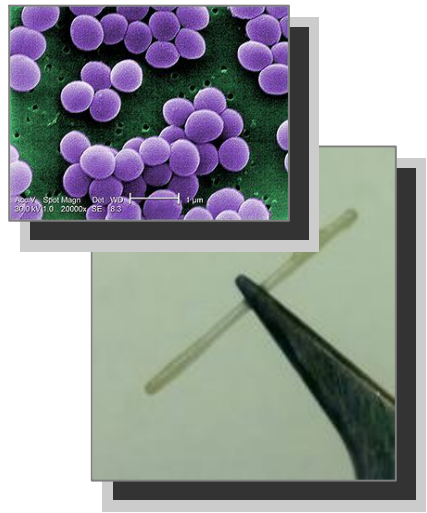

Mice groups

1. **Uninfected controls (negative)**: sterile catheter
2. **Untreated controls (positive)**: infected catheter
3. **Treated mice**: infected catheter + oral rifampicin (0.5 mg/day) for 7 days

FDG PET IMAGING PROCEDURE

PET imaging protocol

- ✓ **^{18}F-FDG**: iv administration dose 18,3 ± 1,6 MBq.
- ✓ **Static study**:
  - Mice fasted for 12h
  - 1h of uptake under inhalation anesthesia (isoflurane)
  - 15 min study
- ✓ **Mosaic** (Philips) small animal PET scanner.

Material and Methods

PET quantitative image analysis

Catheter

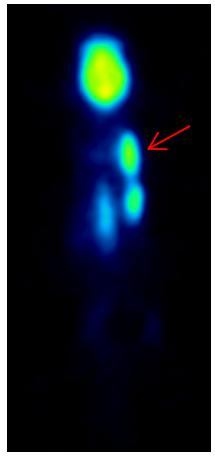

SUV60 index:
SUV mean of the catheter contour semiautomatically delineated by using a threshold of 60% of the maximal SUV within the lesion.

Axillary lymph node



SUVmax index:
SUV mean value of the axillary iplisateral lymph node

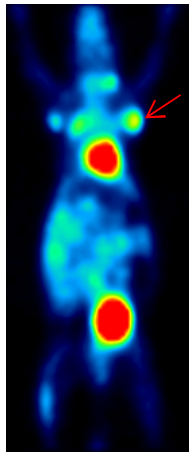

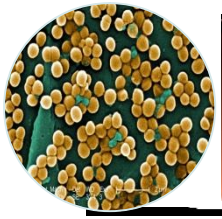

PET monitorization of *S. aureus* infection

Catheter area

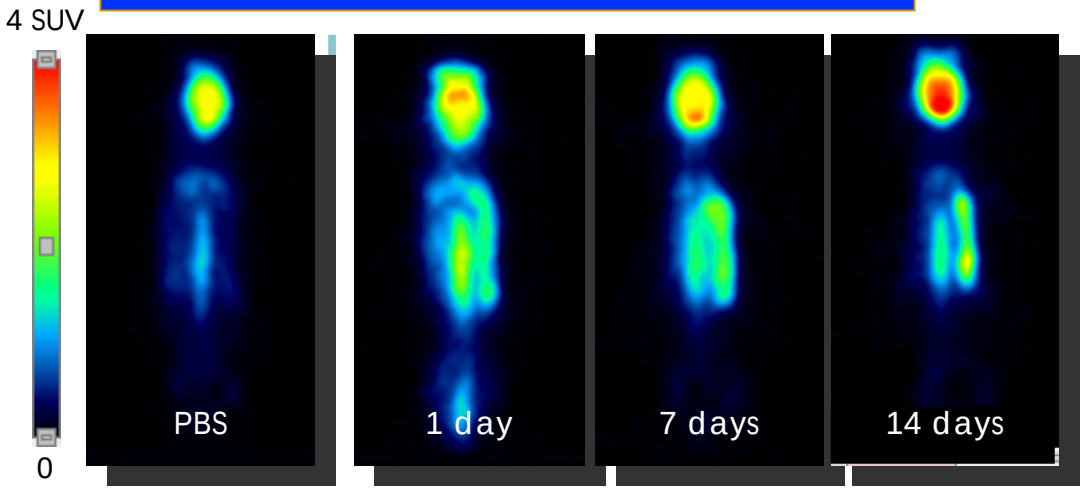

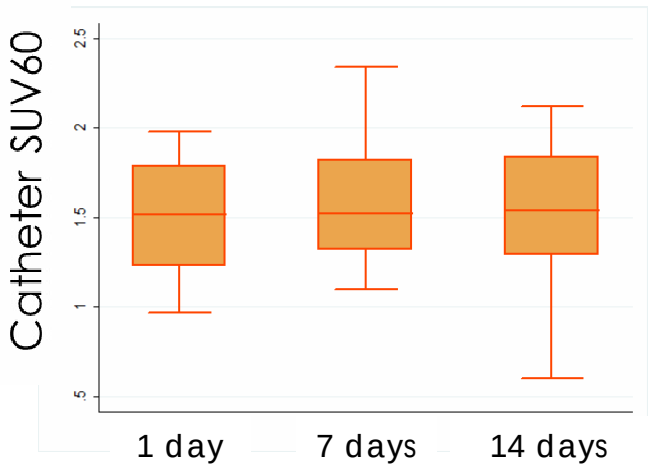

Axilar lymph nodes

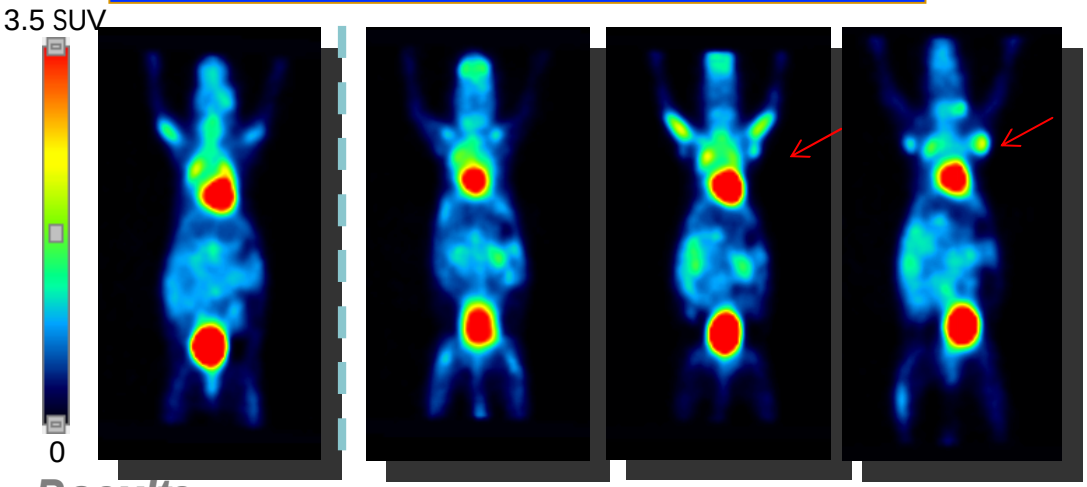

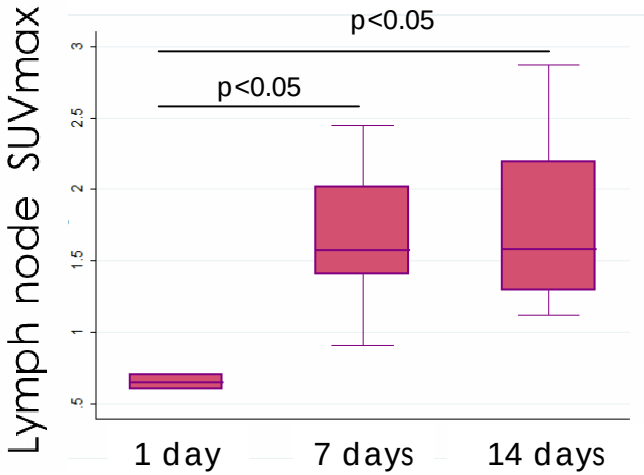

Results

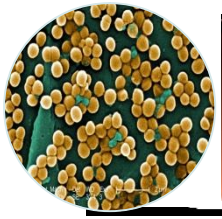

Response to antibiotic treatment

Catheter area

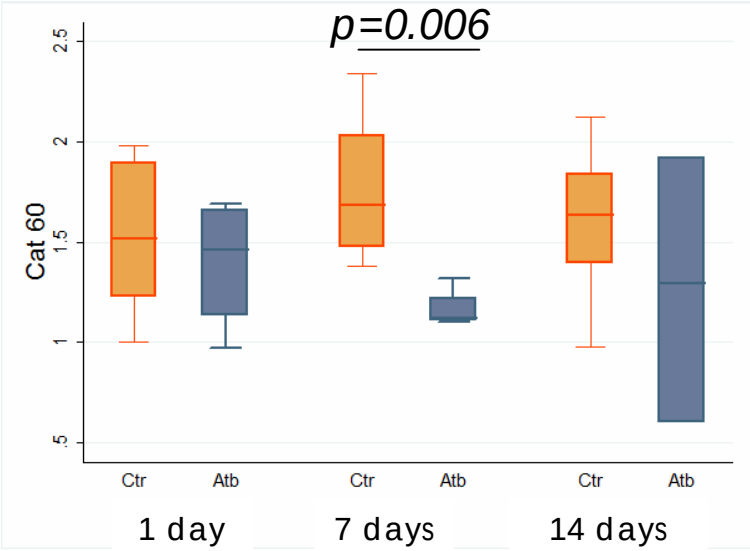

Axilar lymph nodes

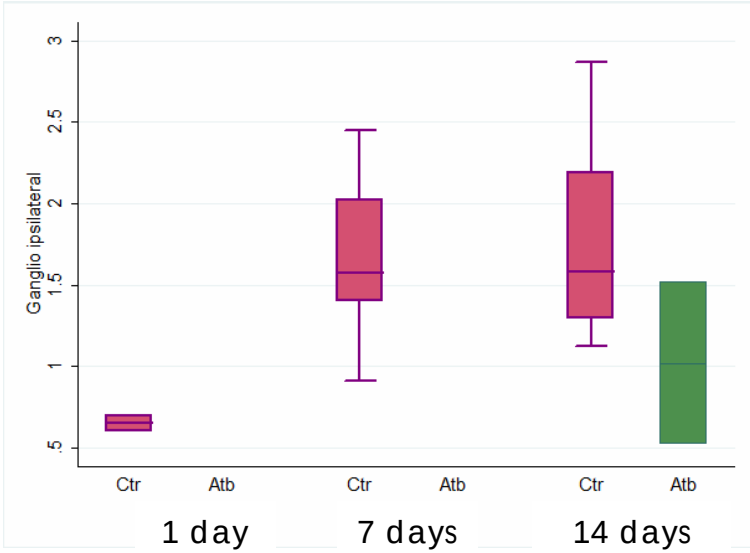

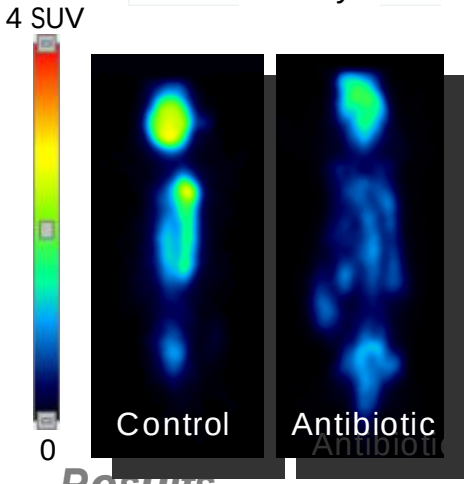

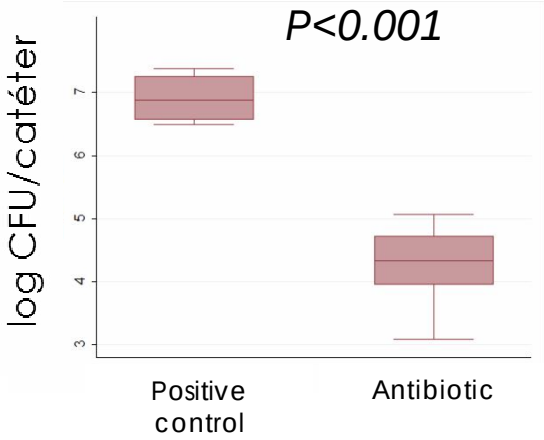

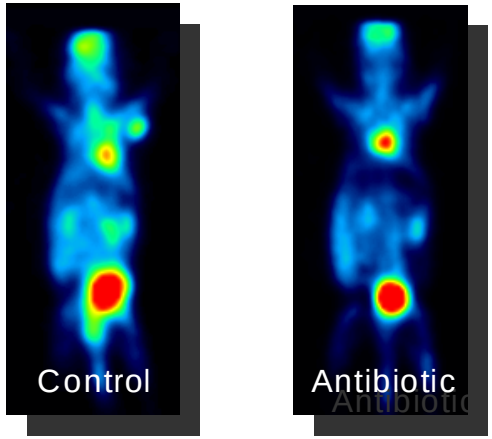

Results

MESA 4 | **REPERCUSIONES SISTÉMICAS DE LAS INFECCIONES CARDIOVASCULARES**

Moderadores:

Antonio Ramos
Hospital Universitario Puerta de Hierro, Madrid

Josune Goikoetxea
Hospital Universitario Cruces, Bilbao

17.50 a 18.10 h | **El riñón y la endocarditis infecciosa**
Eduardo Verde
Hospital Universitario Gregorio Marañón, Madrid

18.10 a 18.30 h | **El sistema nervioso central y la endocarditis infecciosa**
César Aristides de Alarcón
Hospital Universitario Virgen del Rocío, Sevilla

18.30 a 18.50 h | **PET, infección cardiovascular y metástasis a distancia**

FDG PET/CT

Mª José García Velloso
Servicio de Medicina Nuclear
Clínica Universidad de Navarra