Nuevas técnicas de imagen en Endocarditis Infecciosa.

SPECT/TC y PET/TC

Dr. Santiago Aguadé Bruix

Medicina Nuclear.
Hospital Universitari Vall d'Hebron. Barcelona.

saguade@vhebron.net

Nuevas técnicas de imagen en Endocarditis Infecciosa. SPECT/TC y PET/TC

ANTECEDENTES:

Technetium-99m Stannous Pyrophosphate Imaging of Experimental Infective Endocarditis

ARTHUR L. RIBA, M.D., JAMES DOWNS, M.S., MATHEW L. THAKUR, PH.D., ALEXANDER GOTTSCHALK, M.D., VINCENT T. ANDRIOLE, M.D., AND BARRY L. ZARET, M.D.

Circulation. 1978;58:111-119

Finally, the infective endocarditis lesion is composed of platelets, white blood cells, bacteria, fibrinogen and antibacterial substances. Labeling these components with radioactive tracers may also be interesting and valuable in imaging infective endocarditis.

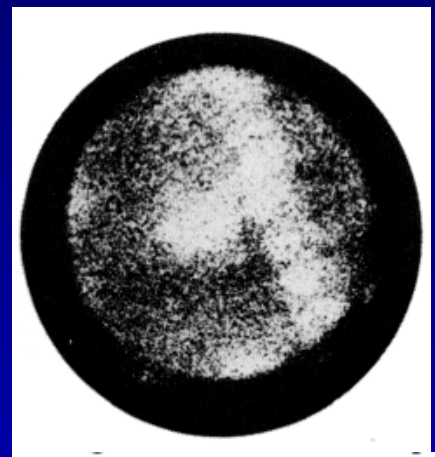

a rabbit with infective endocarditis

Imaging Experimental Infective Endocarditis with Indium-111-labeled Blood Cellular Components

ARTHUR L. RIBA, M.D., MATHEW L. THAKUR, PH.D., ALEXANDER GOTTSCHALK, M.D., VINCENT T. ANDRIOLE, M.D., AND BARRY L. ZARET, M.D.

Circulation. 1979;59:336-343

Our findings indicate that experimental infective endocarditis can be detected by radionuclide ^{111}In-platelet imaging. However, the lesions produced were relatively large and represented acute fulminant endocarditis.



a 72-hour ^{111}In platelet cardiac image from an animal

ANTECEDENTES:

Indium 111 WBC Scan in Local and Systemic Fungal Infections

Michael K. Haseman, MD; Kathleen Blake, MD; I. Ross McDougall, MB, ChB

Arch Intern Med. 1984;144(7):1462-1463.

XII Congreso Nacional de Medicina Nuclear. Palma de Mallorca. Mayo de 1986.

Ponència: "Marcaje de plaquetas y aplicaciones clínicas". M. Roca, S. Aguadé, B. Soriano y J. Martín.

Comunicación: "Plaquetas marcadas con ^{111}Indio-oxina en la detección de vegetaciones en la endocarditis infecciosa". S. Aguadé, B. Soriano, D. Ortega, A. Alvarez y M.P. Tornos.

Nuevas técnicas de imagen en Endocarditis Infecciosa. SPECT/TC y PET/TC

ANTECEDENTES:

The contribution of nuclear medicine to the patient with infection

W. Becker

Eur J Nucl Med (1995) 22:1195–1211

All radiopharmaceuticals available to date, such as technetium-99m nanocolloids, gallium-67 citrate, indium-111- and ^{99m}Tc-labelled white blood cells, ^{99m}Tc-antigranulocyte antibodies, and ^{99m}Tc-or ^{111}In-labelled unspecific human immunoglobulin, have different biodistributions and different physical characteristics.

Fever of unknown origin: prospective comparison of diagnostic value of ^{18}F-FDG PET and ^{111}In-granulocyte scintigraphy

Andreas Kjaer, Anne-Mette Lebech, Annika Eigtved, Liselotte Højgaard

Eur J Nucl Med Mol Im (2004) 31:622-626

^{111}In-granulocyte scintigraphy has a superior diagnostic performance compared to FDG-PET for detection of a localised infectious/inflammatory or neoplastic cause of FUO. The poorer performance of FDG-PET is in particular attributable to a high percentage of false positive scans, leading to low specificity.

Nuevas técnicas de imagen en Endocarditis Infecciosa. SPECT/TC y PET/TC

SPECT/TC:

Aortic Root Infection in a Prosthetic Valve Demonstrated by Gallium-67 Citrate SPECT

L. E. J. Thomson, MB, ChB,§ M. P. Goodman, MD, T. Z. Naqvi, MD,† R. Feldman, MD,‡ N. A. Buchbinder, MD,† A. Waxman, MD,§ and A. D'Agnolo, MD§*

(*Clin Nucl Med* 2005;30: 265–268)

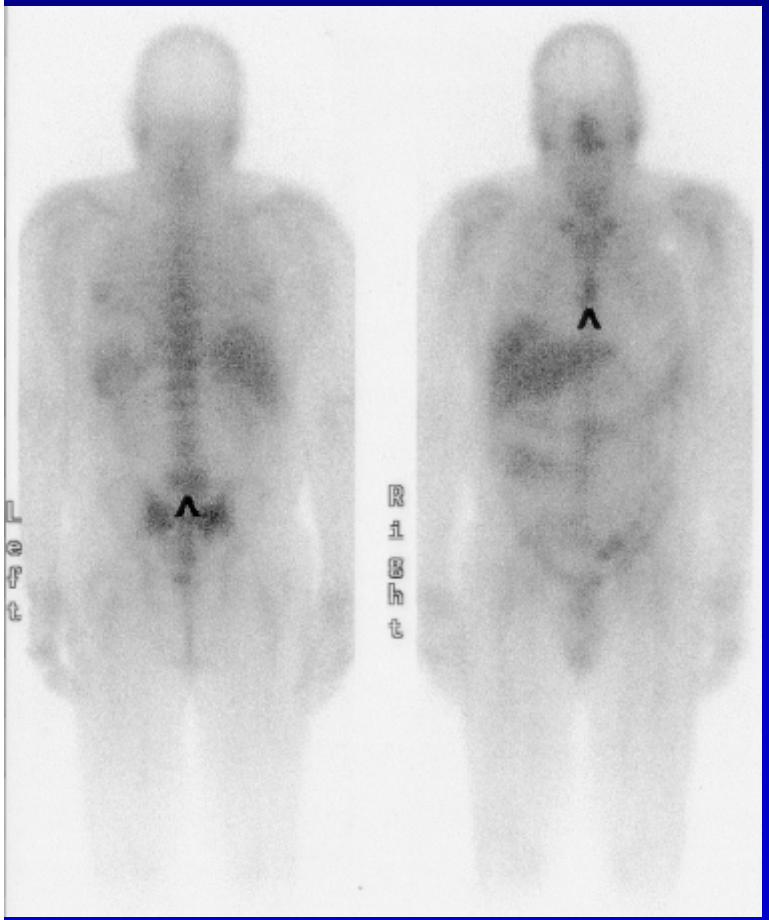

Transversal

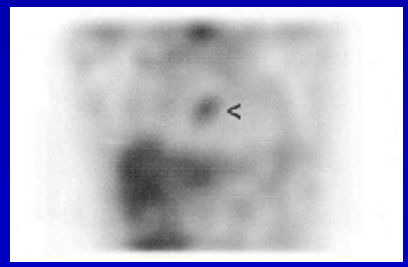

Coronal

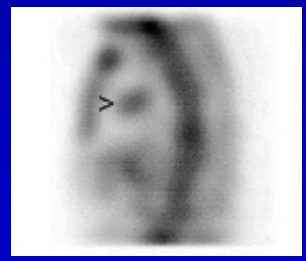

Sagital

SPECT clearly showed increased Ga-67 activity in the region of the aortic root, suspicious for infection.

Nuevas técnicas de imagen en Endocarditis Infecciosa. SPECT/TC y PET/TC

SPECT/TC:

Visualization of Infected Cardiac Pacemaker Leads by SPECT In-111 Leukocyte Imaging

Shayne Squires, MD, and Malik Juweid, MD

(*Clin Nucl Med* 2005;30: 584–585)

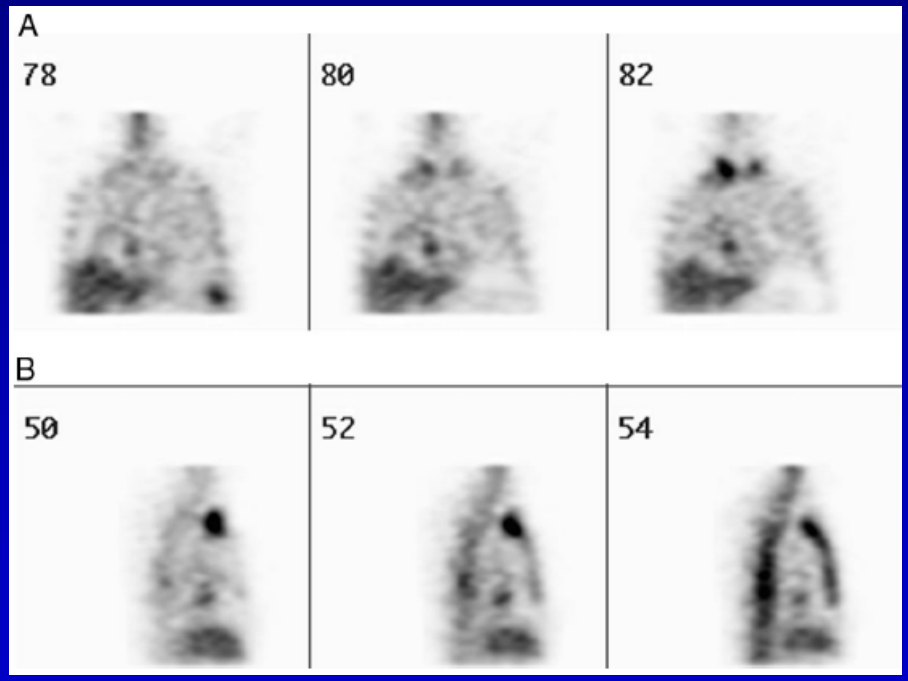

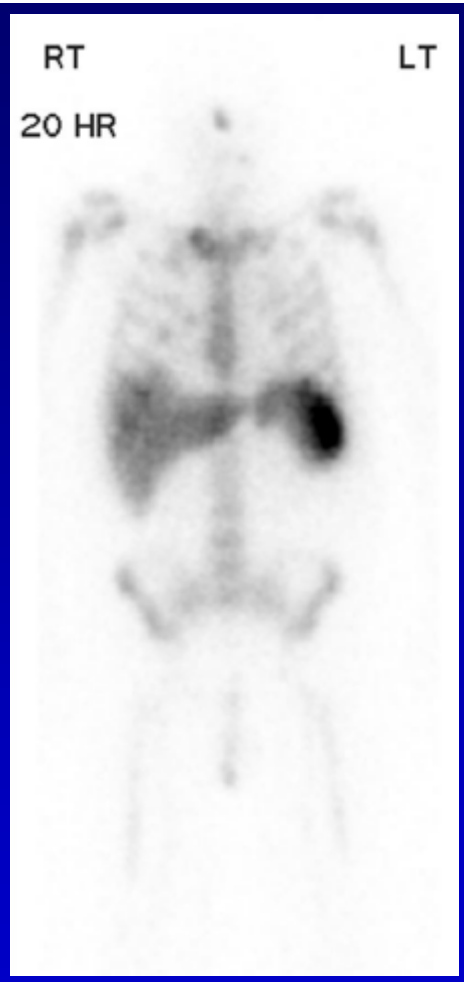

An In-111-labeled leukocyte study was performed to assess for infectious seeding of the pacemaker or shoulder joints. SPECT imaging revealed a focus of radiotracer uptake corresponding to the pacemaker leads that was not seen on the planar images. Transesophageal echo revealed vegetations on the pacer leads.

Nuevas técnicas de imagen en Endocarditis Infecciosa. SPECT/TC y PET/TC

SPECT/TC:

Evaluation of Tc-99m–Labeled Glycoprotein IIb/IIIa Receptor Antagonist DMP444 SPECT in Patients with Infective Endocarditis

FREDERIEKE M. BROUWERS, M.D.,*† WIM J. G. OYEN, M.D., PH.D.,* OTTO C. BOERMAN, PH.D.,*
JOHN A. BARRETT, PH.D.,‡ FREEK W. A. VERHEUGT, M.D., PH.D.,§
FRANS H. M. CORSTENS, M.D., PH.D.,* AND JOS W. M. VAN DER MEER, M.D., PH.D.†

(Clin Nucl Med 2003;28:480–484)

SPECT coronal

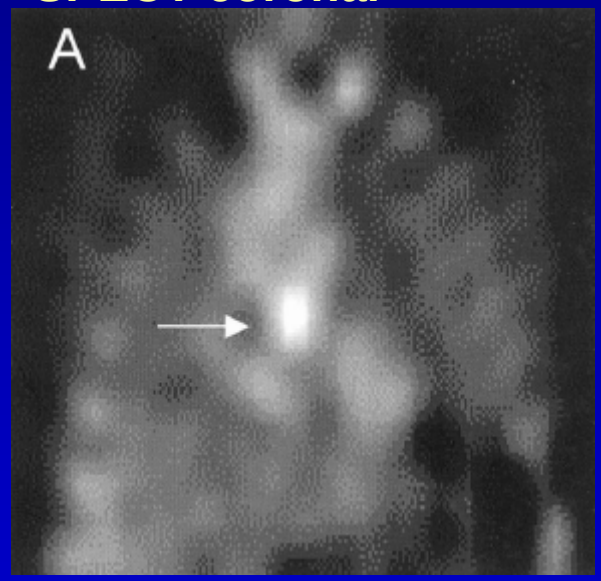

DMP444, a high-affinity glycoprotein IIb/IIIa receptor antagonist, binds to the fibrinogen-binding domain of activated platelets, depicting a key feature of IE.

The high affinity of DMP444 for activated platelets, the results indicate the involvement of activated platelets in early IE.

Nuevas técnicas de imagen en Endocarditis Infecciosa. SPECT/TC y PET/TC

SPECT/TC:

Radiolabeled WBC Scintigraphy in the Diagnostic Workup of Patients With Suspected Device-Related Infections

Paola A. Erba, MD,*† Martina Sollini, MD,† Umberto Conti, MD,‡ Francesco Bandera, MD,‡ Carlo Tascini, MD,§ Salvatore M. De Tommasi, MD,‡ Giulio Zucchelli, MD,‡ Roberta Doria, MD,§ Francesco Menichetti, MD,§ Maria Grazia Bongiorni, MD,‡ Elena Lazzeri, MD, PHD,*† Giuliano Mariani, MD*†

Sensitivity of ^{99m}Tc-HMPAO-WBC SPECT/CT was 94% for both detection and localization of CIED-associated infection.

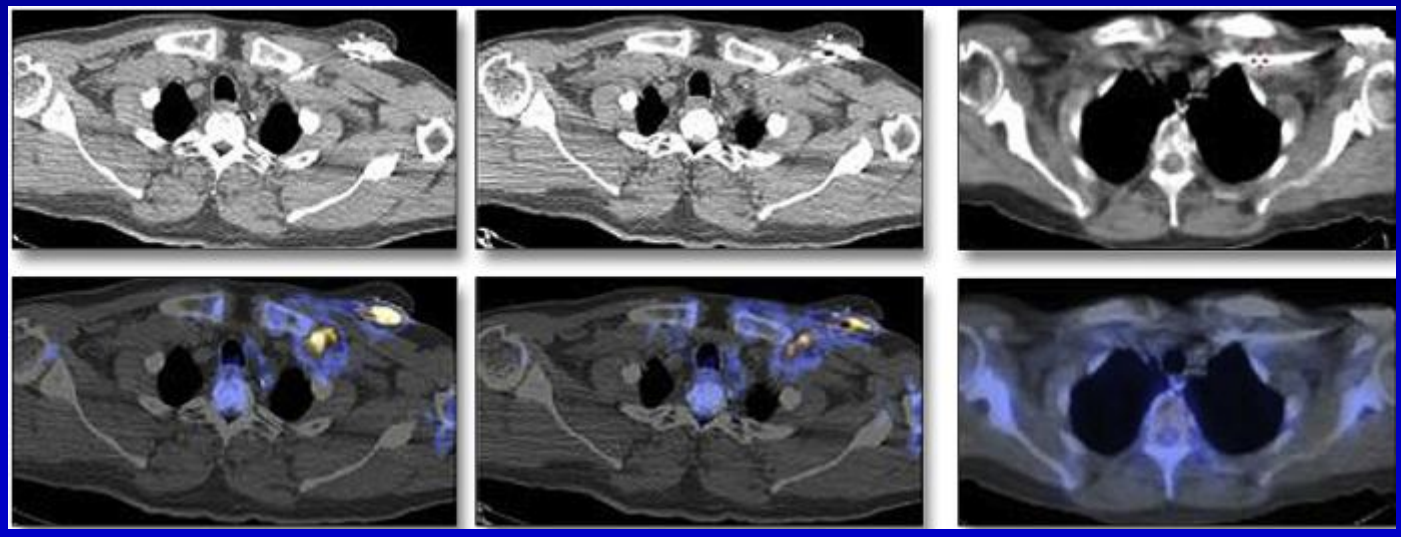

CONCLUSIONS: ^{99m}Tc-HMPAO-WBC scintigraphy enabled the confirmation of the presence of CIED-associated infection, definition of the extent of device involvement, and detection of associated complications. Moreover, ^{99m}Tc-HMPAO-WBC scintigraphy reliably excluded device-associated infection during a febrile episode and sepsis, with 95% negative predictive value.

Nuevas técnicas de imagen en Endocarditis Infecciosa. SPECT/TC y PET/TC

SPECT/TC:

Added Value of ^{99m}Tc-HMPAO–Labeled Leukocyte SPECT/CT in the Characterization and Management of Patients with Infectious Endocarditis

Paola A. Erba[1], Umberto Conti[2], Elena Lazzeri[1], Martina Sollini[1], Roberta Doria[3], Salvatore M. De Tommasi[4], Francesco Bandera[5], Carlo Tascini[3], Francesco Menichetti[3], Rudi A.J.O. Dierckx[6], Alberto Signore[6,7], and Giuliano Mariani[1]

J Nucl Med 2012; 53:1235–1243

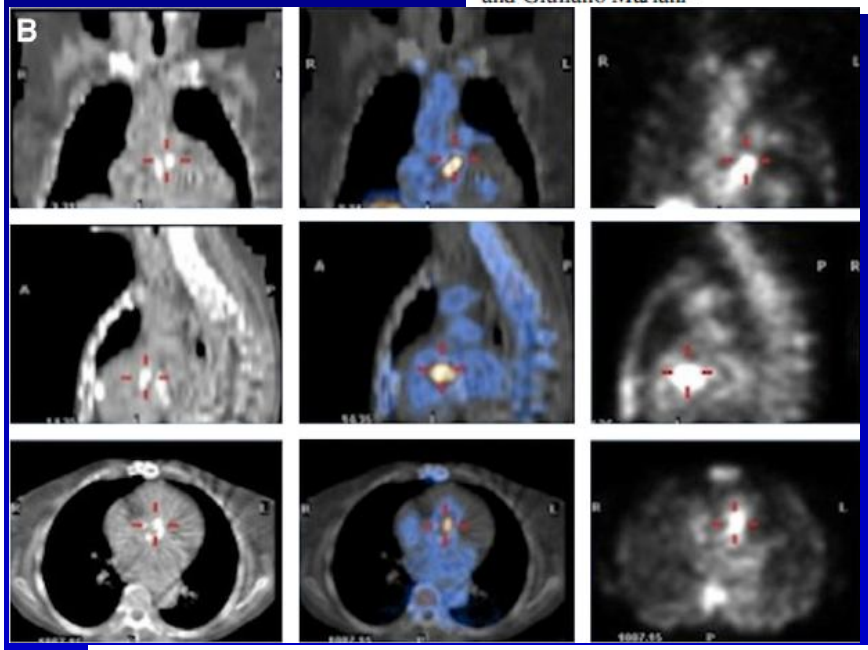

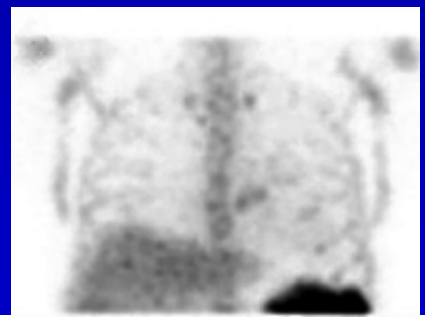

Conclusions: SPECT/CT is necessary to demonstrate and localize ^{99m}Tc-HMPAO-WBC at native or prosthetic valves, thus confirming the diagnosis of IE.

Negative results in the presence of a typical echocardiographic pattern for IE should be carefully evaluated, because false-negative findings due to limited spatial resolution or non–leukocyterecruiting microorganisms can be encountered.

SPECT/TC vs PET/TC:

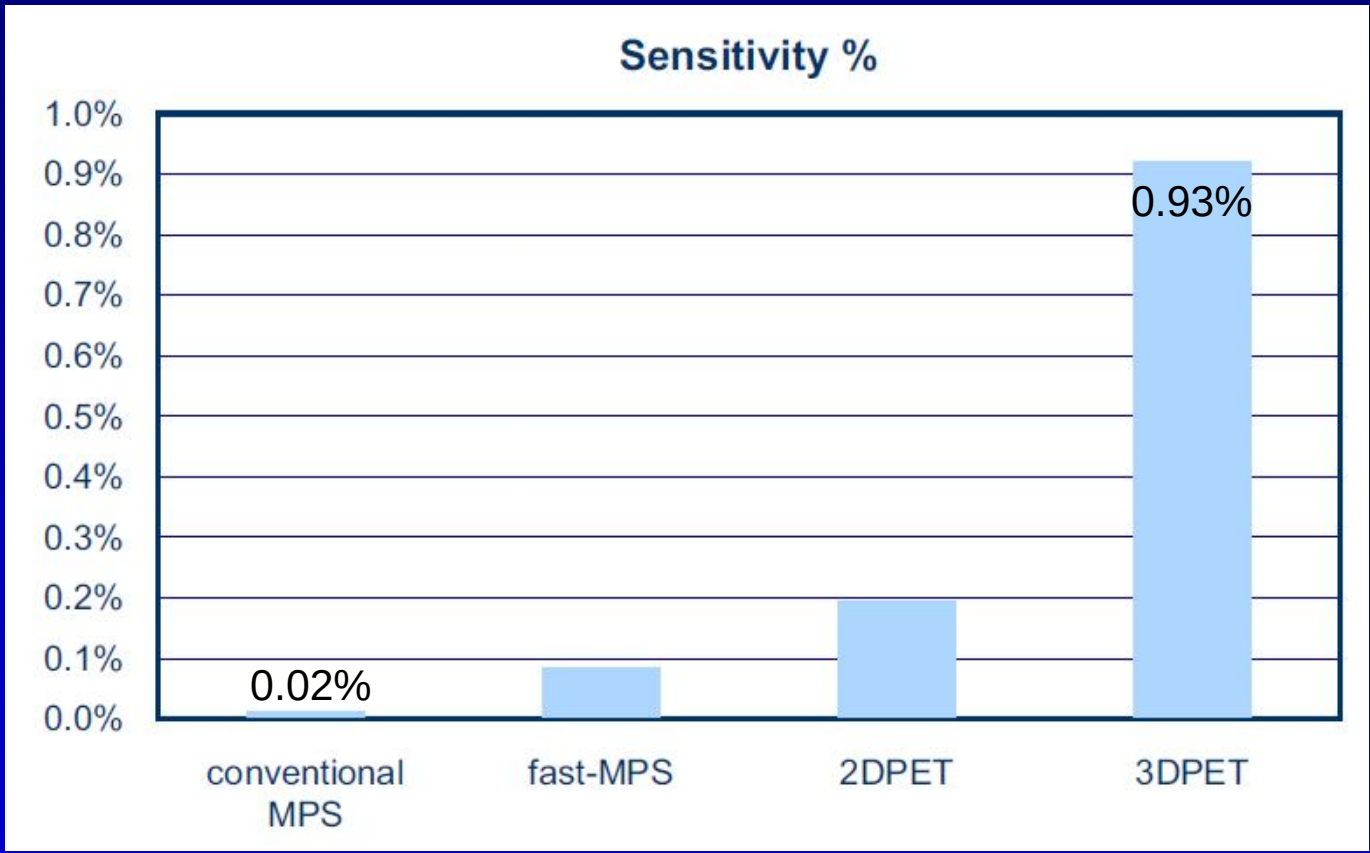

Diferencia de sensibilidad de detección entre equipos.

SPECT/TC gammacámara

2D 3D PET/TC

Nuevas técnicas de imagen en Endocarditis Infecciosa. SPECT/TC y PET/TC

PET/TC:

Imaging Infection with ^{18}F-FDG–Labeled Leukocyte PET/CT: Initial Experience in 21 Patients

Nicolas Dumarey, MD[1]; Dominique Egrise, PhD[1]; Didier Blocklet, MD[1]; Bernard Stallenberg, MD[2]; Myriam Remmelink, MD, PhD[3]; Véronique del Marmol, MD, PhD[4]; Gaëtan Van Simaeys, PhD[1]; Frédérique Jacobs, MD[5]; and Serge Goldman, MD, PhD[1]

J Nucl Med 2006; 47:625–632

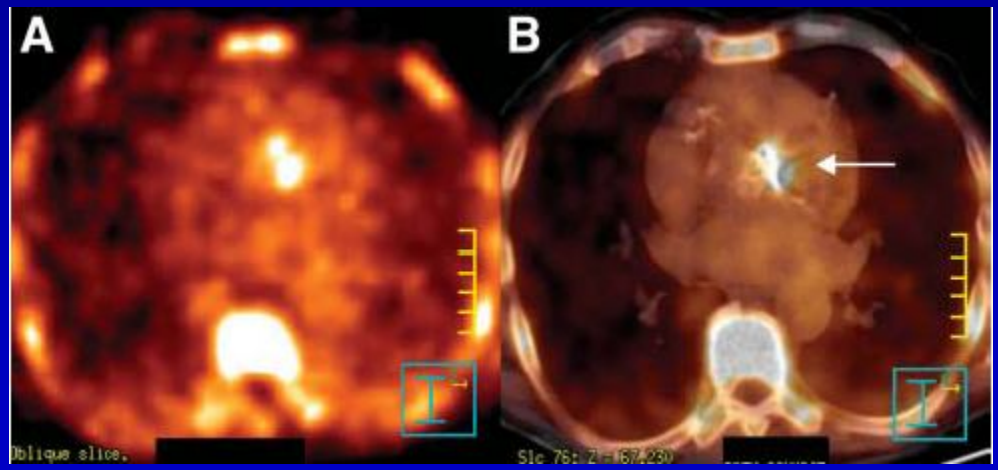

The median labeling efficiency was 80% (range, 24%–96%).

Wholebody PET and noncontrast-enhanced CT images were obtained at **3 h** after injection

This initial experience in 21 patients demonstrates the feasibility and the potential value of hybrid 18F-FDG–WBC PET/CT in infection. Our results show that 18F-FDG–WBC PET/CT is a promising technique with a high sensitivity and specificity and has major advantages over the more conventional nuclear medicine and radiologic methods.

PET/TC:

FDG-PET in Cardiac Infections

Paola A. Erba, MD,[*,†] Martina Sollini, MD,[†] Elena Lazzeri, MD, PhD,[*] and Giuliano Mariani, MD[*]

Semin Nucl Med 2013;43:377-395

^{18}F-FDG-PET is a well-established imaging modality for the diagnosis and management of malignancies, and evidenceis also increasing regarding its value for assessing infectious and inflammatory diseases.

- **Infective Endocarditis (IE)**
- **Cardiovascular Implantable Electronic Devices (CIED) Infections**
- **Acute Pericarditis**
- **Myocarditis**

The usefulness of ^{18}F-FDG-PET for the diagnosis of cardiac infections, mainly focused on endocarditis and cardiovascular device infections.

Nuevas técnicas de imagen en Endocarditis Infecciosa. SPECT/TC y PET/TC

PET/TC:

The value of ^{18}F-FDG PET/CT in diagnosing infectious endocarditis

Ilse J. E. Kouijzer · Fidel J. Vos · Marcel J. R. Janssen · Arie P. J. van Dijk · Wim J. G. Oyen · Chantal P. Bleeker-Rovers

Eur J Nucl Med Mol Imaging 2013 (40):1102-1107

Preparación convencional:

S : 39%

E : 93%

PET 3D sin HR ni TOF

TC sin contraste

Varón 65 a.
Fiebre
Bacteriemia Estreptococo B
FDG PET/CT: v. aórtica

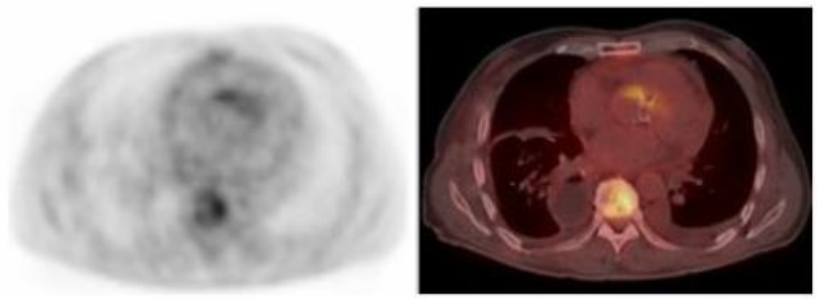

Varón 71 a.
Fiebre
Bacteriemia S. aureus
FDG PET/CT: v. mitral

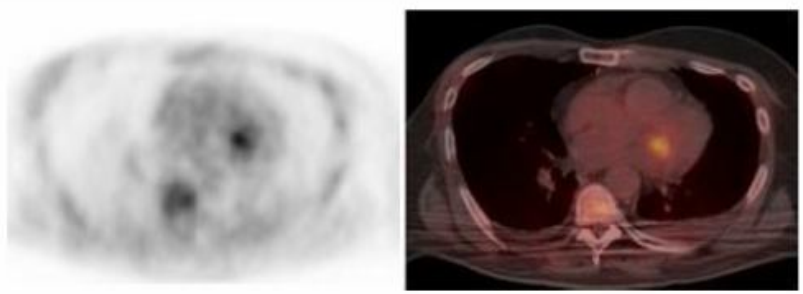

Nuevas técnicas de imagen en Endocarditis Infecciosa. SPECT/TC y PET/TC

PET/TC:

18-Fluoro-2-deoxyglucose positron emission tomography–computed tomography: an additional tool in the diagnosis of prosthetic valve endocarditis☆

Alessandra Ricciardi [a], Pasquale Sordillo [a], Laura Ceccarelli [a], Gaetano Maffongelli [a], Giorgio Calisti [b], Barbara Di Pietro [c], Cristiana Ragano Caracciolo [c], Orazio Schillaci [c], Antonio Pellegrino [d], Luigi Chiariello [d], Massimo Andreoni [a], Loredana Sarmati [a,*]

International Journal of Infectious Diseases
Accepted 26 April 2014. IN PRESS

Retrospectively examined 27 consecutive patients.
The final IE diagnosis was defined according to the modified Duke criteria, and the microbiological and diagnostic results were collected for each patient.

Results: Twenty out of 27 patients had a suspected prosthetic valve endocarditis (PVE) and 7 had a suspected native valve endocarditis (NVE).

ECHO showed a higher sensitivity as a diagnostic tool for the detection of IE compared to PET/CT (80% vs. 55%).

Analyzing only the cases who underwent transoesophageal ECHO, **PET/CT showed a sensitivity of 85% in PVE** (vs. 69% for echocardiography and 77% for the Duke criteria).

All seven patients with NVE had a positive echocardiography and negative PET/CT findings ($p < 0.001$).

Conclusions: The results of this study further highlight the limitations of ECHO in the diagnosis of PVE and the potential advantages of PET/CT in these cases.

Nuevas técnicas de imagen en Endocarditis Infecciosa. SPECT/TC y PET/TC

PET/TC:

Clin Microbiol Infect 2011; **17**: 836–844 L. Bensimhon, Paris, Francia.

Whole body [^{18}F]fluorodeoxyglucose positron emission tomography imaging for the diagnosis of pacemaker or implantable cardioverter defibrillator infection: a preliminary prospective study

Europace (2013) **15**, 252–257 J. Cautela, Marsella, Francia.

Diagnostic yield of FDG positron-emission tomography/computed tomography in patients with CEID infection: a pilot study

Role of ^{18}F-FDG PET/CT in the diagnosis of infective endocarditis in patients with an implanted cardiac device: a prospective study

Maddalena Graziosi · Cristina Nanni · Massimiliano Lorenzini · Igor Diemberger · Rachele Bonfiglioli · Ferdinando Pasquale · Matteo Ziacchi · Mauro Biffi · Cristian Martignani · Michele Bartoletti · Fabio Tumietto · Giuseppe Boriani · Pier Luigi Viale · Stefano Fanti · Claudio Rapezzi

Eur J Nucl Med Mol Imaging (2014) 41:1617–1623

In patients with a cardiac device, PET/CT increases the diagnostic accuracy of the modified Duke criteria for IE, particularly in the subset of patients with possible IE in whom it may help the clinician manage a challenging situation.

Nuevas técnicas de imagen en Endocarditis Infecciosa. SPECT/TC y PET/TC

PET/TC:

J Am Coll Cardiol 2012;59:1616–25 J. Sarrazin, Quebec, Canadá.

Usefulness of Fluorine-18 Positron Emission Tomography/ Computed Tomography for Identification of Cardiovascular Implantable Electronic Device Infections

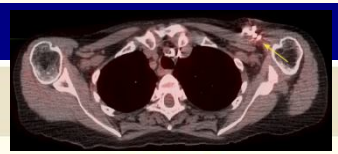

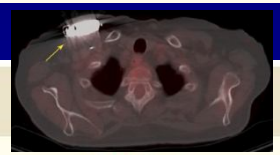

Table 2 ^{18}F-FDG PET/CT Results

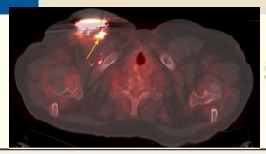

	Group A Suspected CIED Infection (n = 42)	Group B Controls Acute Phase (n = 12)	Group C Controls Chronic Phase (n = 12)	p Value
Maximal SUV	4.4 ± 1.6	1.2 ± 1.4	0	<0.001
Qualitative visual score				
Median	2.0	0.8	0	<0.001*
Lower quartile	1.3	0.5		
Upper quartile	2.5	1.0		
Semi-quantitative ratio				
Median	2.02	1.08	0.57	<0.001†
Lower quartile	1.30	0.84	0.40	
Upper quartile	2.98	1.31	0.62	
Infección confirmada:	35 (83%)	0	0	

- ✓ **LOS PACIENTES INFECTADOS TIENEN NIVELES DE CAPTACIÓN DE FDG SIGNIFICATIVAMENTE SUPERIORES RESPECTO A LOS PACIENTES NO INFECTADOS.**
- ✓ **PASADAS LAS 6 SEMANAS DEL IMPLANTE, LA CAPTACIÓN DE FDG PARECE SER MUY BAJA, POR LO QUE UNA CAPTACIÓN FOCAL IMPORTANTE ES SUGESTIVA DE INFECCIÓN.**

PET/TC:

- PET/TC EN LAS ENDOCARDITIS PROTÉSICAS Y DE DISPOSITIVOS
  - METODOLOGÍA
  - DISPOSITIVOS
  - ENDOCARDITIS NATIVA
  - ENDOCARDITIS PROTÉSICA
  - DOBLES DISPOSITIVOS

Vall d'Hebron Hospital

Nuevas técnicas de imagen en Endocarditis Infecciosa. SPECT/TC y PET/TC

SEICAV
Sociedad Española de Infecciones Cardiovasculares

METODOLOGÍA DE LA PET/angioTC

^{18}F-FDG

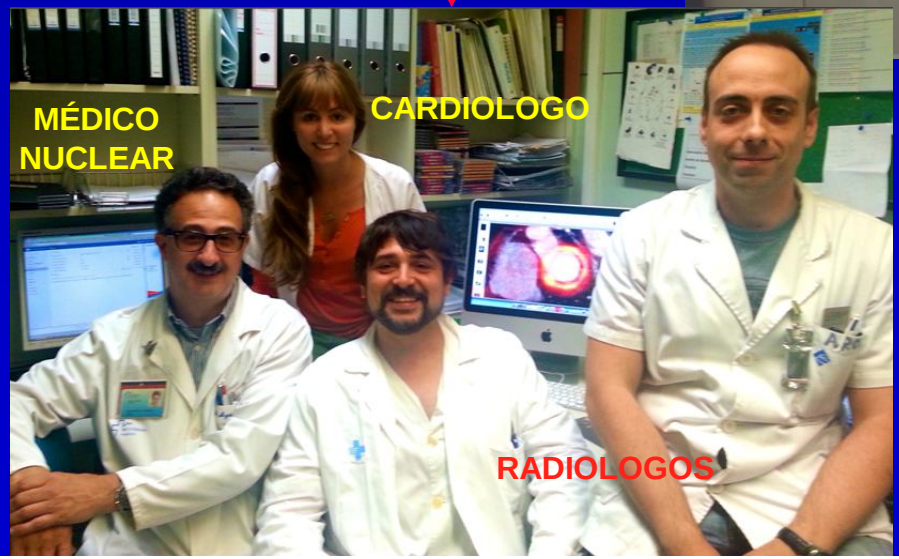

METODOLOGÍA DE LA PET/angioTC

Preparación:

- Ayuno prolongado (hasta 12 horas)
- Dieta (rica en grasa y pobre en gúcidos)
- Heparina EV (50 UI/Kg) 15 minutos antes de la FDG

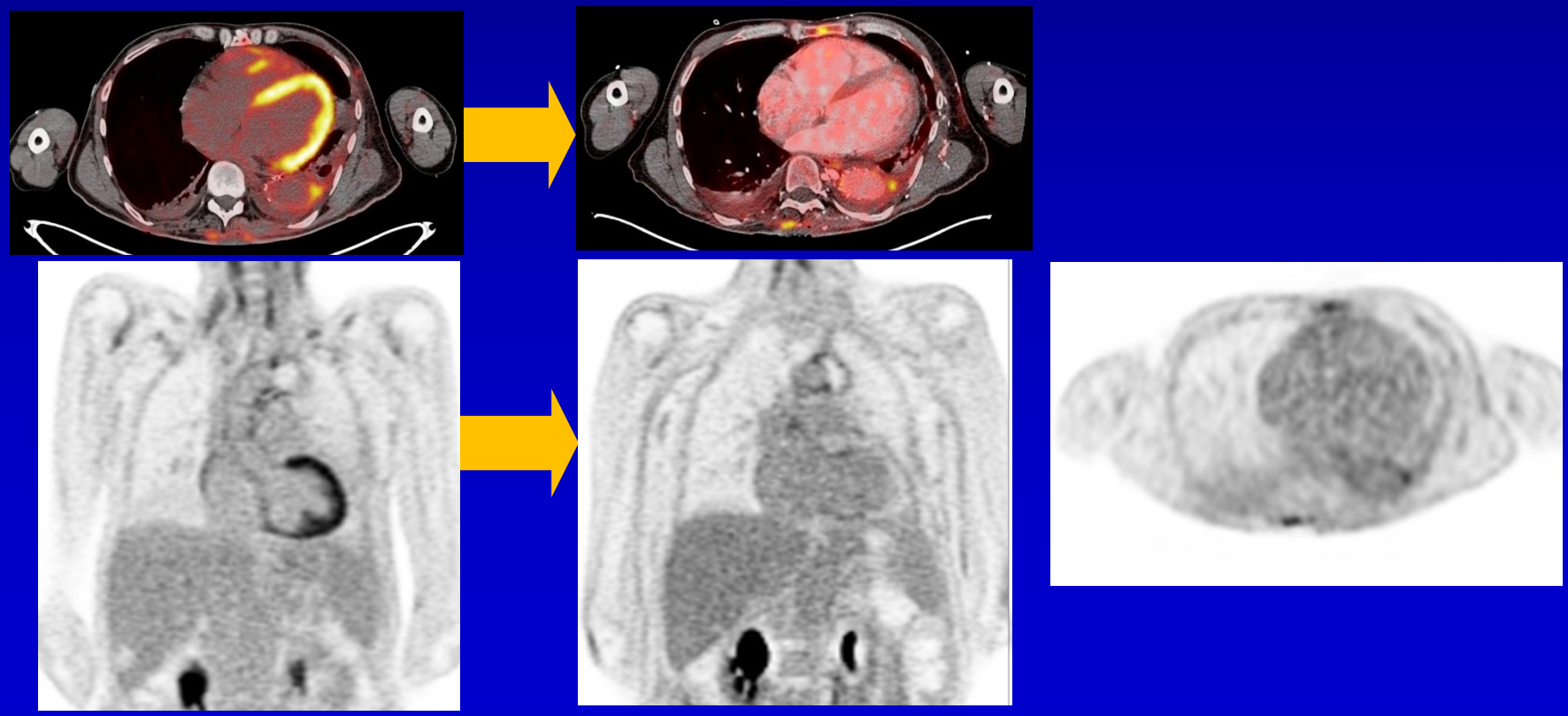

METODOLOGÍA DE LA PET/angioTC

El protocolo consta de:

- Supresión miocárdica con ayuno y heparina EV (50 UI/Kg unos 15 minutos antes de la dosis de FDG)
- Se realizó una PET/TC con ^{18}F-FDG de cuerpo entero, un bed cardíaco sincronizado y una angioTC con contraste sincronizada en un equipo SIEMENS mCT 64S.

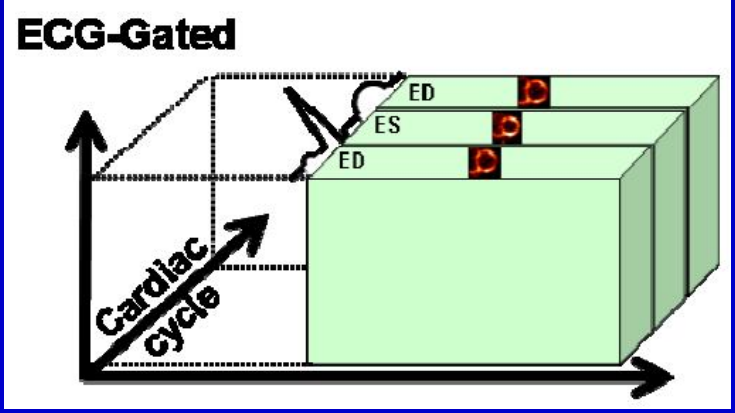

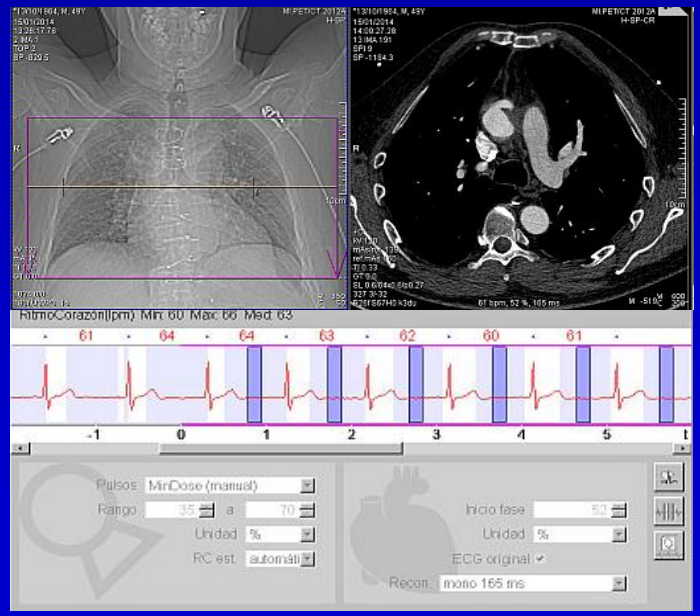

METODOLOGÍA DE LA PET/angioTC

Realización:

- Administración de la ^{18}F-FDG EV
- Espera mínima 60 minutos
- Toma de las imágenes:
  - Whole body PET-TC [8-12 min.]
  - Bed cardíaco (sincronizado) [8 min.]
  - Angio TC (sincronizado) con contraste [1 min.]
- Imágenes tardías (si procede) [8 min.]

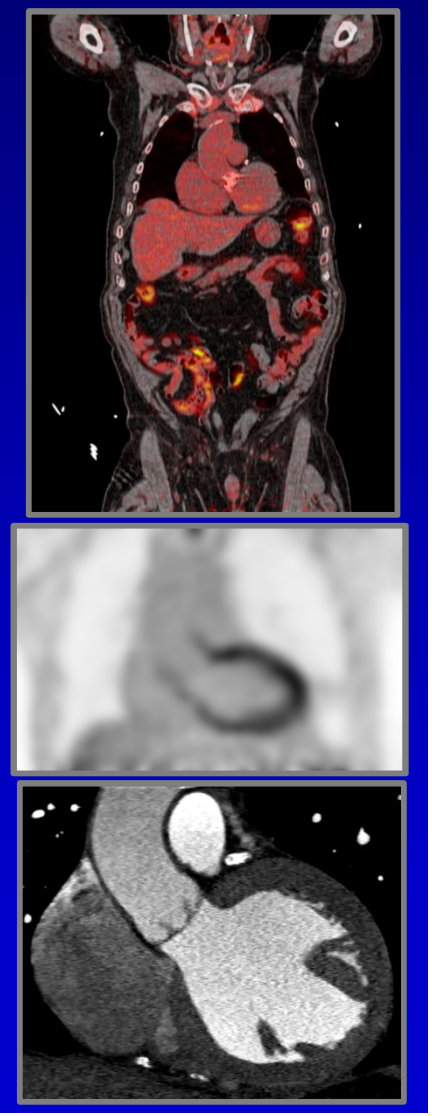

METODOLOGÍA DE LA PET/angioTC

PET-TC CUERPO ENTERO →
. Capración folal de FDG
. Embolismos periféricos
. Otras lesiones (Neoplasias)

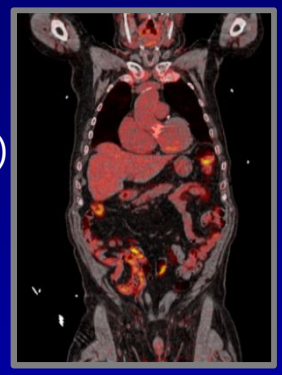

- PET (6 beds def 2 minutos)
- CT de baja dosis (mapa de atenuación y localización anatómica)

GATED CARDIAC PET-TC → Mejora la visualización del area cardíaca (ECG gated-PET)

1 Bed de 8 minutos

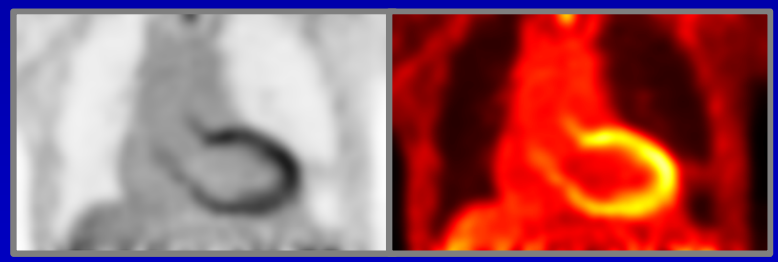

ANGIO-TC-CARDÍACO → Alta resolución espacial y de contraste (ECG gated-CT)

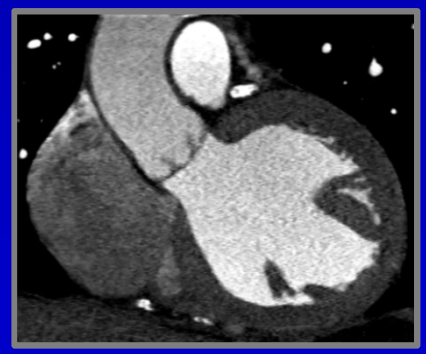

Dosimetría: **PET** 3 mSv
CT: variable según el estudio 5-8 mSv

Nuevas técnicas de imagen en Endocarditis Infecciosa. SPECT/TC y PET/TC

METODOLOGÍA DE LA PET/angioTC

WB TC

WB PET

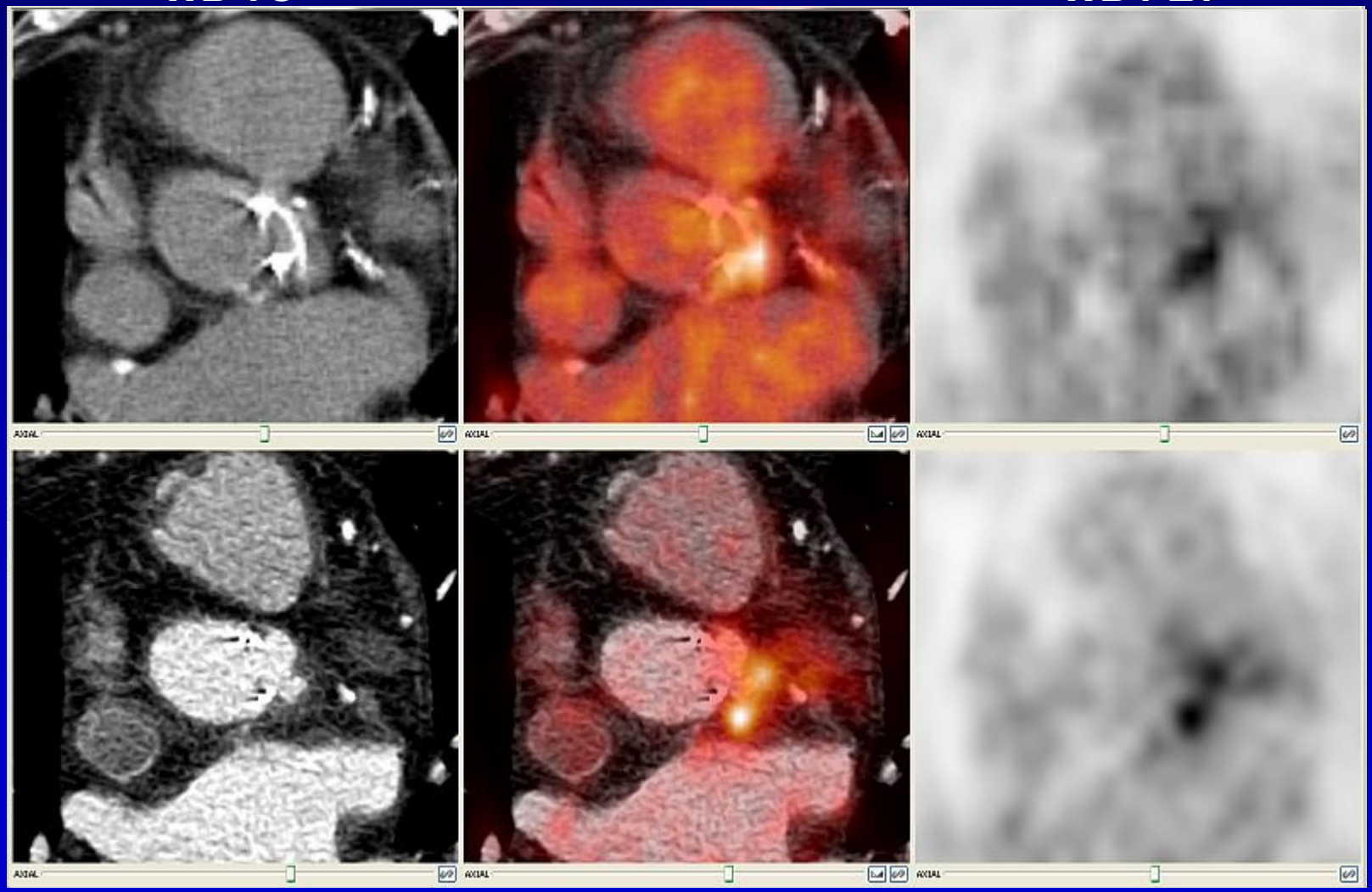

angio TC sincronizado

Bed cardíaco sincronizado

METODOLOGÍA DE LA PET/angioTC

- ✓ Combina la máxima resolución espacial del TC (lesiones anatómicas) y máxima sensibilidad de la imagen metabólica (detección de infección).

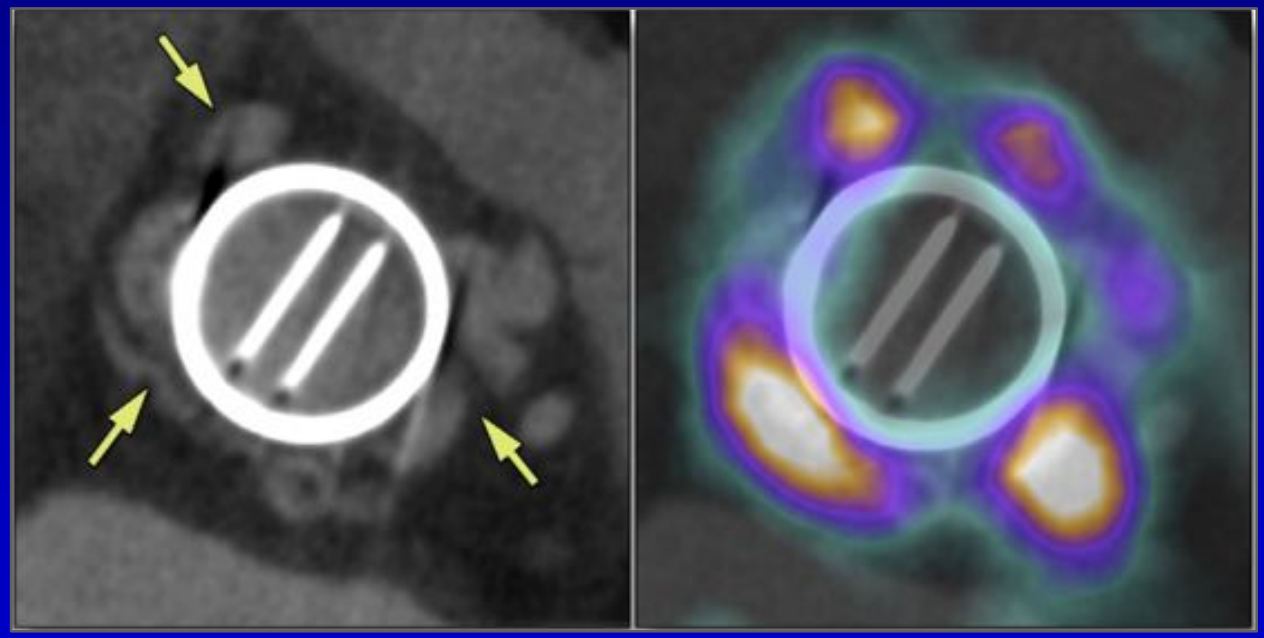

- ✓ Evaluación coronaria prequirúrgica.

Vall d'Hebron Hospital

Nuevas técnicas de imagen en Endocarditis Infecciosa. SPECT/TC y PET/TC

SEICAV
Sociedad Española de Infecciones Cardiovasculares

METODOLOGÍA DE LA PET/angioTC

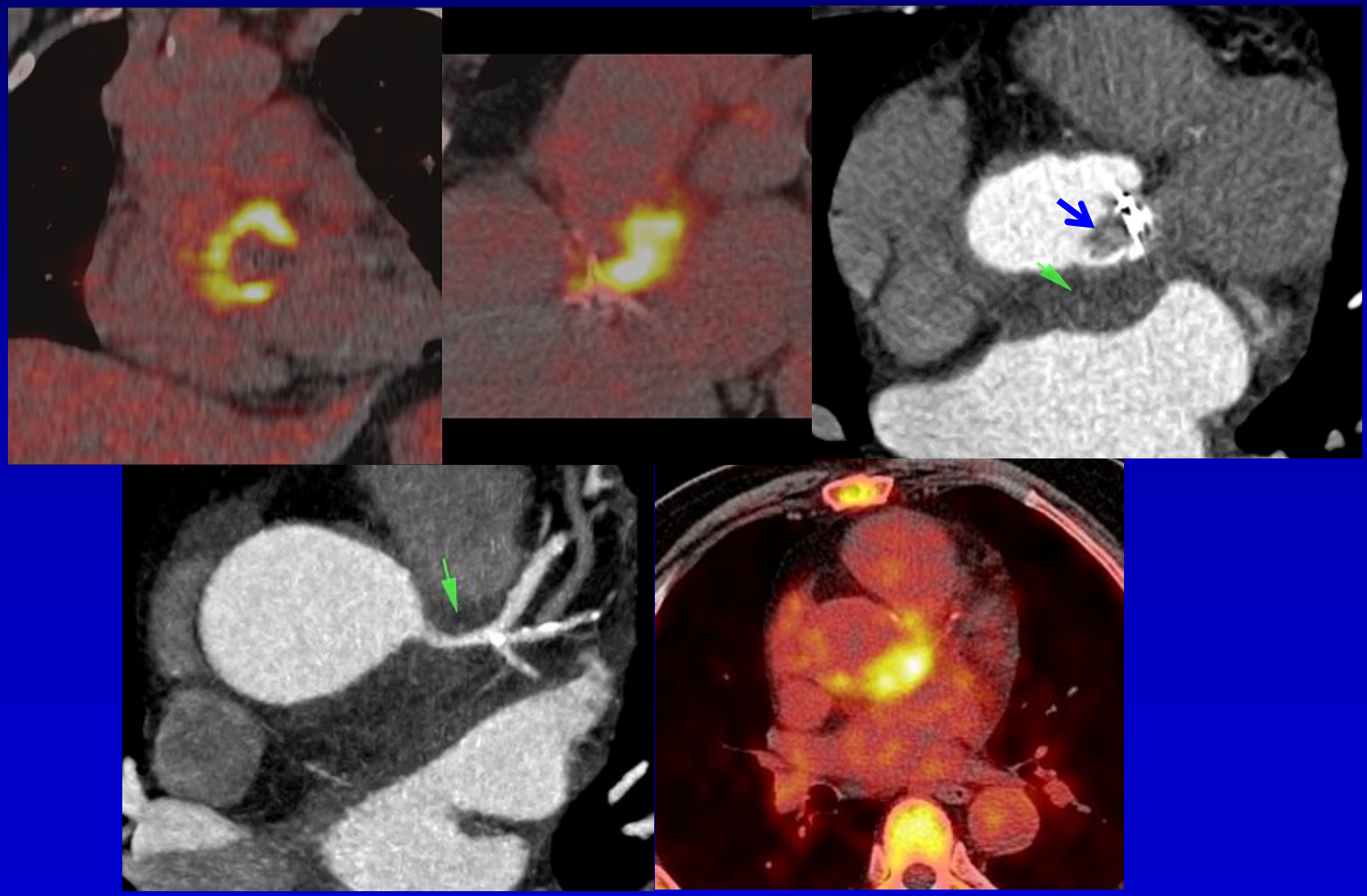

Nuevas técnicas de imagen en Endocarditis Infecciosa. SPECT/TC y PET/TC

METODOLOGÍA DE LA PET/angioTC

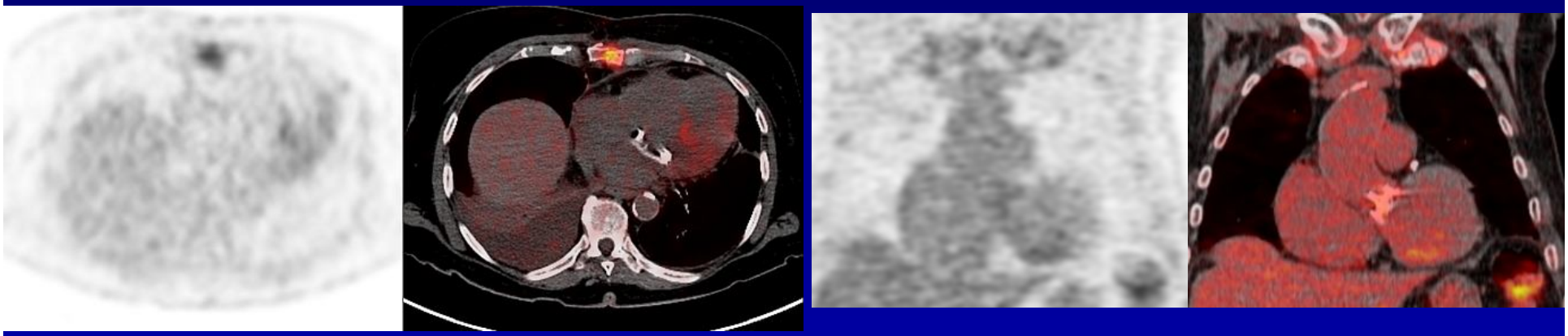

Descartar la afectación

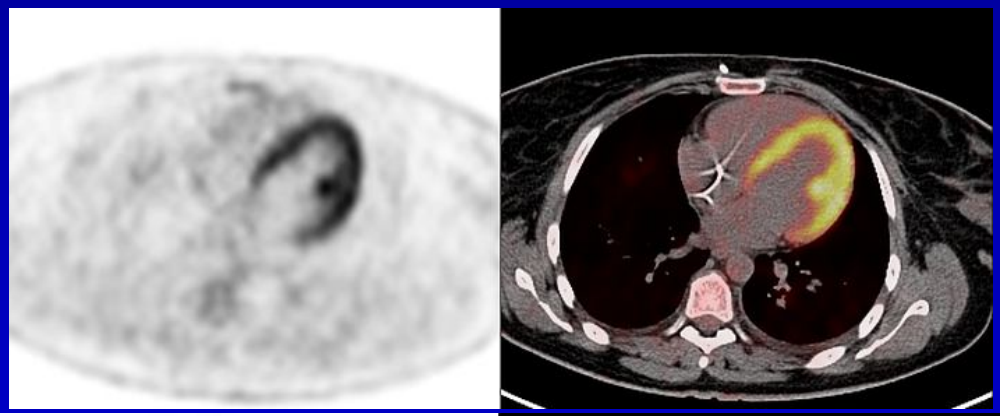

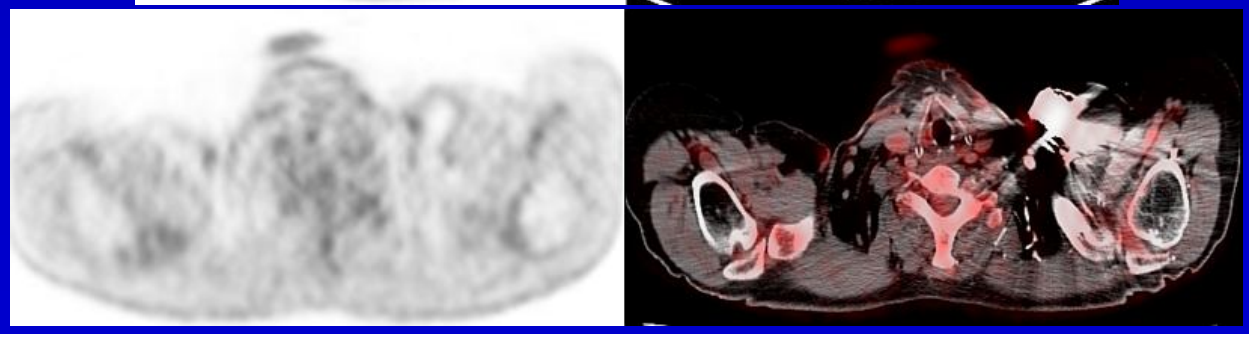

Vall d'Hebron Hospital

Nuevas técnicas de imagen en Endocarditis Infecciosa. SPECT/TC y PET/TC

SEICAV
Sociedad Española de Infecciones Cardiovasculares

METODOLOGÍA DE LA PET/angioTC

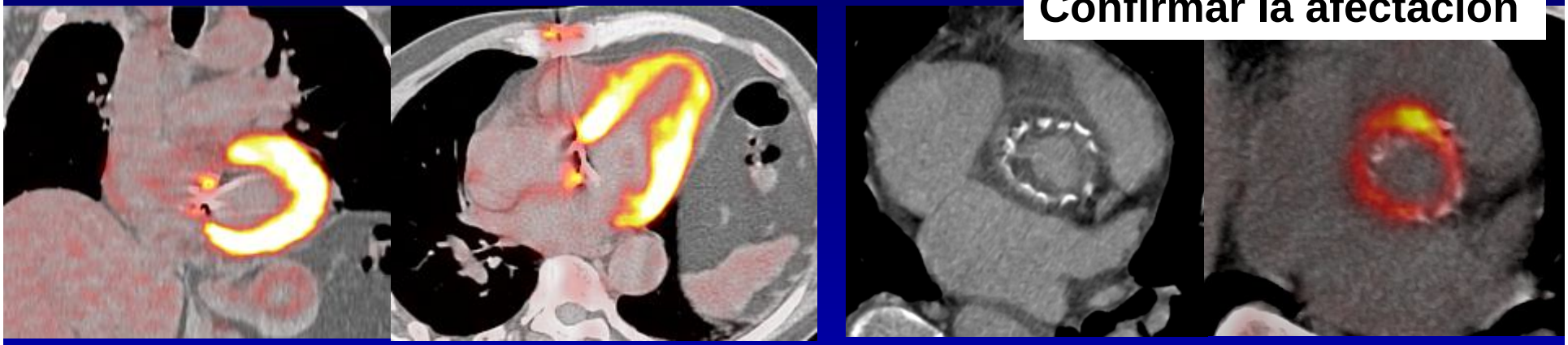

Confirmar la afectación

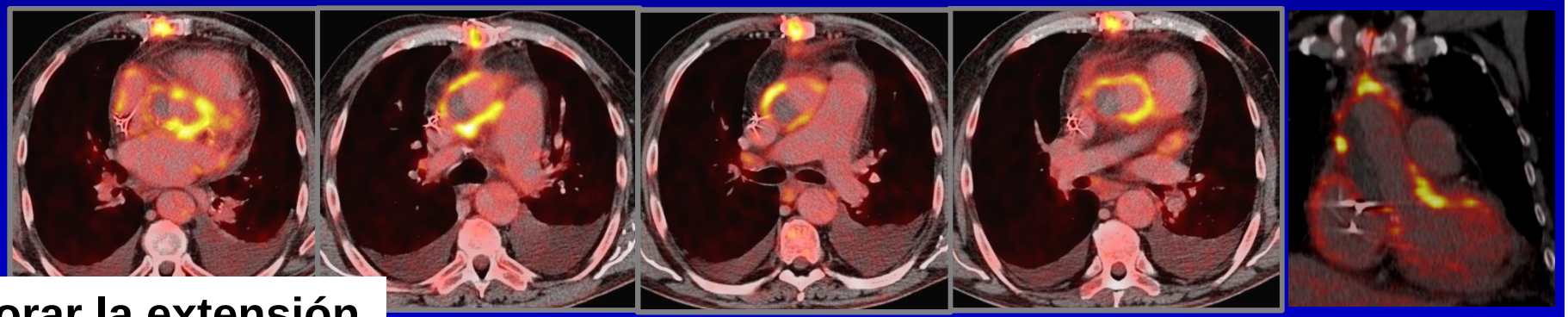

Valorar la extensión

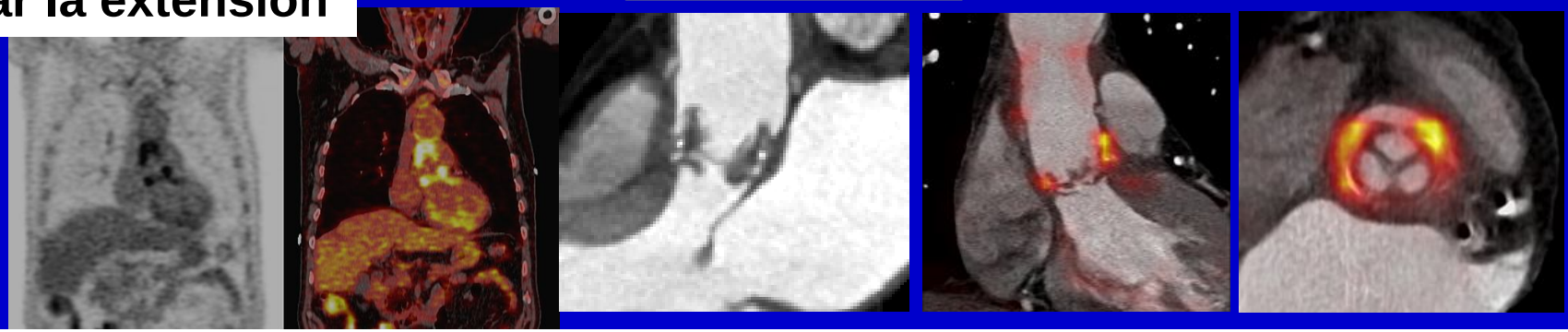

PET/TC:

- PET/TC EN LAS ENDOCARDITIS PROTÉSICAS Y DE DISPOSITIVOS
  - METODOLOGÍA
  - DISPOSITIVOS
  - ENDOCARDITIS NATIVA
  - ENDOCARDITIS PROTÉSICA
  - DOBLES DISPOSITIVOS

Nuevas técnicas de imagen en Endocarditis Infecciosa. SPECT/TC y PET/TC

PET-TC EN DISPOSITIVOS

MARCAPASOS/DAI

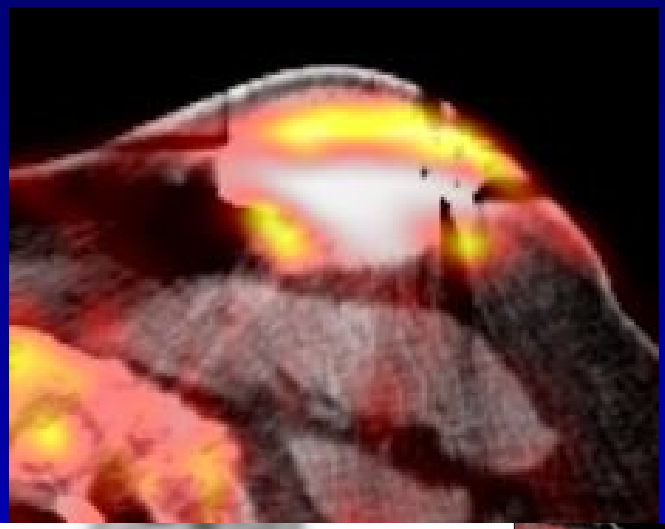

Valoración conjunta de bolsa y cables, tanto en el trayecto extravascular, como intravascular e intracardíaco.

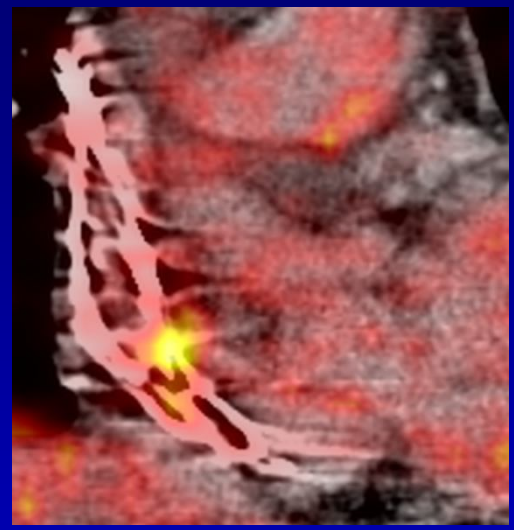

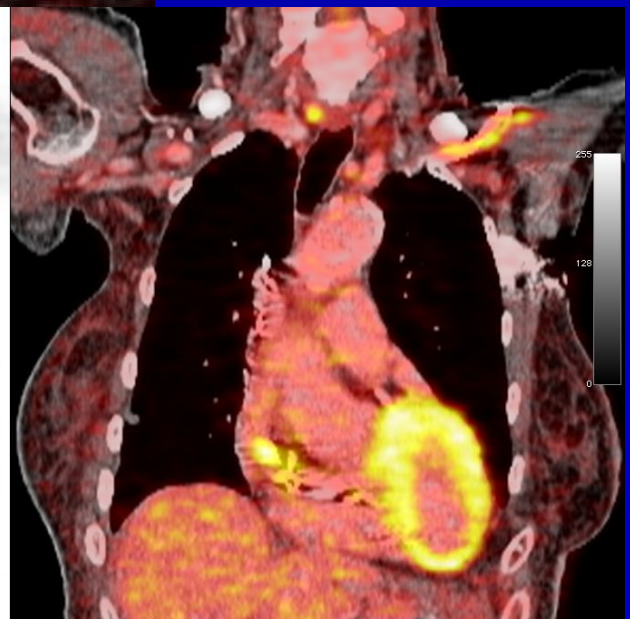

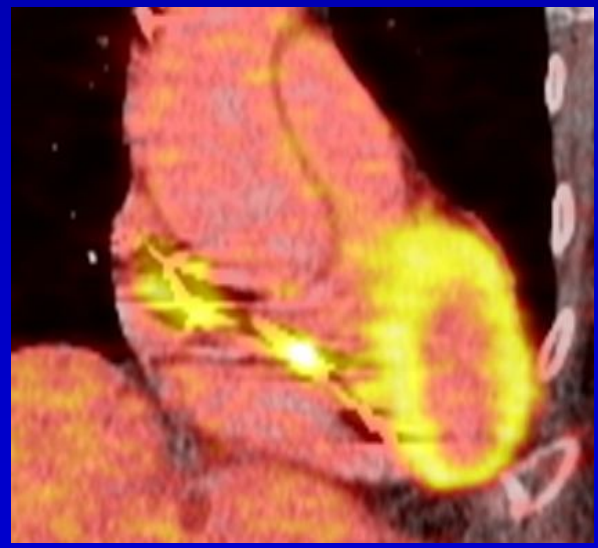

Nuevas técnicas de imagen en Endocarditis Infecciosa. SPECT/TC y PET/TC

PET-TC EN DISPOSITIVOS

MARCAPASOS/DAI

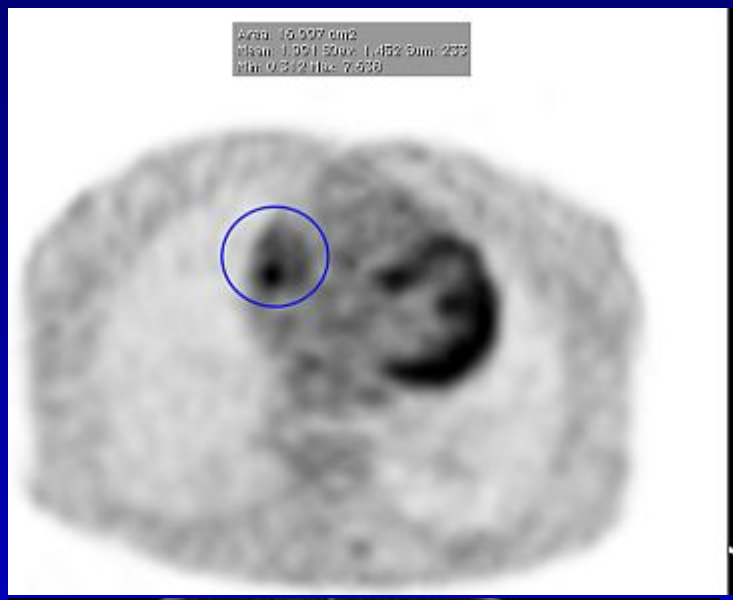

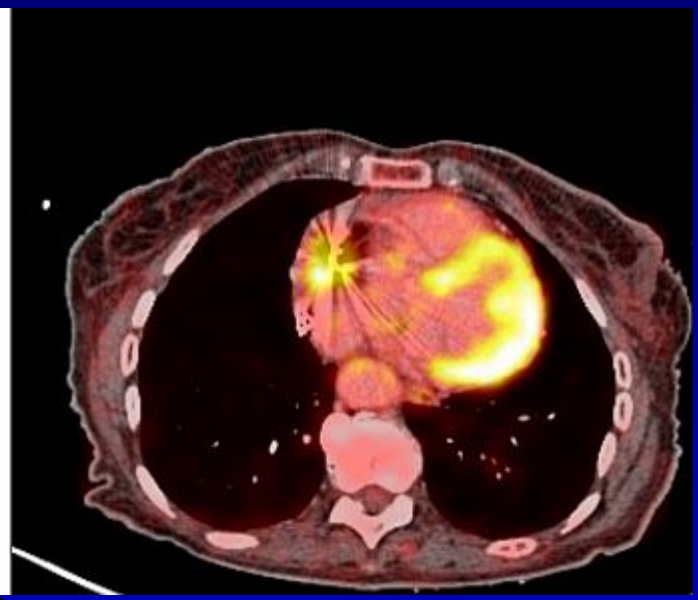

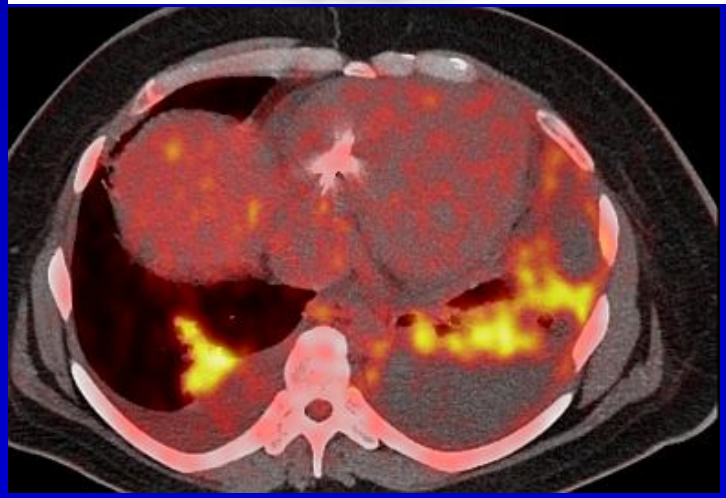

Pneumonia

- ✓ Confirmar/Excluir el diagnostico en casos de ECO dudoso o negativo.
- ✓ Puede discriminar infección de inflamación residual por el implante.
- ✓ Extensión de la infección: piel, bolsa, generador, cables intra-extracardíacos.
- ✓ Embolismo pulmonar asociado.

PET/TC:

- PET/TC EN LAS ENDOCARDITIS PROTÉSICAS Y DE DISPOSITIVOS
  - METODOLOGÍA
  - DISPOSITIVOS
  - ENDOCARDITIS NATIVA
  - ENDOCARDITIS PROTÉSICA
  - DOBLES DISPOSITIVOS

PET-TC EN ENDOCARDITIS NATIVA

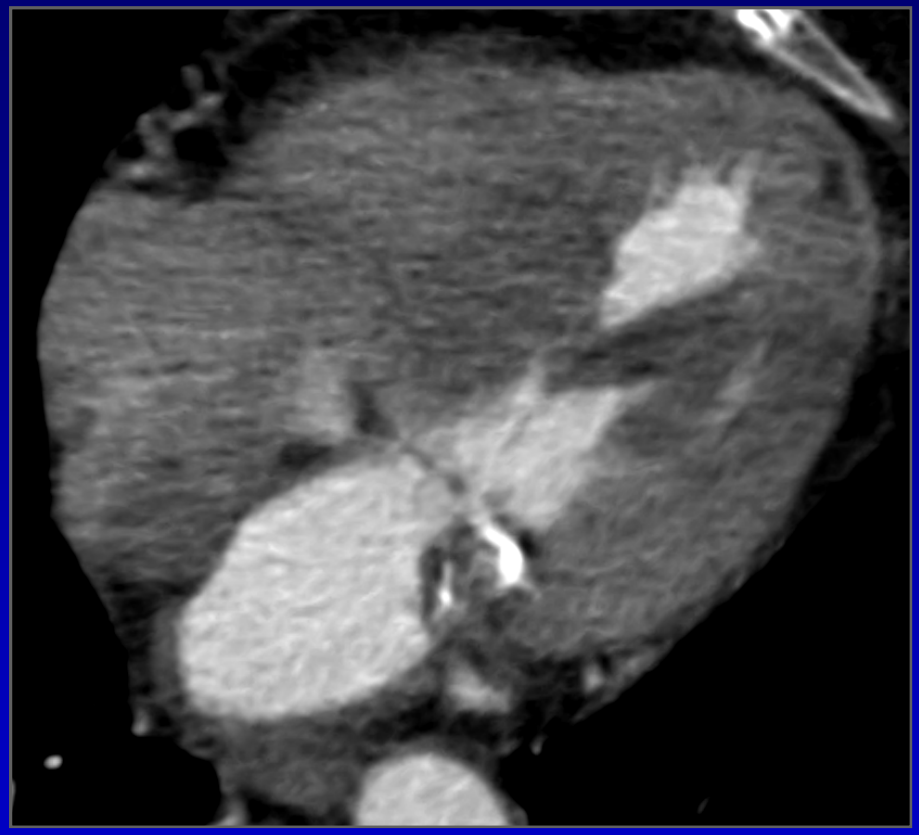

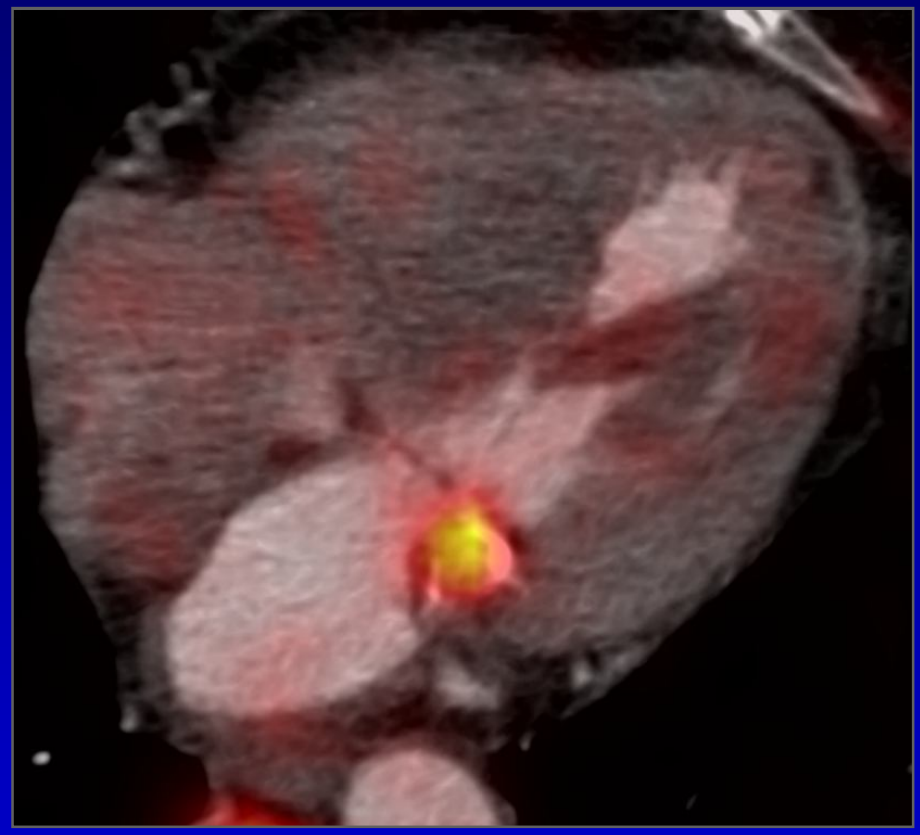

VÁLVULA MITRAL NATIVA

Calcificación severa, gran vegetación auricular adherida.

PET-TC EN ENDOCARDITIS NATIVA

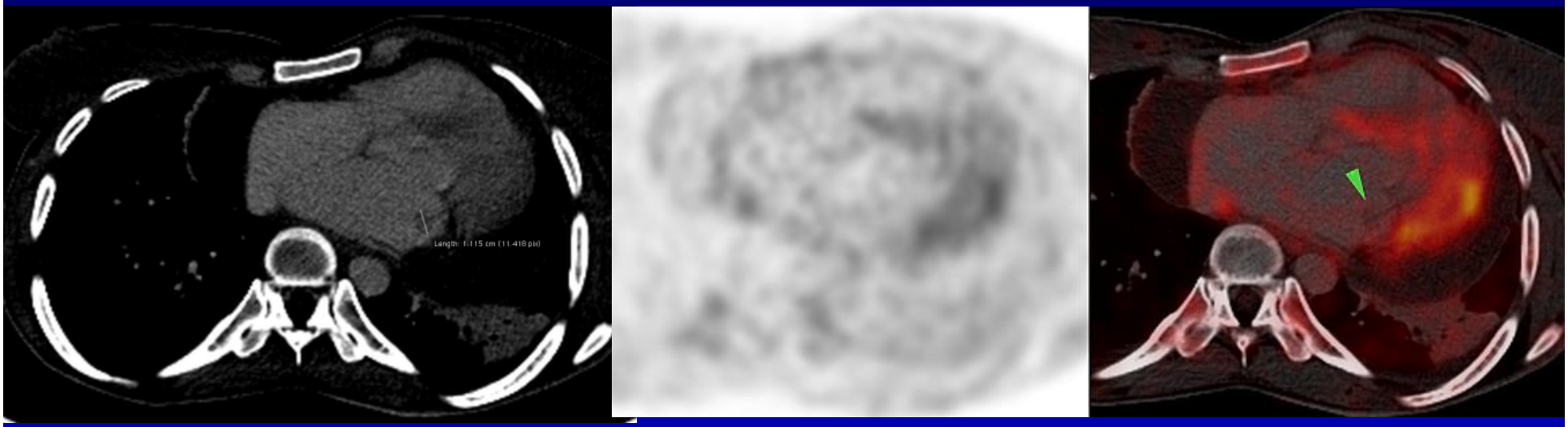

Difícil captación de la vegetación aislada

ENDOCARDITIS NATIVA:

- ✓ solo casos aislados.
- ✓ su rendimiento se ve muy afectado por la dificultad en la frenación miocárdica.

PET/TC:

- PET/TC EN LAS ENDOCARDITIS PROTÉSICAS Y DE DISPOSITIVOS
  - METODOLOGÍA
  - DISPOSITIVOS
  - ENDOCARDITIS NATIVA
  - ENDOCARDITIS PROTÉSICA
  - DOBLES DISPOSITIVOS

Vall d'Hebron Hospital

Nuevas técnicas de imagen en Endocarditis Infecciosa. SPECT/TC y PET/TC

SEICAV
Sociedad Española de Infecciones Cardiovasculares

PET-TC EN ENDOCARDITIS PROTÉSICA

VÁLVULA AÓRTICA

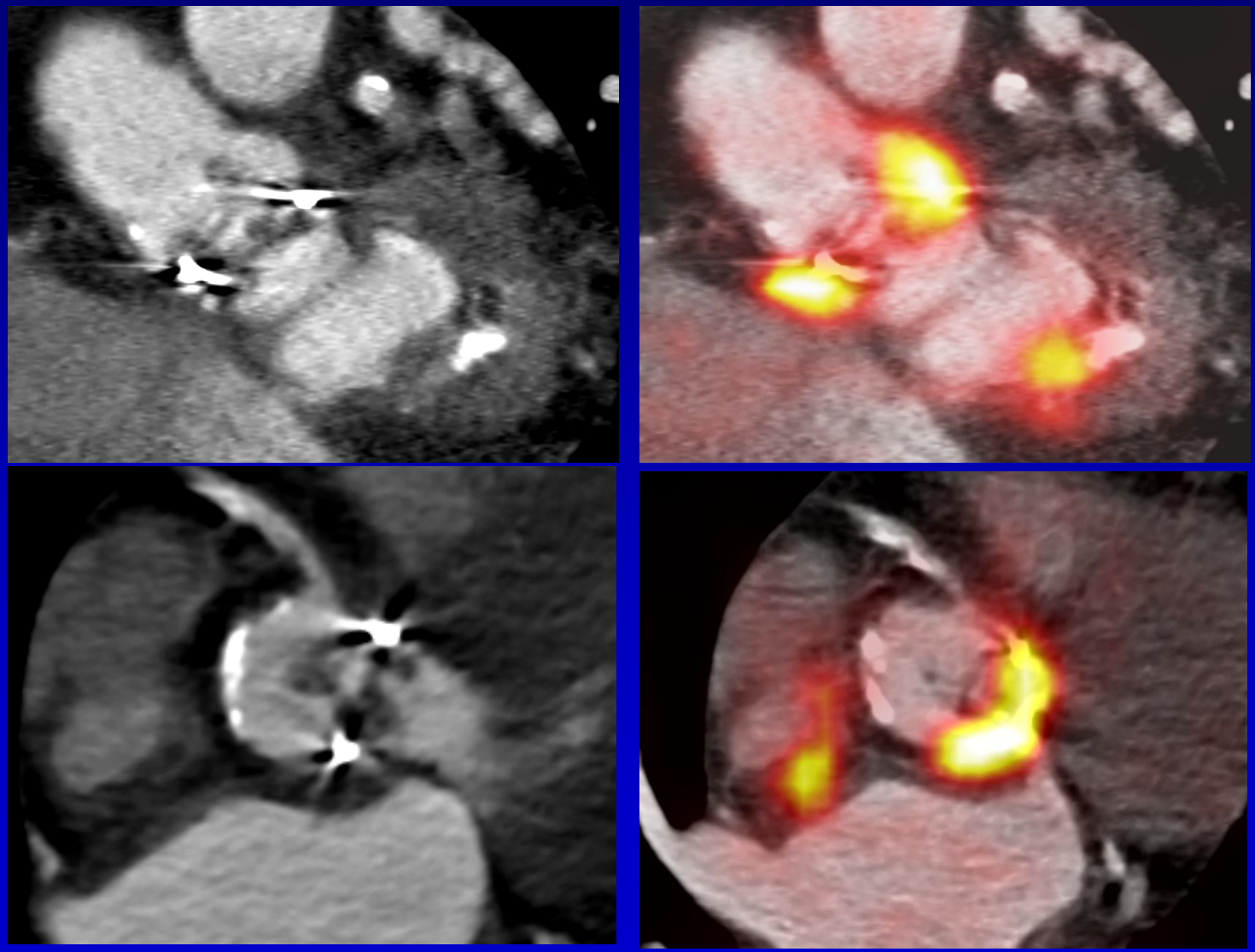

Nuevas técnicas de imagen en Endocarditis Infecciosa.
SPECT/TC y PET/TC

PET-TC EN ENDOCARDITIS PROTÉSICA

Selección de la serie de TC

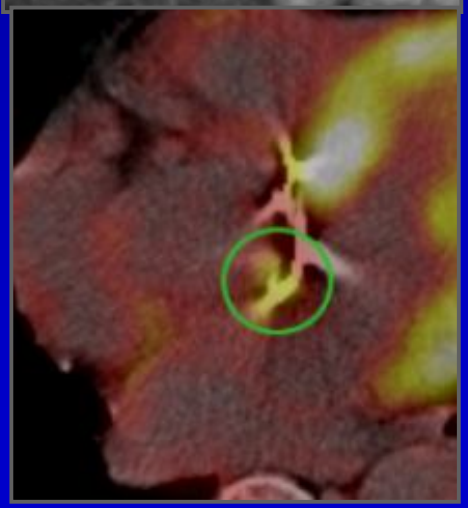

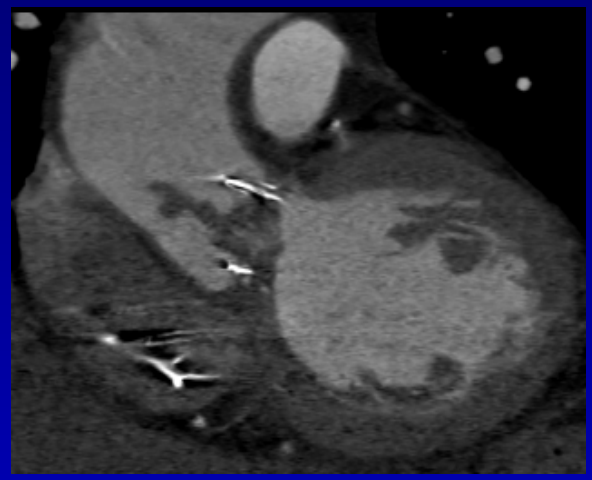

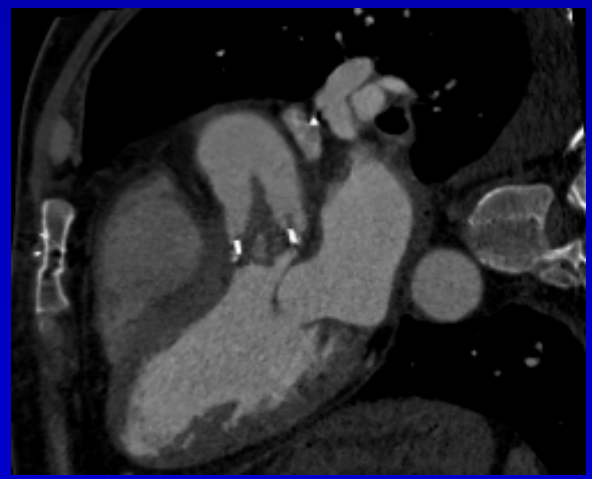

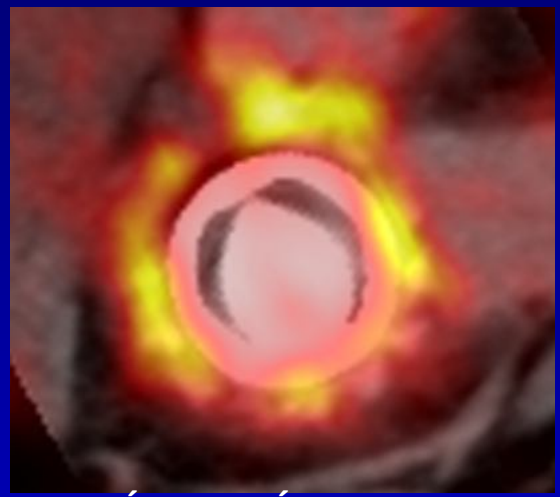

VÁLVULA AÓRTICA CERRADA

VÁLVULA AÓRTICA ABIERTA

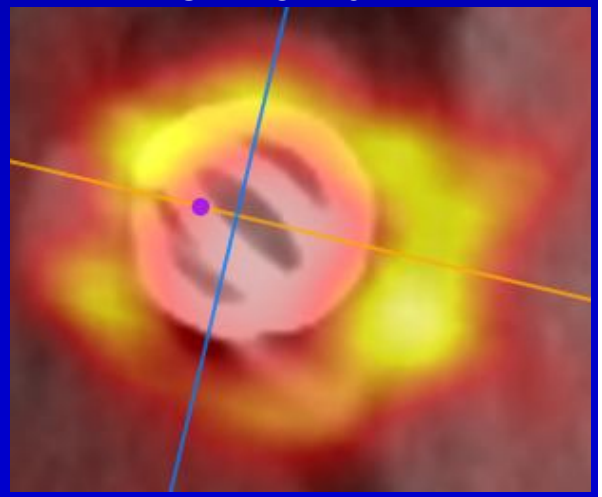

- VEGETACIÓN VALVULAR AÓRTICA.
- FIJACIÓN FOCAL DE FDG A NIVEL VALVULAR.

PET-TC EN ENDOCARDITIS PROTÉSICA

COMPLICACIÓN POSTQUIRÚRGICA NO INFECCIOSA

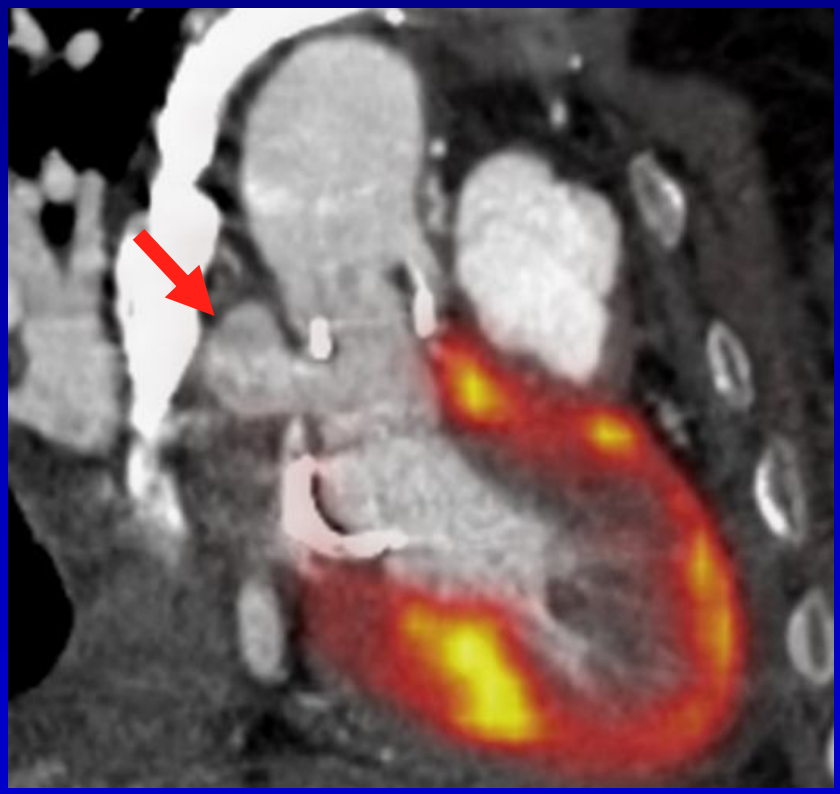

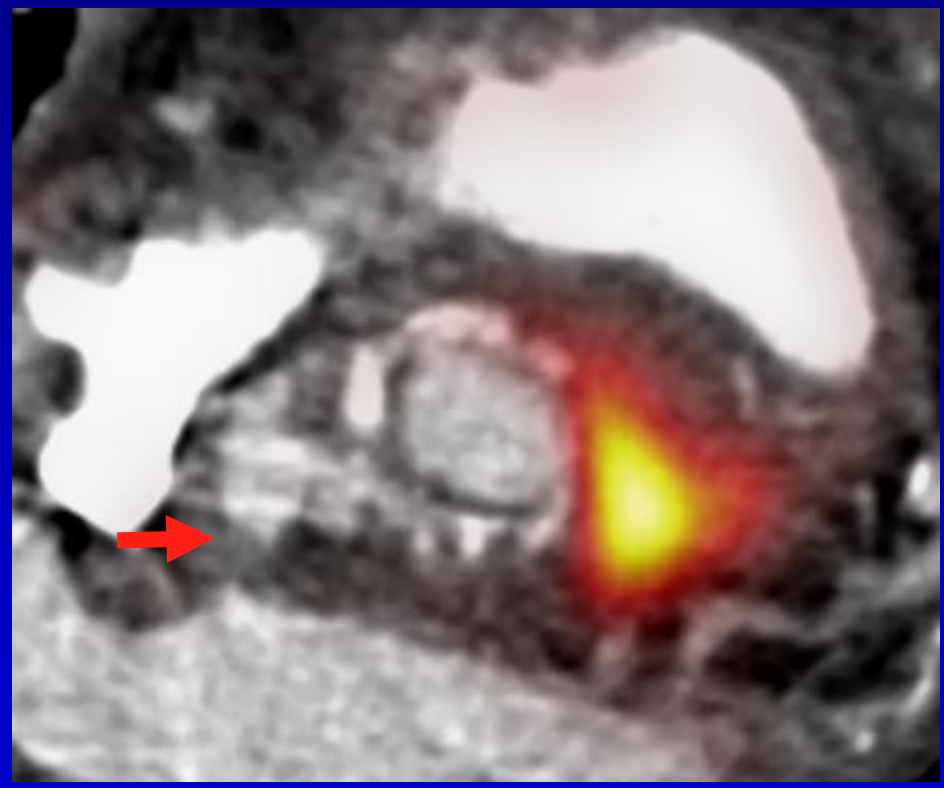

PET-TC EN ENDOCARDITIS PROTÉSICA

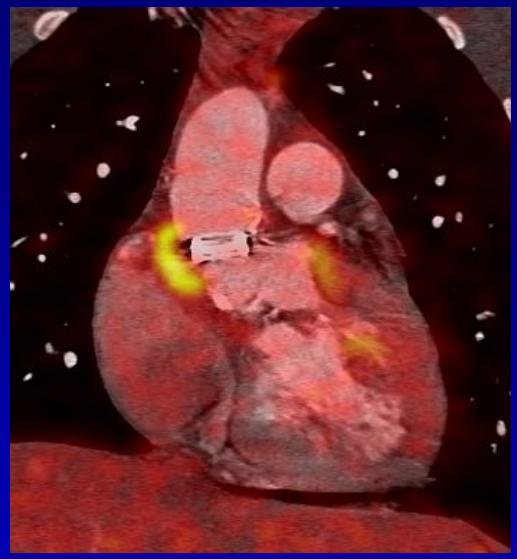

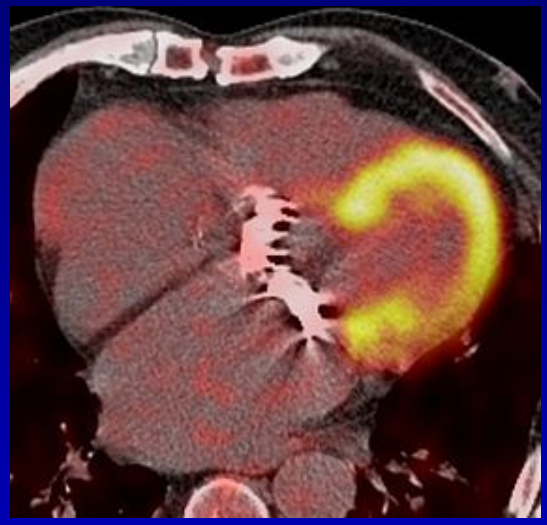

- ✓ **Permite confirmar-excluir el diagnostico en casos de ECO dudoso o negativo (El POSIBLE).**
- ✓ **INCREMENTO DE LA SENSIBILIDAD DIAGNÓSTICA.**
- ✓ **DIAGNÓSTIO PRECOZ > tratamiento precoz + menor daño valvular > mejoría pronostica.**

PET/TC:

- PET/TC EN LAS ENDOCARDITIS PROTÉSICAS Y DE DISPOSITIVOS
  - METODOLOGÍA
  - DISPOSITIVOS
  - ENDOCARDITIS NATIVA
  - ENDOCARDITIS PROTÉSICA
  - DOBLES DISPOSITIVOS

PET-TC EN DOBLES DISPOSITIVOS

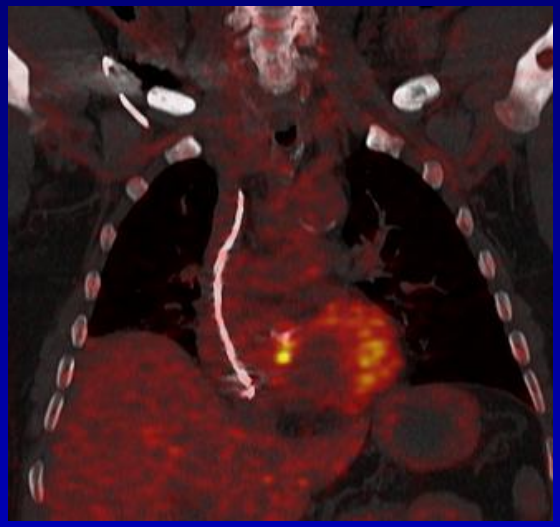

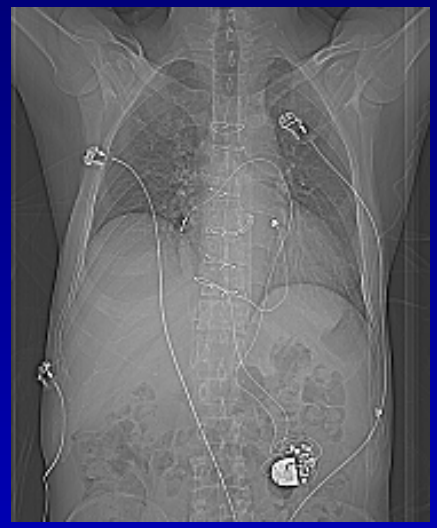

- ✓ PUEDE SER DIFÍCIL DETERMINAR SI SÓLO EXISTE AFECTACIÓN VALVULAR, O DEL DISPOSITIVO, O DE AMBOS.
- ✓ NO ESTÁ ESTABLECIDO SI UN DISPOSITIVO DEBE RETIRARSE EN UN PACIENTE CON ENDOCARDITIS VALVULAR.
- ✓ PET/TC PODRÍA DEFINIR SU COMPROMISO Y LA NECESIDAD DE EXTRACCIÓN O RECAMBIO SELECTIVO.

PET-TC EN DOBLES DISPOSITIVOS

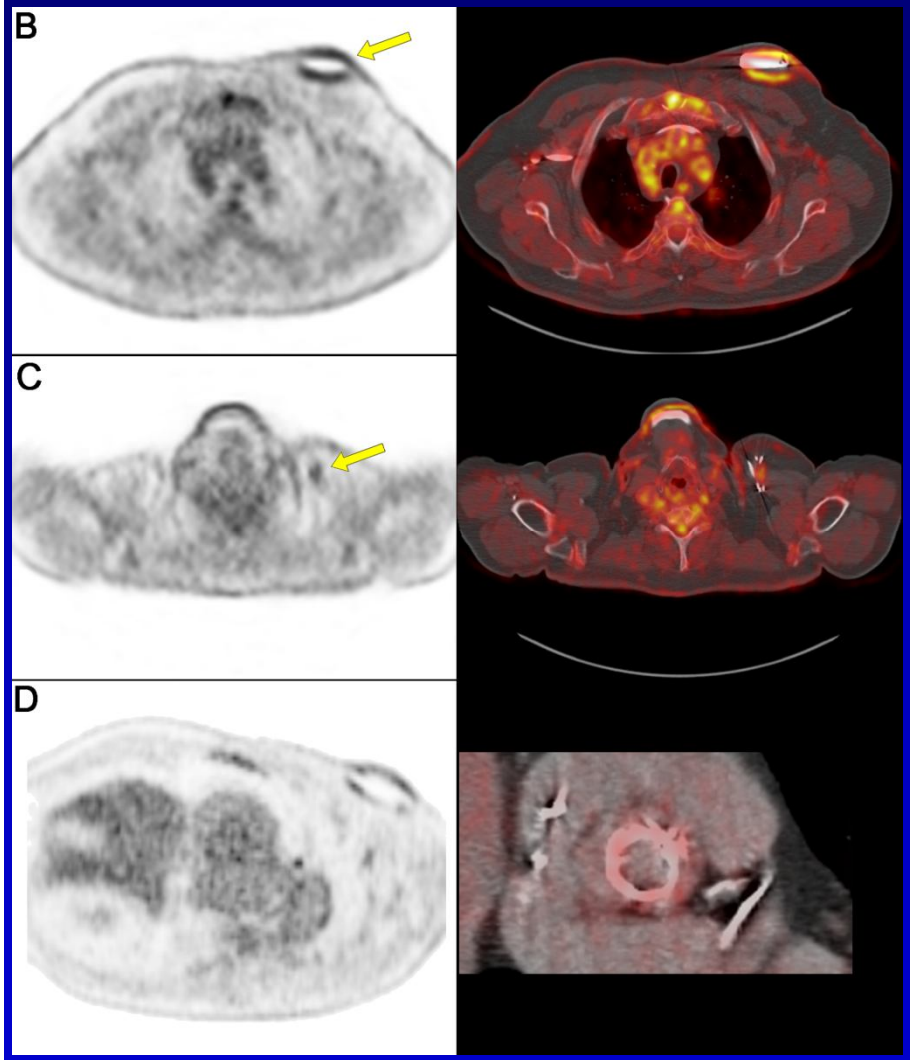

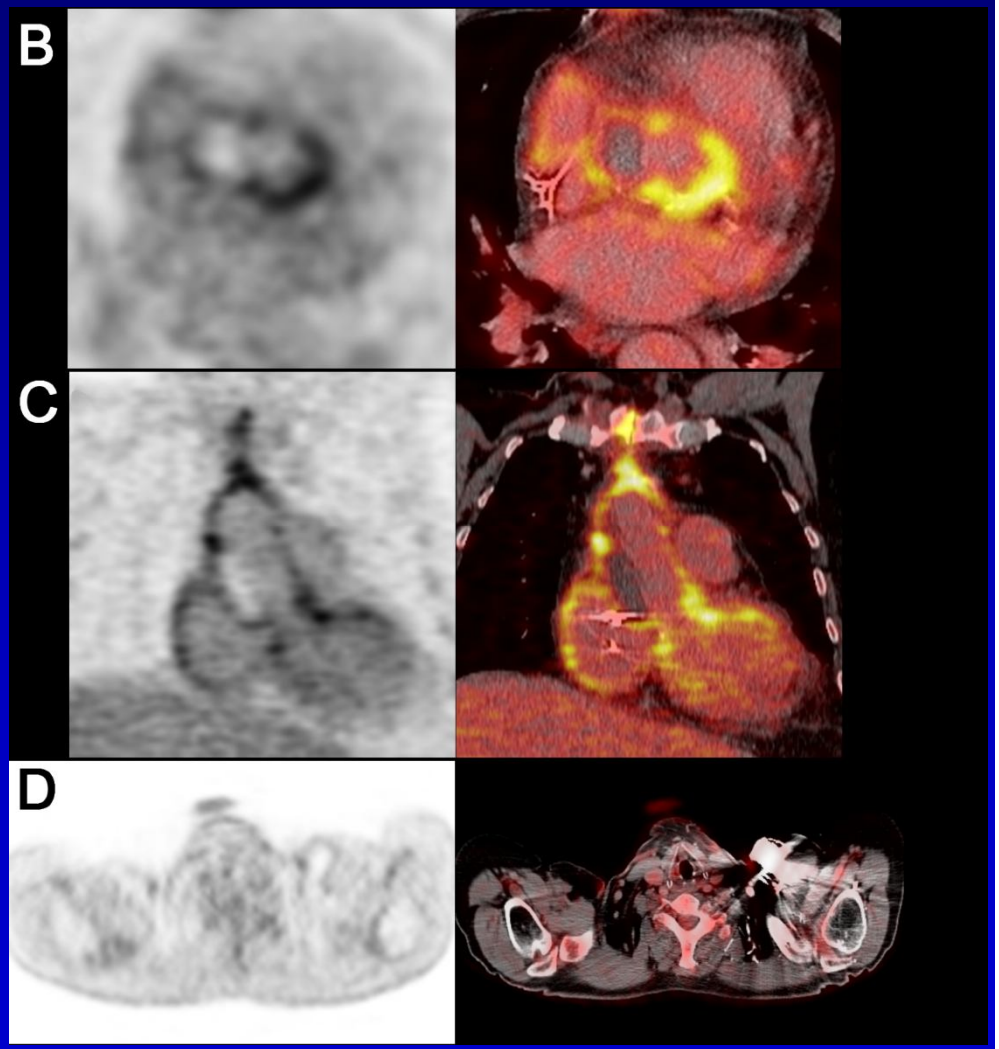

PET/TC:

- PET/TC EN LAS ENDOCARDITIS PROTÉSICAS Y DE DISPOSITIVOS
  - METODOLOGÍA
  - DISPOSITIVOS
  - ENDOCARDITIS NATIVA
  - ENDOCARDITIS PROTÉSICA
  - DOBLES DISPOSITIVOS
  - OTROS USOS

ENDOCARDITIS EN CARDIOPATIAS CONGÉNITAS

- ✓ Mucho más frecuente que en la población general.
- ✓ Material protésico.
- ✓ DIAGNÓSTICO ES UN DESAFÍO: Estructuras difíciles de evaluar mediante ecocardiografía.

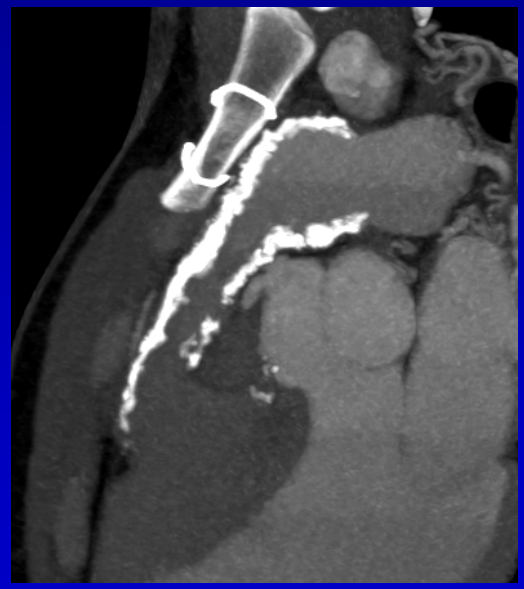

- ✓ ETE no ha demostrado ser superior al TTE. Una ECO negativa no excluye la EI.

ENDOCARDITIS EN CARDIOPATIAS CONGÉNITAS

Varón de 35 años.

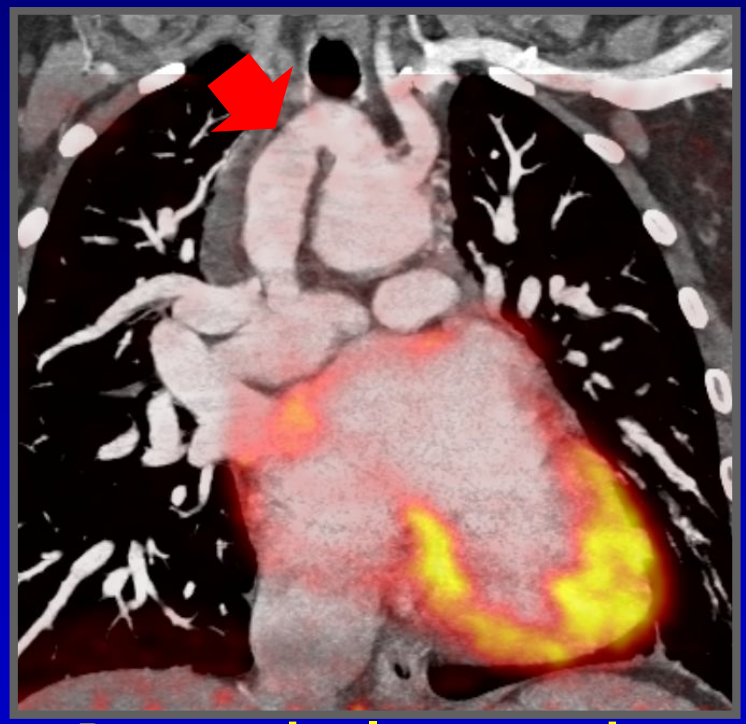

Descartado el compromiso del Blalog Taussig

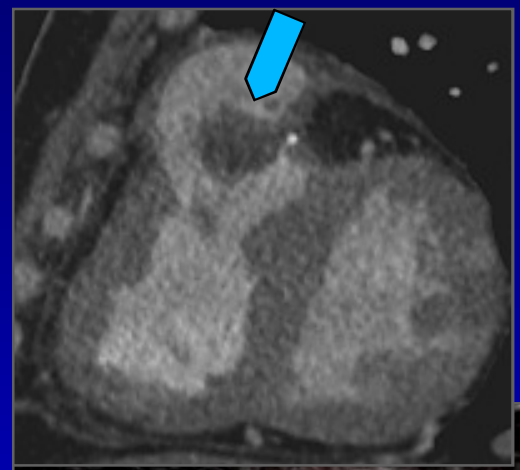

Mujer de 37 años

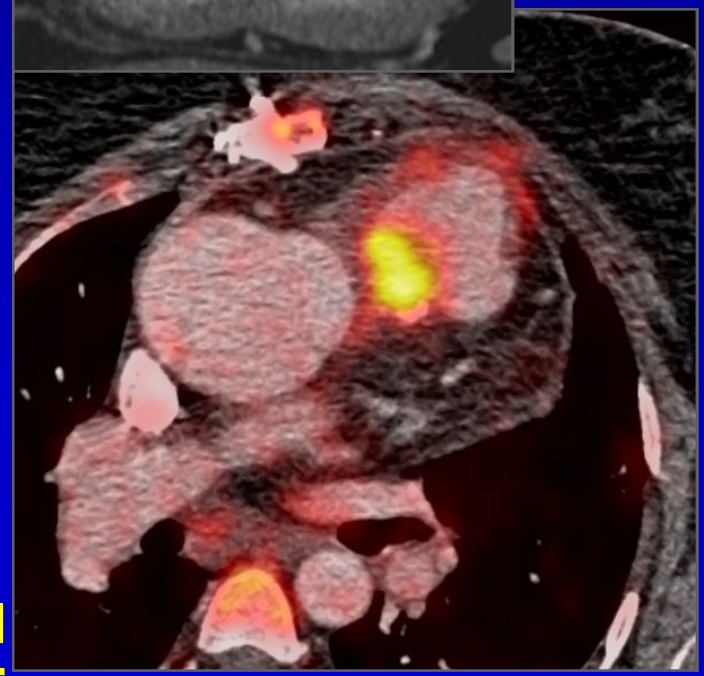

Vegetación hipermetabólica en el tracto de salida de la pulmonar

Nuevas técnicas de imagen en Endocarditis Infecciosa. SPECT/TC y PET/TC

EVALUACIÓN DE LA RESPUESTA AL TRATAMIENTO ATB

Hombre de 61 años. Sindrome de Marfan. . 3 cirugías aórticas. E**ndocarditis recidivante (2m)** por *Staphylococcus CN.*

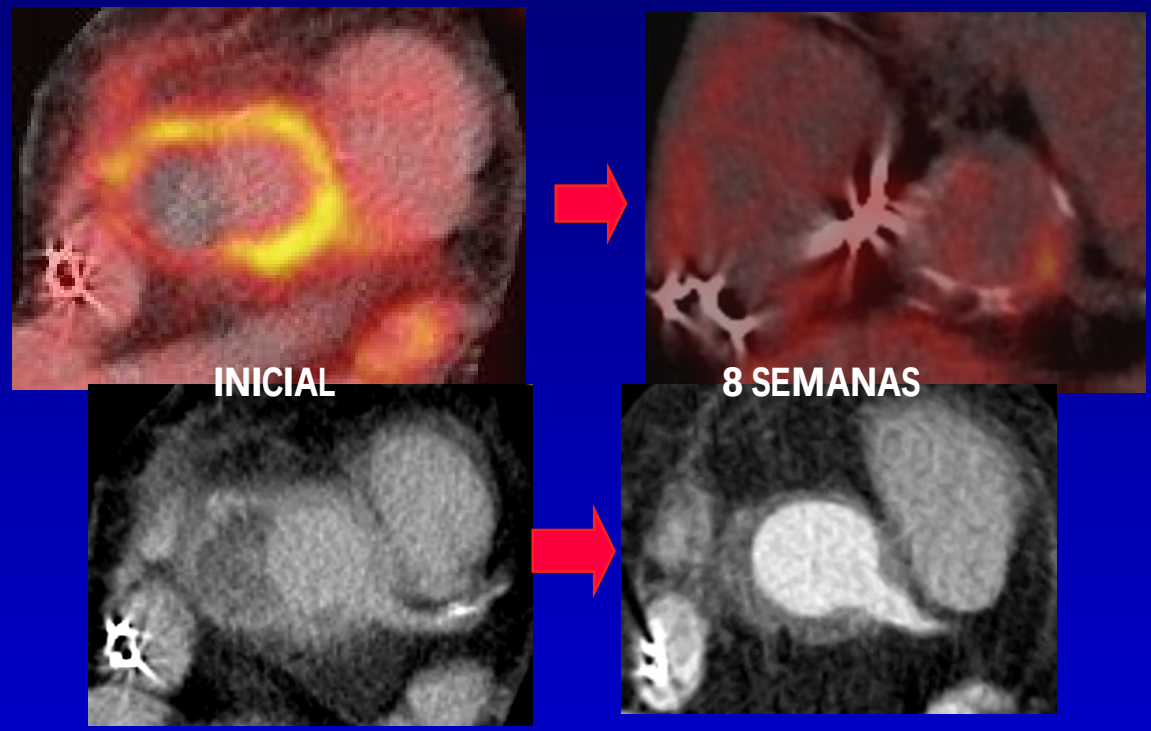

- Reabsorción de la colección
- Disminución de la actividad metabólica (SUV máx 9 > 5.9)

✓ **En pacientes con infección extensa INOPERABLES POR ALTO RIESGO QUIRÚRGICO.**

✓ **La PET-TC podría determinar, conjuntamente con la respuesta clínica y bacteriológica, la eficacia del tratamiento antibiótico.**

EMBOLISMOS PERIFÉRICOS

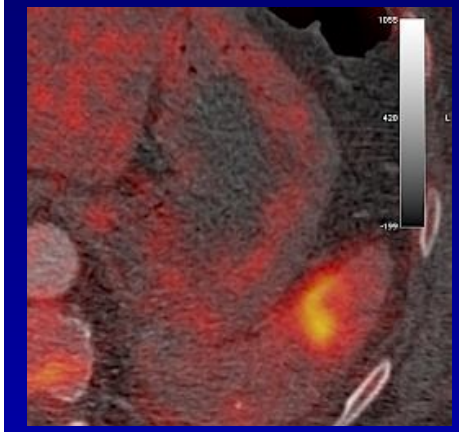

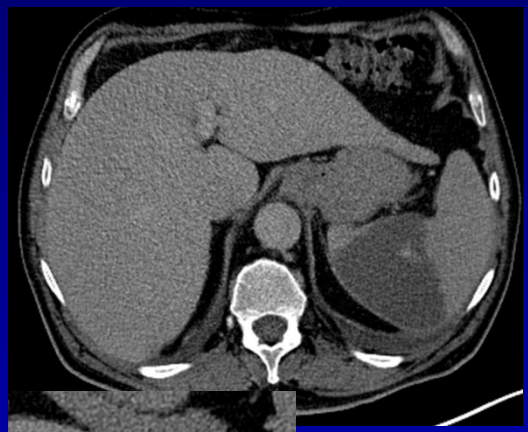

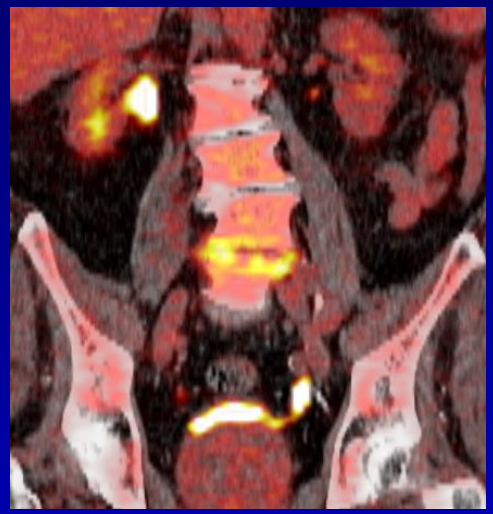

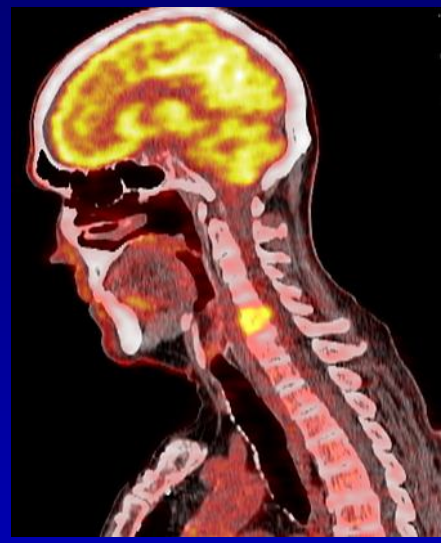

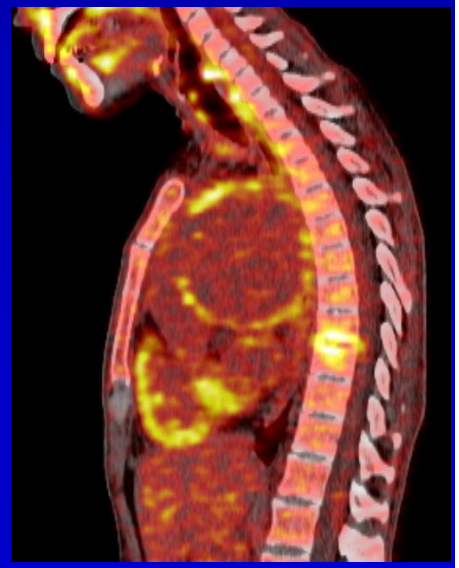

- ✓ Son relativamente frecuentes.
- ✓ Podrían ser responsables de bacteriemia persistente y reinfección de una nueva prótesis.
- ✓ NO definida la necesidad de screening sistemático.
- ✓ PET puede detectar embolias periféricas en todo el cuerpo, con dificultad a nivel cerebral.

INCIDENTALOMAS

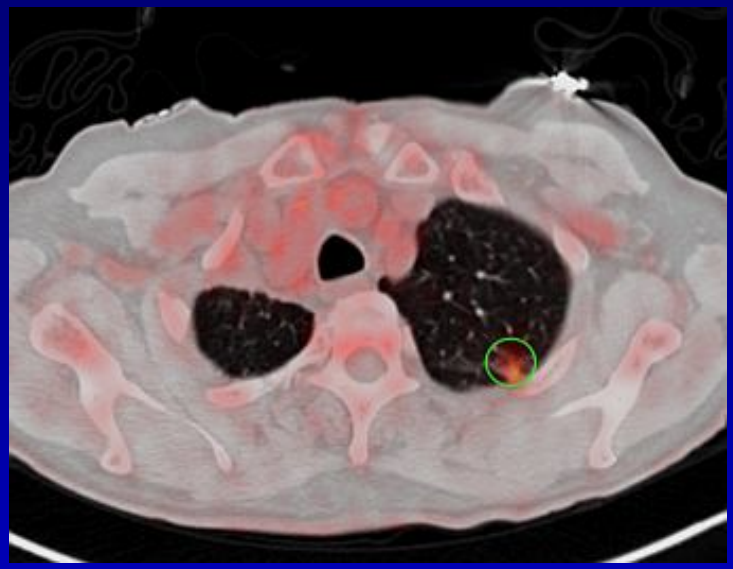

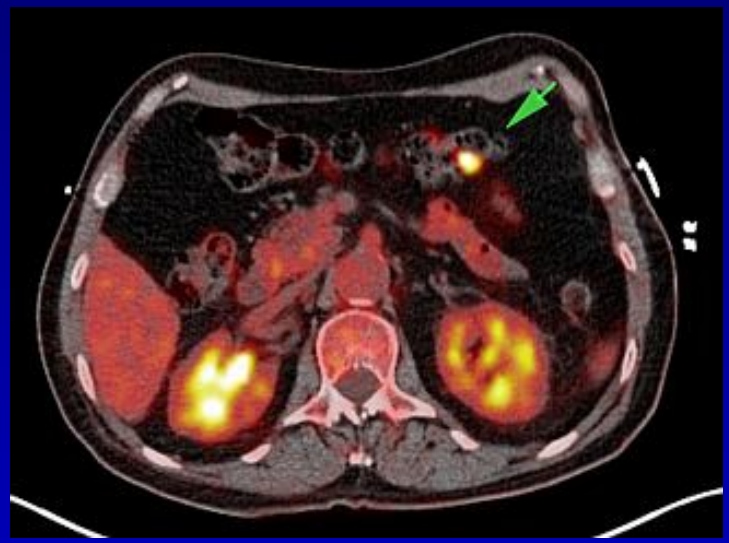

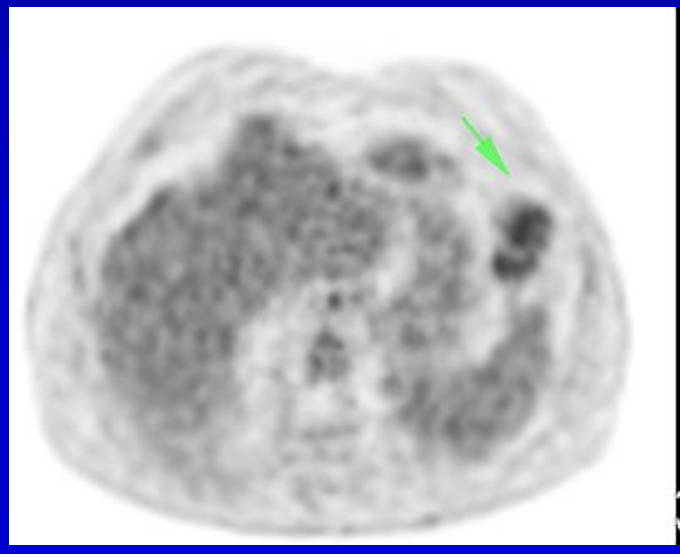

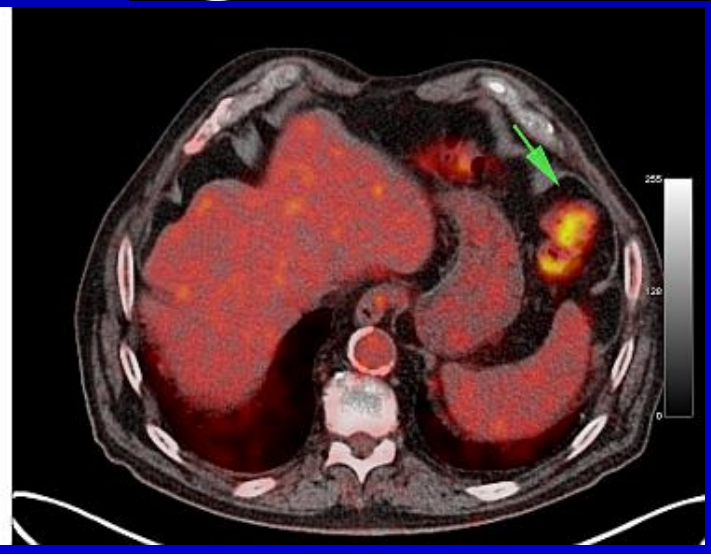

PET/TC:

- PET/TC EN LAS ENDOCARDITIS PROTÉSICAS Y DE DISPOSITIVOS
  - METODOLOGÍA
  - DISPOSITIVOS
  - ENDOCARDITIS NATIVA
  - ENDOCARDITIS PROTÉSICA
  - DOBLES DISPOSITIVOS
  - OTROS USOS

CONCLUSIONES:

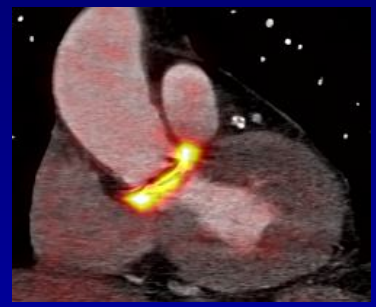

- ✓ La PET-AngioTC demuestra un valor diagnóstico incremental a los criterios clásicos de EI protésica valvular y de dispositivos, al presentar conjuntamente información relevante sobre el metabolismo local y la anatomía.

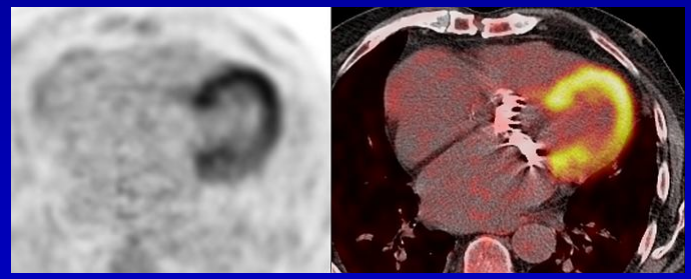

- ✓ Valora la afectación local y la extensión locoregional.
- ✓ Además, muestra alternativas diagnósticas, detecta embolismos periféricos y lesiones neoplásicas no sospechadas.

Nuevas técnicas de imagen en Endocarditis Infecciosa. SPECT/TC y PET/TC

CONCLUSIONES:

Positron Emission Tomography/Computed Tomography for Diagnosis of Prosthetic Valve Endocarditis

Increased Valvular ^{18}F-Fluorodeoxyglucose Uptake as a Novel Major Criterion

Ludivine Saby, MD,* Olivia Laas, MD,† Gilbert Habib, MD,* Serge Cammilleri, MD, PHD,† Julien Mancini, MD, PHD,‡ Laetitia Tessonnier, MD,† Jean-Paul Casalta, MD,§ Frederique Gouriet, MD, PHD,§ Alberto Riberi, MD,|| Jean-Francois Avierinos, MD,* Frederic Collart, MD,|| Olivier Mundler, MD, PHD,† Didier Raoult, MD, PHD,§ Franck Thuny, MD, PHD*§¶

(J Am Coll Cardiol 2013;61:2374–82)

Methods: We prospectively studied 72 consecutive patients suspected of having PVE. All of the patients were subjected to clinical, microbiological, and echocardiographic evaluation. Cardiac PET/CT was performed at admission. The final diagnosis was defined according to the clinical and/or pathological modified Duke criteria determined during a 3-month follow-up.

Major criteria

Blood culture positive for IE
- Typical microorganisms consistent with IE from 2 separate blood cultures:
  - Viridans streptococci, *Streptococcus bovis,* HACEK group, *Staphylococcus aureus;* or Community-acquired enterococci, in the absence of a primary focus; or
- Microorganisms consistent with IE from persistently positive blood cultures, defined as follows:
  - at least 2 positive cultures of blood samples drawn >12 h apart; or
  - all of 3 or a majority of ≥4 separate cultures of blood (with first and last sample drawn at least 1 h apart)
- Single positive blood culture for *Coxiella burnetii* or antiphase I IgG antibody titer >1:800

Evidence of endocardial involvement
- Echocardiogram (TTE and/or TEE) positive for IE defined as follows:
  - Oscillating intracardiac mass on valve or supporting structures, in the path of regurgitant jets, or on implanted material in the absence of an alternative anatomic explanation; or
  - Abscess; or
  - New partial dehiscence of prosthetic valve
- New valvular regurgitation (worsening or changing of pre-existing murmur not sufficient)

Positive ^{18}F-fluorodeoxyglucose (FDG) positron emission tomography/computed tomography: abnormal FDG uptake at the site of prosthetic valve

(61% Hombres)

(61% Bioprótesis / 39% Mecánicas)

PET 3D sin HR ni TOF

TC sin contraste

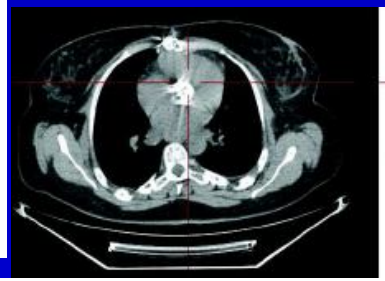



Nuevas técnicas de imagen en Endocarditis Infecciosa. SPECT/TC y PET/TC

CONCLUSIONES:

Positron Emission Tomography/Computed Tomography for Diagnosis of Prosthetic Valve Endocarditis

Increased Valvular ^{18}F-Fluorodeoxyglucose Uptake as a Novel Major Criterion

Ludivine Saby, (J Am Coll Cardiol 2013;61:2374–82)

Table 3. Results of PET/CT According to the Final Diagnosis

	Final Diagnosis		
	Definite PVE	*Possible* PVE	*Rejected* PVE
Positive PET/CT 36 (50%)	22 (73)	10 (45)	FP 15% 4 (20)
Negative PET/CT 36 (50%)	8 (27) FN 33%	12 (55)	16 (80)

Data are expressed as number (% of each final diagnosis)

FN: tratamiento ATB igual que los demás

- S 73%
- E 80%
- VPP 85%
- VPN 67%
- Accuracy 76%

FP: 2 tubos aórticos
1 trombosis protésica
1 cuerda rota mitral con ligera fijación de FDG

Nuevas técnicas de imagen en Endocarditis Infecciosa. SPECT/TC y PET/TC

CONCLUSIONES:

Resultados 2014 HUVH. Barcelona.

- ✓ La PET-AngioTC incrementa la sensibilidad de los criterios de Duke del 48% hasta el 88%, y permitió al equipo de expertos dar una clasificación definitiva d las EI en el 92% de los casos.

ESC CONGRESS BARCELONA 2014 www.escardio.org/esc2014

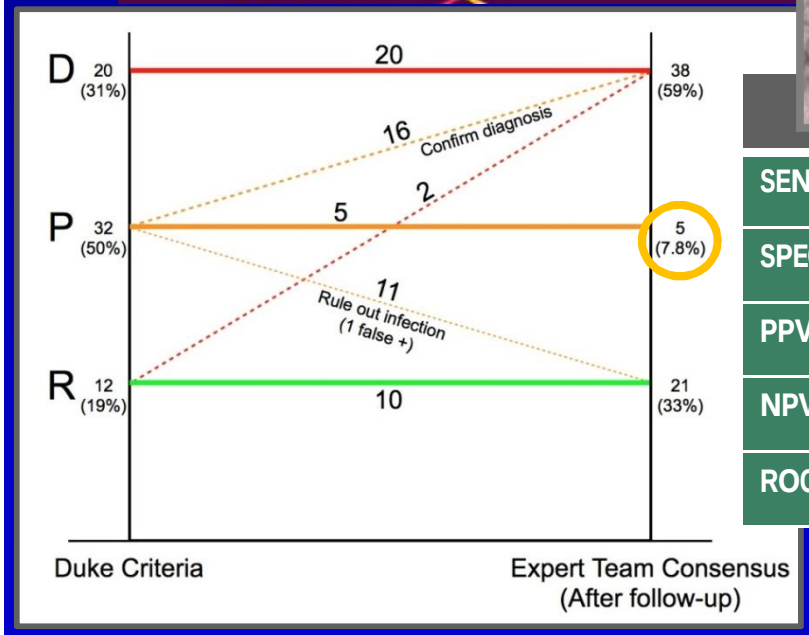

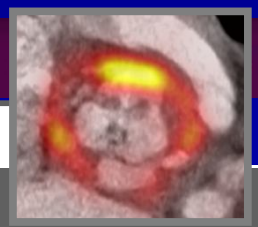

	DUKE MOD	PET/ANGIO-CT	DC + PET/CTA
SENSITIVITY (%, 95% CI)	**47.6** (32-63.6)	83.3 (68.6-93)	**88.1** (74.4-96)
SPECIFICITY (%, 95% CI)	100 (84.6-100)	86.4 (65.1-97.1)	86.4 (65.1-97.1)
PPV (%, 95% CI)	100 (70.2-99.1)	89.8 (75.3-96.2)	90.3 (76.4-96.4)
NPV (%, 95% CI)	57 (49.9-63.9)	78.3 (64.2-87.8)	83.4 (68.5-92.1)
ROC AREA (%, 95% CI)	0.738 (0.66-0.81)	0.849 (0.75-0.94)	0.87 (0.78-0.96)

Estudio prospectivo desde Nov 2012 a Jun 2014 (N: 64) en sospecha de **EI** sobre válvulas protésicas y dispositivos.

AGRADECIMIENTOS:

Hospital Universitari Vall d'Hebron. Comité de EI:

Servicio de Enfermedades Infecciosas:

N. Fernández-Hidalgo, B. Almirante

Servicio de Cardiología:

M.N. Pizzi, G. Oristrell, M.T. Gonzàlez-Alujas, P. Tornos.

Servicio de Radiología:

A. Roque, H. Cuéllar-Calabria

Servicio de Microbiología

Servicio de Neurología

Servicio de Medicina Nuclear

Institut per al Diagnòstic per la Imatge (IDI)