HA LLEGADO LA REVOLUCIÓN DEL ECOCARDIOGRAMA TRIDIMENSIONAL

Mar Moreno Yangüela,
Servicio de Cardiología
H U La Paz
Madrid.

Endocarditis y eco 3D

1ª ¿Qué aporta la ecografía 3D en el manejo de pacientes con endocarditis infecciosa?

- ☑ Imágenes bonitas

Eco 3D ¿Sólo son imágenes bonitas?

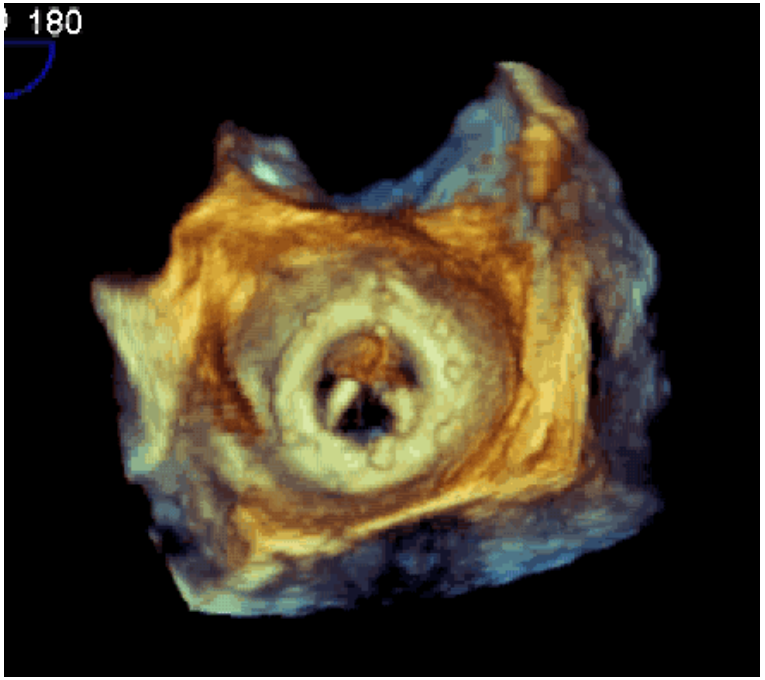

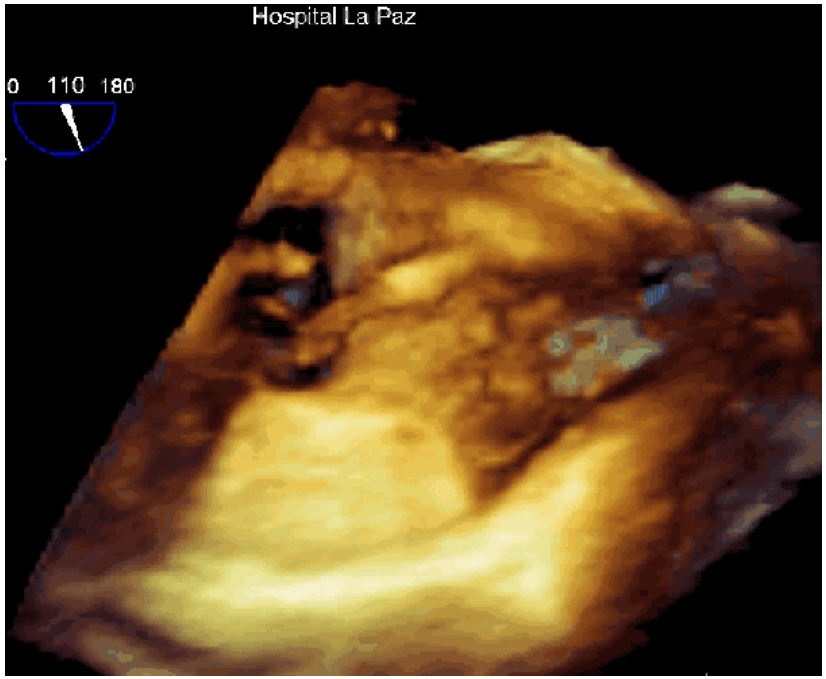

Endocarditis y eco 3D

1ª ¿Qué aporta la ecografía 3D en el manejo de pacientes con endocarditis infecciosa?

- ☑ ¿Imágenes bonitas?
- ❑ Información relevante desde el punto de vista clínico
  - ❑ En todos los casos
  - ❑ En pacientes complejos: prótesis, catéteres, dispositivos…

European Heart Journal (2015) **36**, 3075–3123
doi:10.1093/eurheartj/ehv319

ESC GUIDELINES

2015 ESC Guidelines for the management of infective endocarditis

The Task Force for the Management of Infective Endocarditis of the European Society of Cardiology (ESC)

Endorsed by: European Association for Cardio-Thoracic Surgery (EACTS), the European Association of Nuclear Medicine (EANM)

Characteristics of the 'Endocarditis Team'

When to refer a patient with IE to an 'Endocarditis Team' in a reference centre

1. Patients with complicated IE (i.e. endocarditis with HF, abscess, or embolic or neurological complication or CHD), should be referred early and managed in a reference centre with immediate surgical facilities.
2. Patients with non-complicated IE can be initially managed in a non-reference centre, but with regular communication with the reference centre, consultations with the multidisciplinary 'Endocarditis Team', and, when needed, with external visit to the reference centre.

Characteristics of the reference centre

1. Immediate access to diagnostic procedures should be possible, including TTE, TOE, multislice CT, MRI, and nuclear imaging.
2. Immediate access to cardiac surgery should be possible during the early stage of the disease, particularly in case of complicated IE (HF, abscess, large vegetation, neurological, and embolic complications).
3. Several specialists should be present on site (the 'Endocarditis Team'), including at least cardiac surgeons, cardiologists, anaesthesiologists, ID specialists, microbiologists and, when available, specialists in valve diseases, CHD, pacemaker extraction, echocardiography and other cardiac imaging techniques, neurologists, and facilities for neurosurgery and interventional neuroradiology .

Role of the 'Endocarditis Team'

1. The 'Endocarditis Team' should have meetings on a regular basis in order to discuss cases, take surgical decisions, and define the type of follow-up.
2. The 'Endocarditis Team' chooses the type, duration, and mode of follow up of antibiotic therapy, according to a standardized protocol, following the current guidelines.
3. The 'Endocarditis Team' should participate in national or international registries, publicly report the mortality and morbidity of their centre, and be involved in a quality improvement programme, as well as in a patient education programme.
4. The follow-up should be organized on an outpatient visit basis at a frequency depending on the patient's clinical status (ideally at 1, 3, 6, and 12 months after hospital discharge, since the majority of events occur during this period[57]).

European Heart Journal (2015) 36, 3075–3123

Definition of infective endocarditis according to the modified Duke criteria

Definite IE
Pathological criteria • Microorganisms demonstrated by culture or on histological examination of a vegetation, a vegetation that has embolized, or an intracardiac abscess specimen; or • Pathological lesions; vegetation or intracardiac abscess confirmed by histological examination showing active endocarditis **Clinical criteria** • 2 major criteria; or • 1 major criterion and 3 minor criteria; or • 5 minor criteria
Possible IE
• 1 major criterion and 1 minor criterion; or • 3 minor criteria
Rejected IE
• Firm alternate diagnosis; or • Resolution of symptoms suggesting IE with antibiotic therapy for ≤4 days; or • No pathological evidence of IE at surgery or autopsy, with antibiotic therapy for ≤4 days; or • Does not meet criteria for possible IE, as above

European Heart Journal (2015) 36, 3075–3123

Diagnóstico de EI: Criterios mayores

Hemocultivos positivos

Evidencia de afectación endocárdica

- Diagnóstico EI
- Pronóstico EI
- Implicaciones terapeúticas

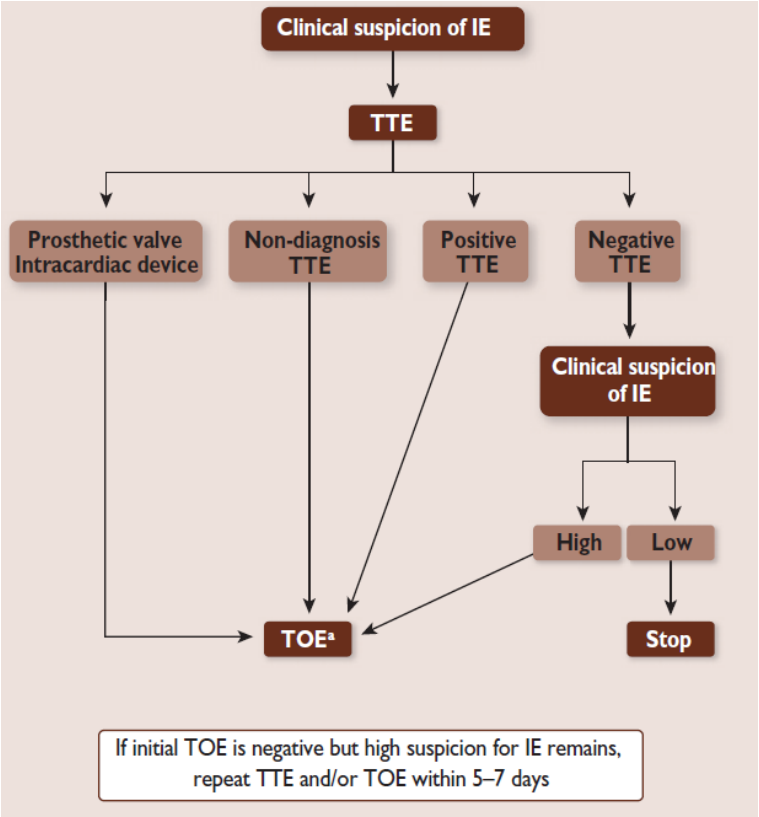

European Heart Journal (2015) 36, 3075–3123

Diagnóstico de EI

- Paciente de 85 años
- EPOC ; I Renal
- EAO severa + ICC
- EuroScore 25
- Implante de TAVI (3d)
- Avisan por disnea.

Semiología de IC

Técnicas de **imagen cardiaca** en el diagnóstico de endocarditis

Diagnóstico de EI

± 5h después
¿Sin síntomas nuevos?

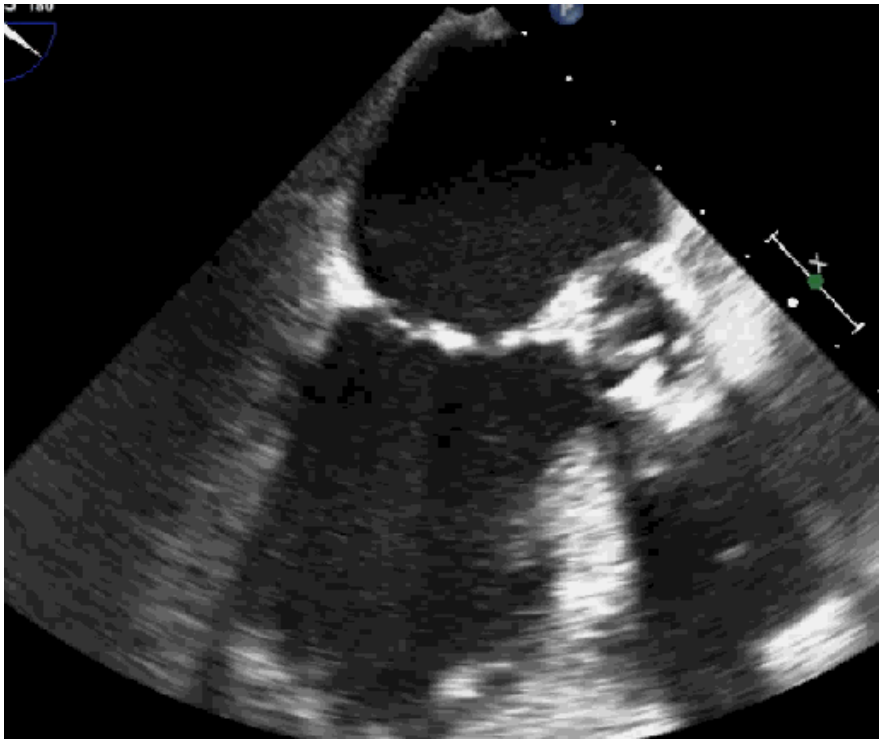

TAC craneal y toraco-abdominal negativos

Limitaciones de la ecocardiografía

Sensibilidad≠ 100% **Especificidad ≠ 100%**

- Vegetación: <2mm o atípica. Estudio muy precoz
- **Abscesos** - complicaciones perivalvulares
- **Material protésico. Valvulopatía previa**
- DD: trombo, prolapso mitral, rotura cuerdas, infiltración difusa valvular, excrecencias de Lamb, vegetaciones no infecciosas, fibroelastoma

European Heart Journal (2015) 36, 3075–3123

Técnicas de **imagen cardiaca** en el diagnóstico de endocarditis

¿↑ S y E?

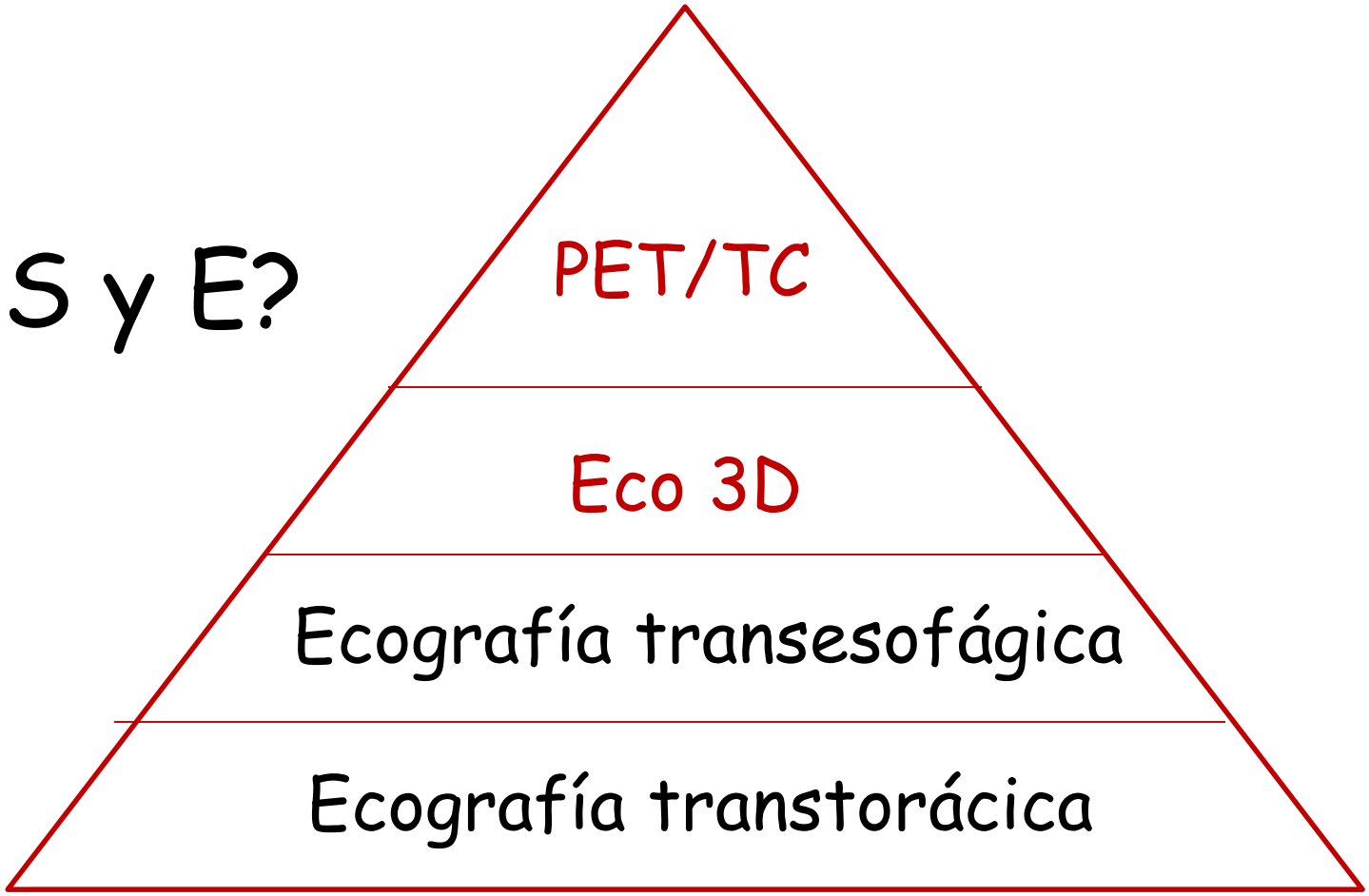

¿De qué técnica me fío?

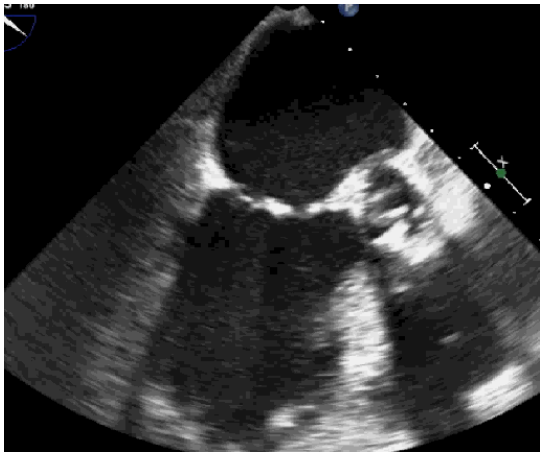

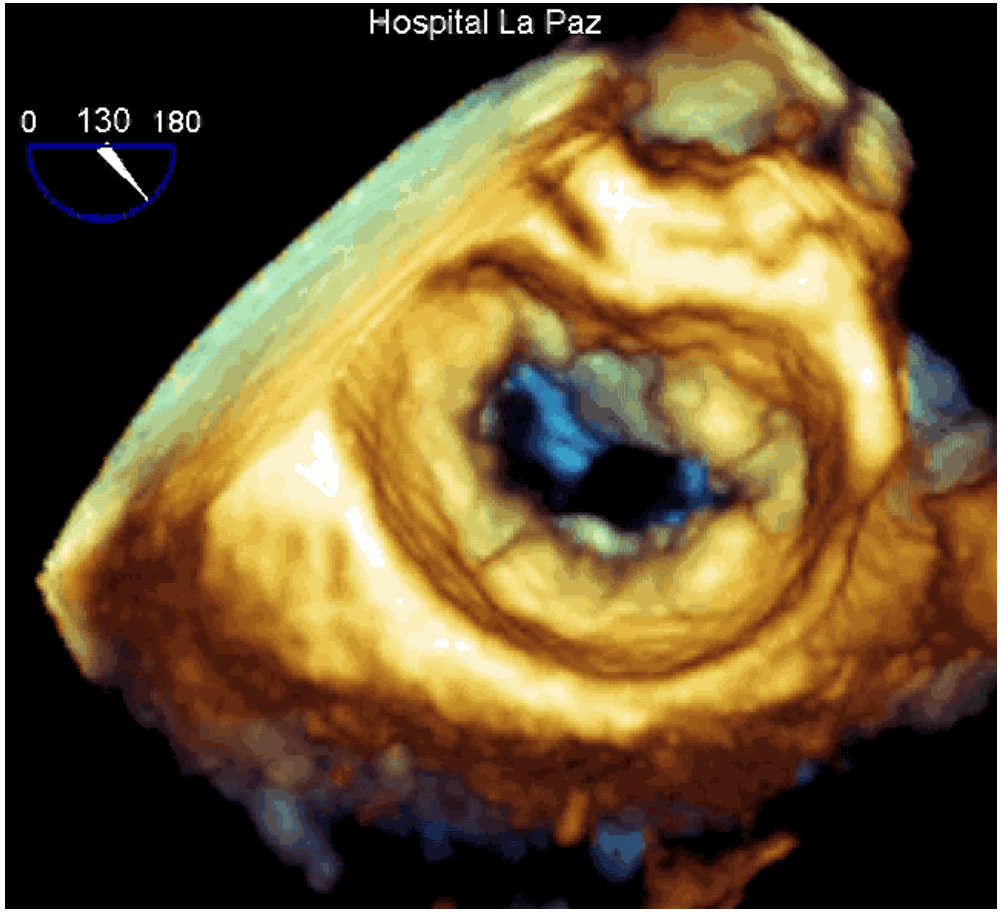

Endocarditis y eco 3D

¿Qué tengo que buscar?

	Surgery/necropsy	Echocardiography
Vegetation	Infected mass attached to an endocardial structure or on implanted intracardiac material.	Oscillating or non-oscillating intracardiac mass on valve or other endocardial structures, or on implanted intracardiac material.
Abscess	Perivalvular cavity with necrosis and purulent material not communicating with the cardiovascular lumen.	Thickened, non-homogeneous perivalvular area with echodense or echolucent appearance.
Pseudoaneurysm	Perivalvular cavity communicating with the cardiovascular lumen.	Pulsatile perivalvular echo-free space, with colour-Doppler flow detected.
Perforation	Interruption of endocardial tissue continuity.	Interruption of endocardial tissue continuity traversed by colour-Doppler flow.
Fistula	Communication between two neighbouring cavities through a perforation.	Colour-Doppler communication between two neighbouring cavities through a perforation.
Valve aneurysm	Saccular outpouching of valvular tissue.	Saccular bulging of valvular tissue.
Dehiscence of a prosthetic valve	Dehiscence of the prosthesis.	Paravalvular regurgitation identified by TTE/TOE, with or without rocking motion of the prosthesis.

European Heart Journal (2015) 36, 3075–3123

¿Qué tengo que buscar?

Vegetación: masa intracardiaca oscilante o no, adherida a una válvula, a otra estructura endocárdica, o a material protésico

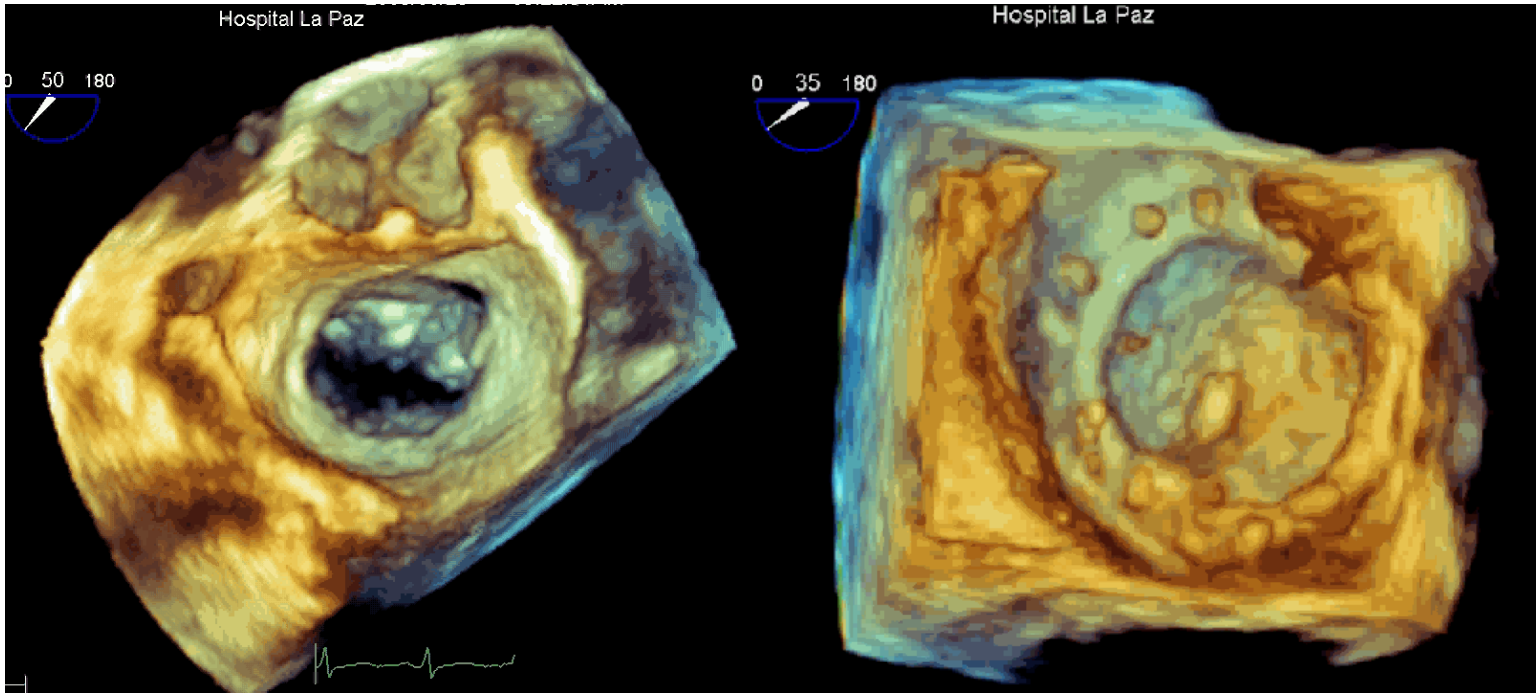

Eco 3D en EI mitral

Mejora la sensibilidad de la técnica

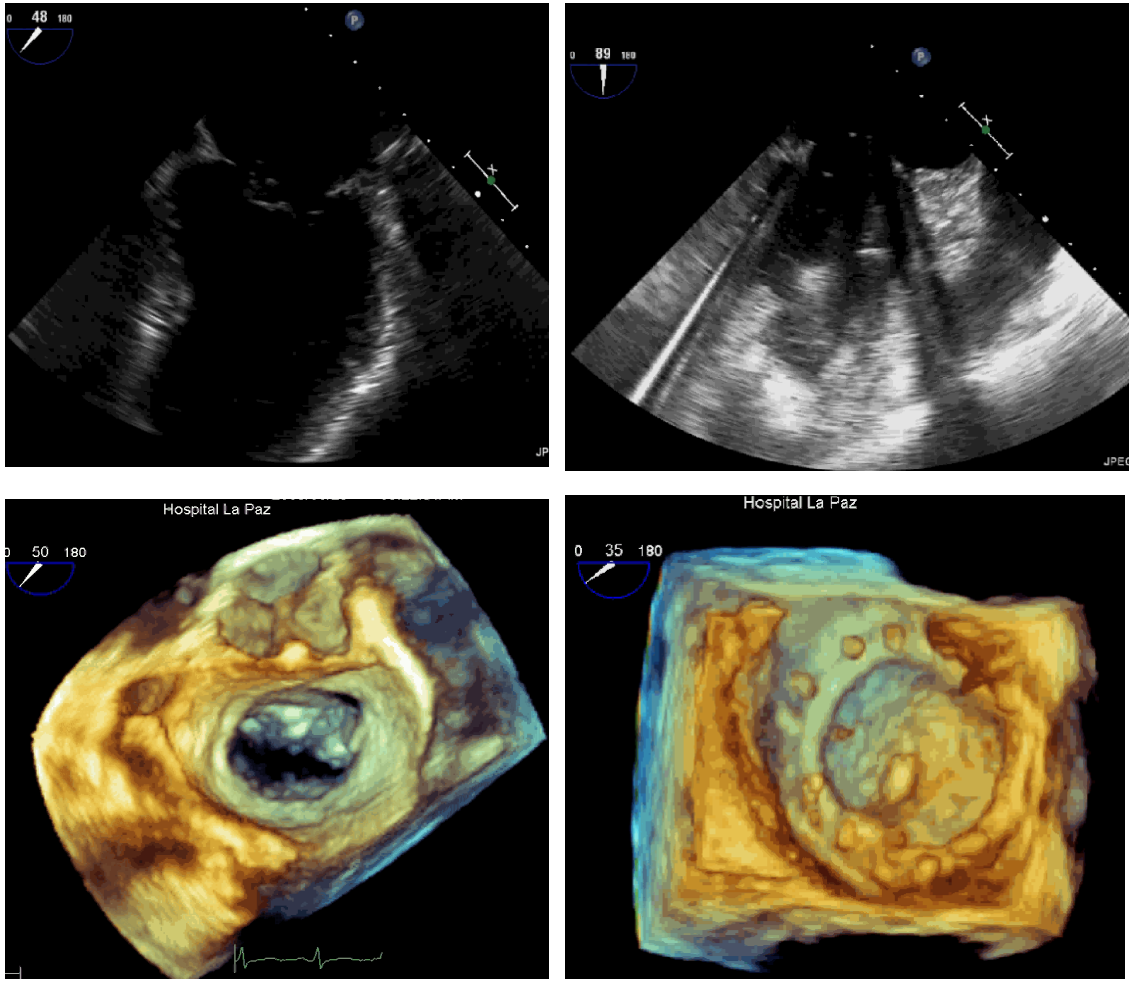

¿Qué tengo que buscar?

Aneurisma : cavidad sacular sobre el tejido endocárdico

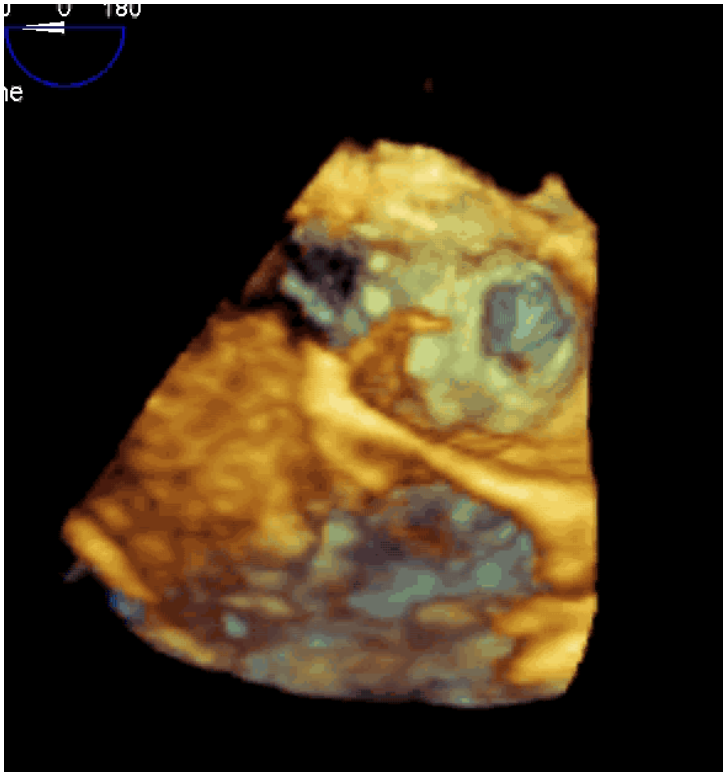

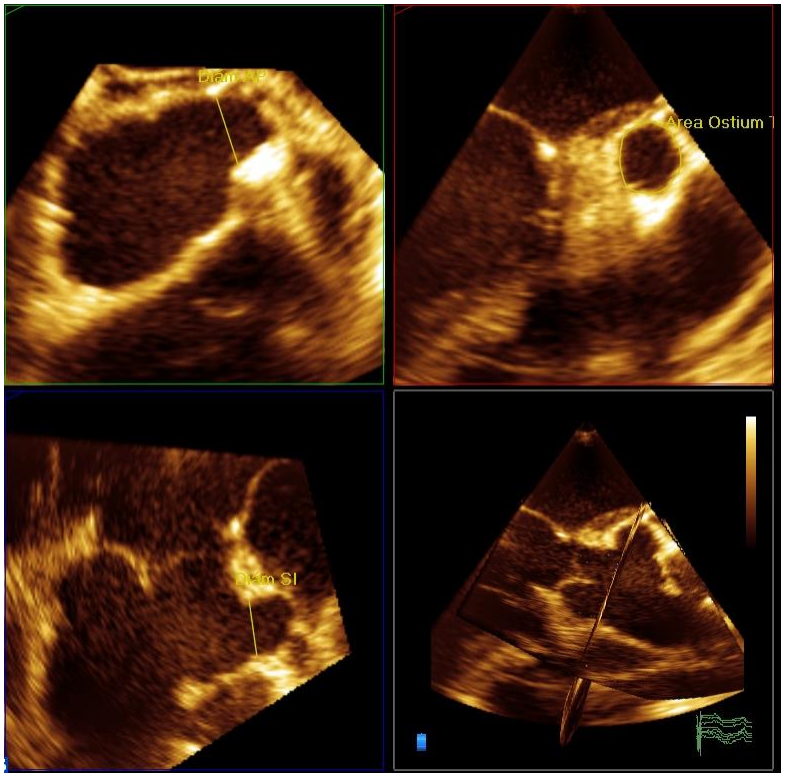

¿Qué tengo que buscar?

Absceso: engrosamiento perivalvular no homogéneo con áreas ecodensas y ecolucentes (DD cambios post Qx)

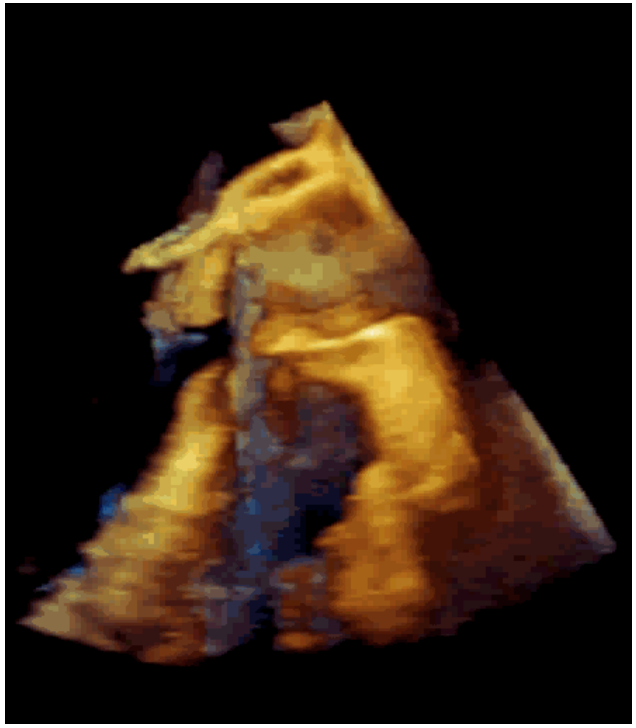

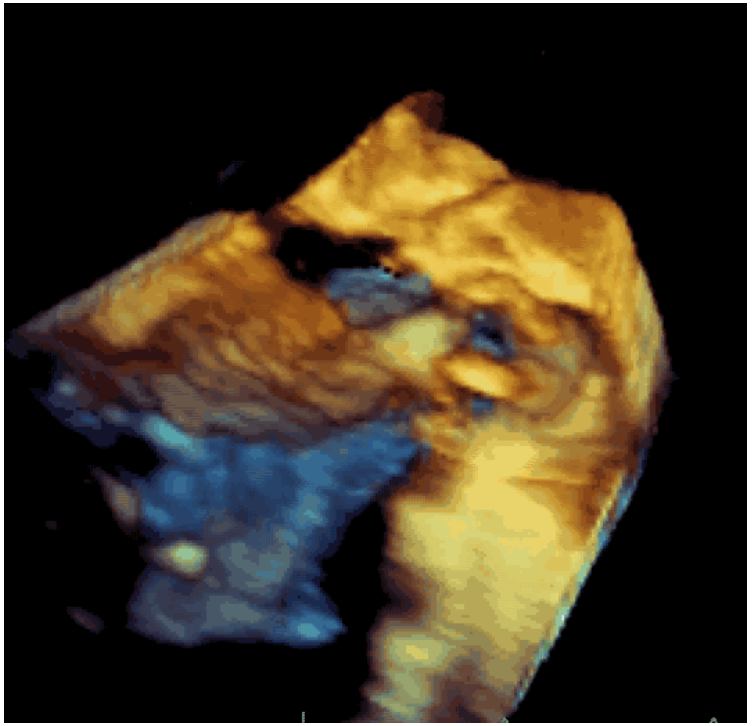

¿Qué tengo que buscar?

Pseudoaneurisma: cavidad perivalvular libre de ecos, con flujo en su interior

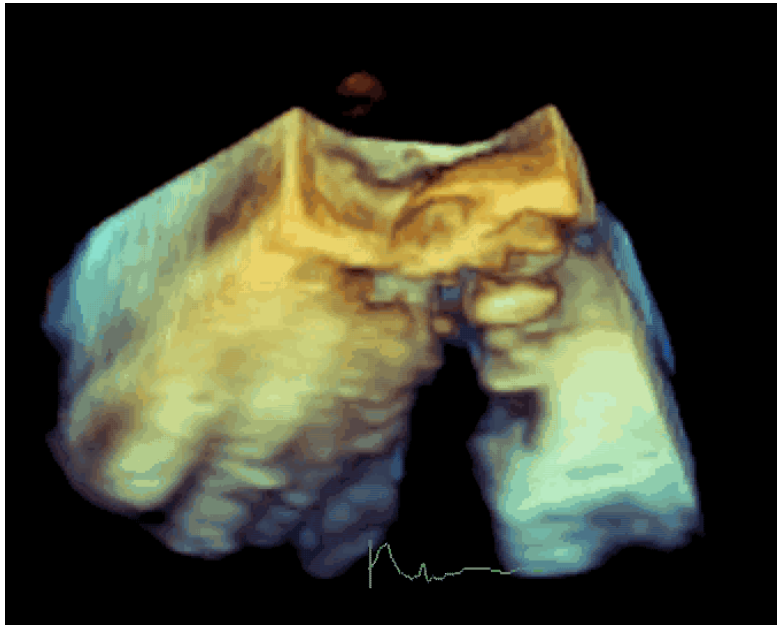

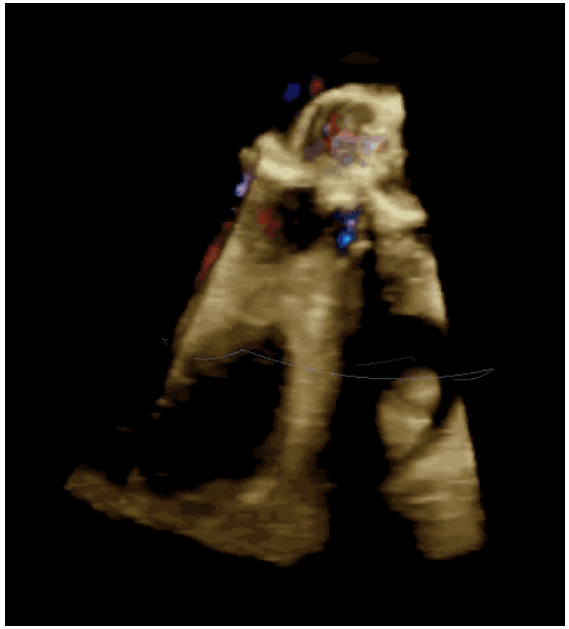

¿Qué tengo que buscar?

Fístula: comunicación entre dos cavidades vecinas.

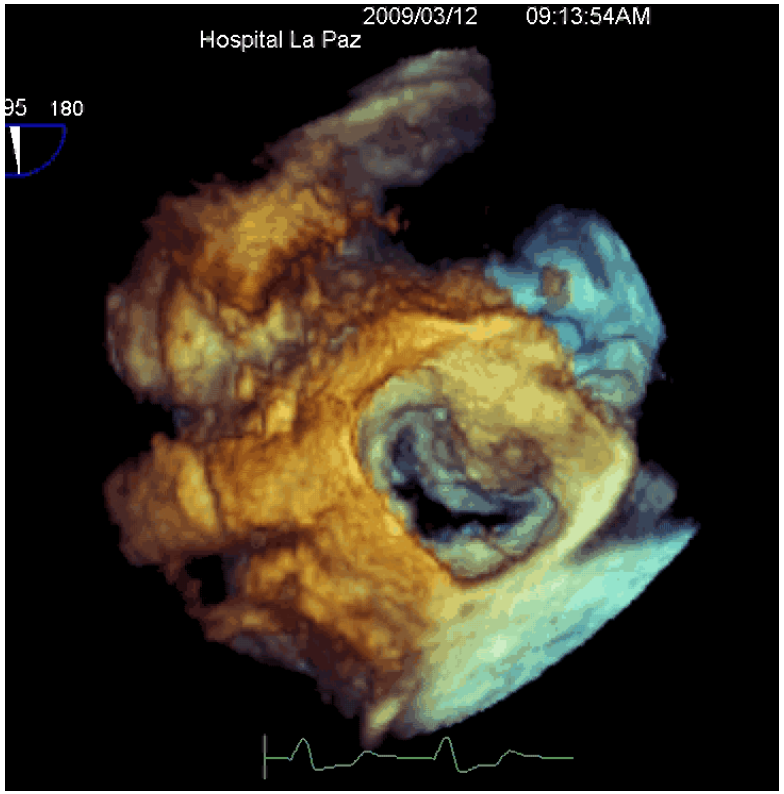

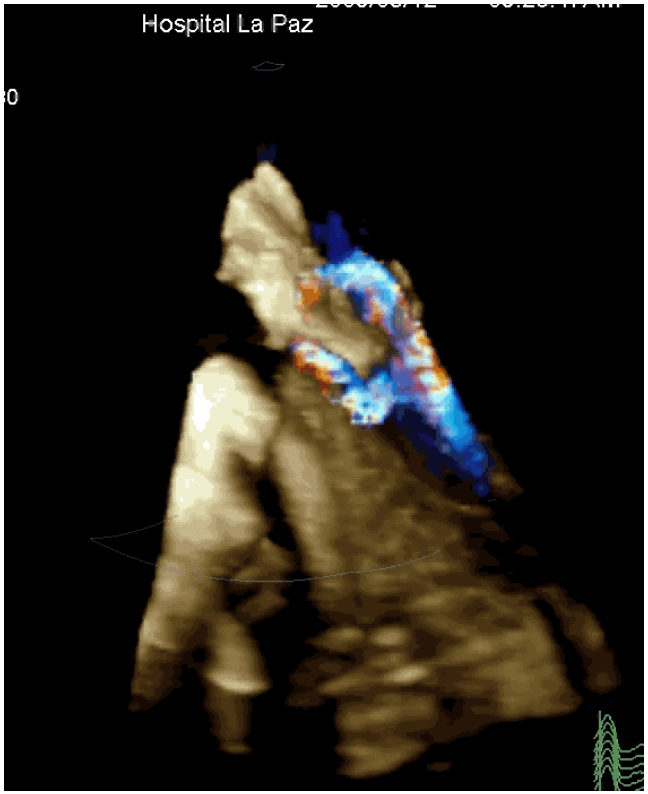

¿Qué tengo que buscar?

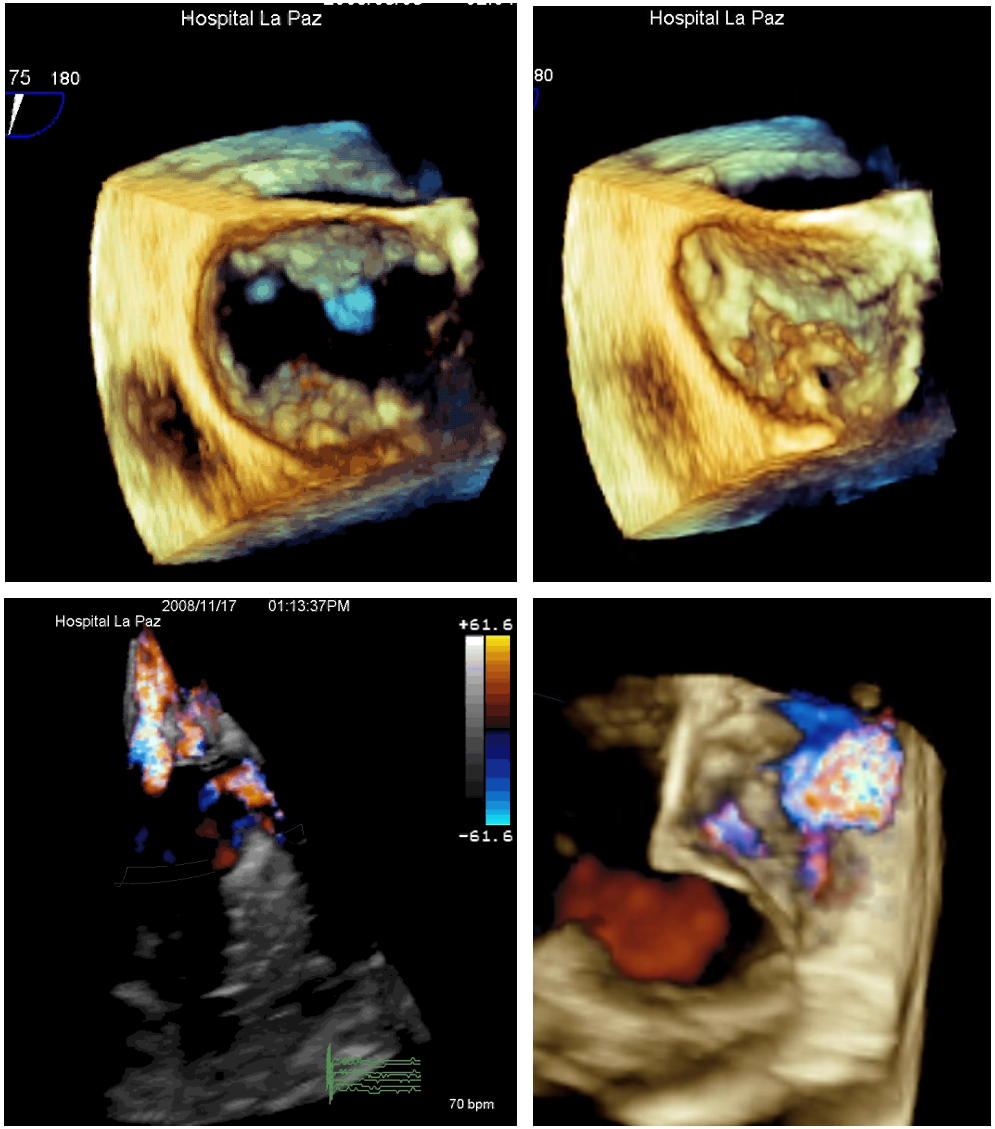

Perforación

Interrupción del tejido endocárdico atravesada por flujo, demostrado con doppler color.

¿Qué tengo que buscar?

Dehiscencia periprotésica

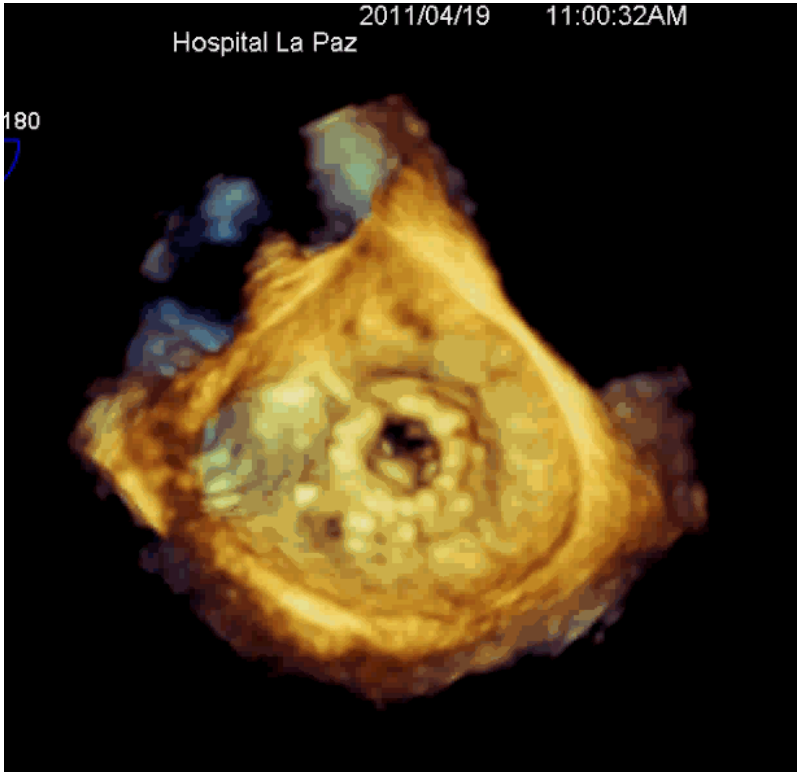

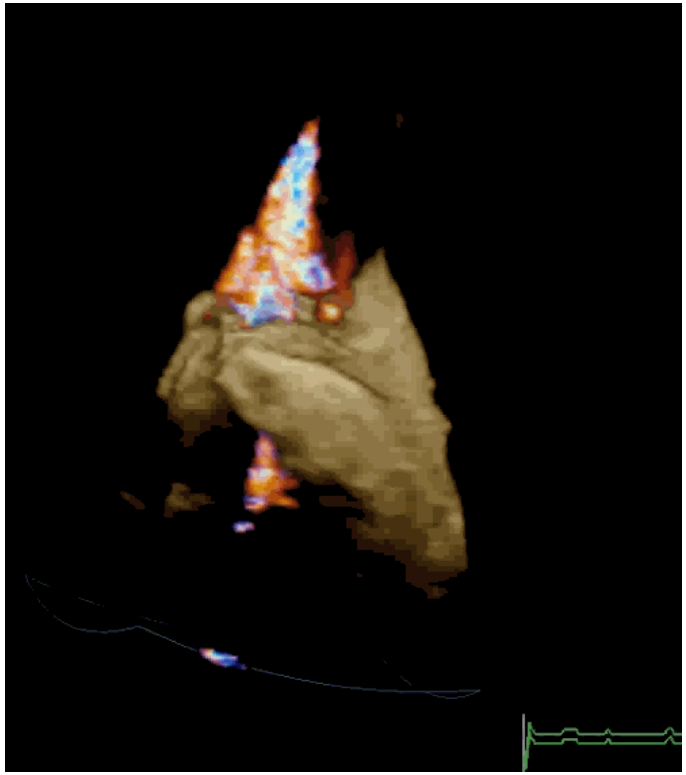

J Am Soc Echocardiogr 2010; 23:26-32 European Heart Journal (2015) 36, 3075–3123

Dehiscencia periprotésica

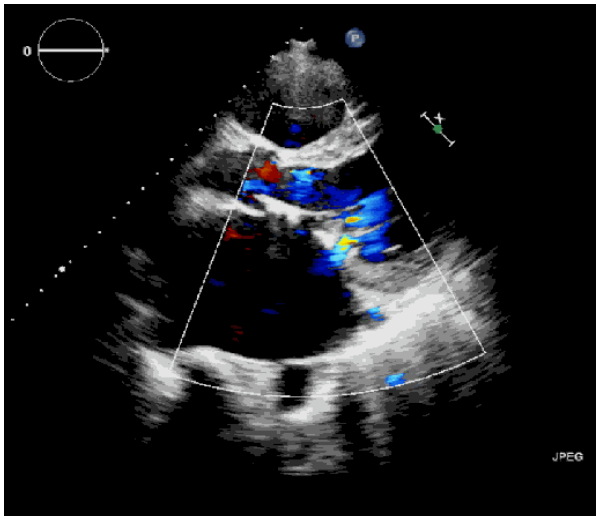

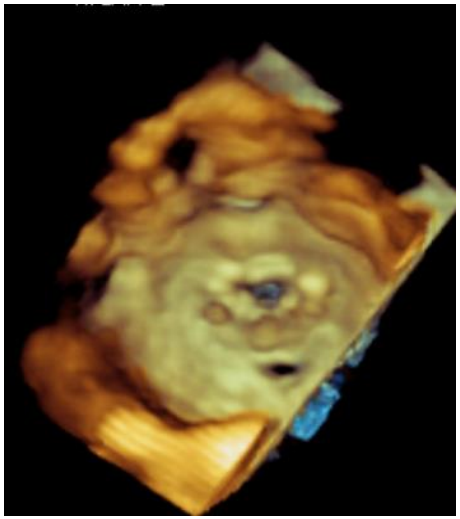

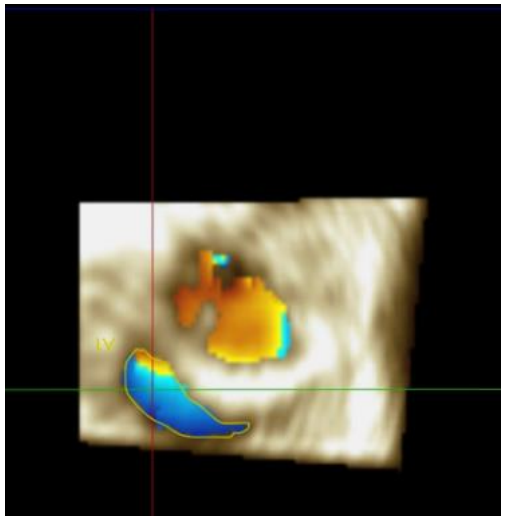

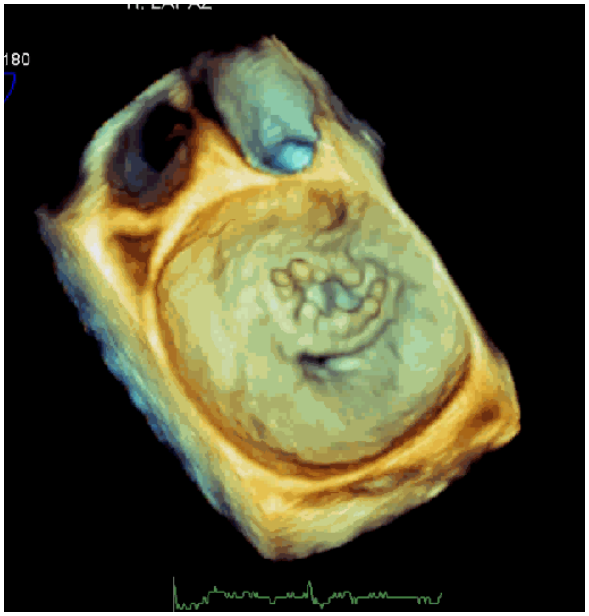

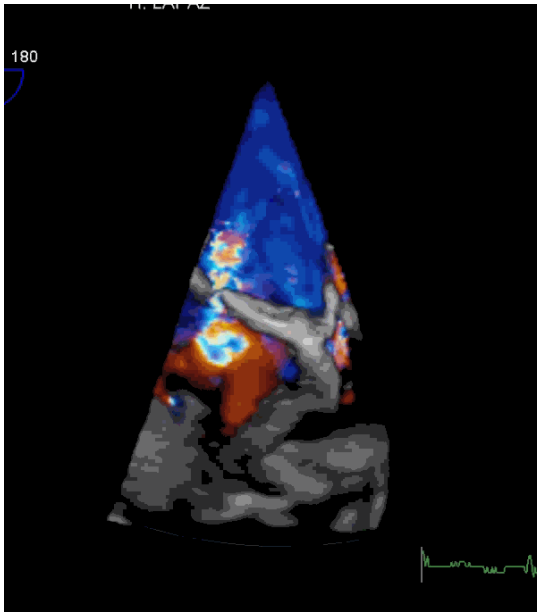

Ecocardiografía en el diagnóstico de endocarditis infecciosa

↓

La ecografía 3D detecta lesiones diagnósticas de EI

- Seleccionar la **estructura de interés**
- **Optimizar imagen 3D**

Limitaciones de la técnica/operador

Ajuste ganancias…

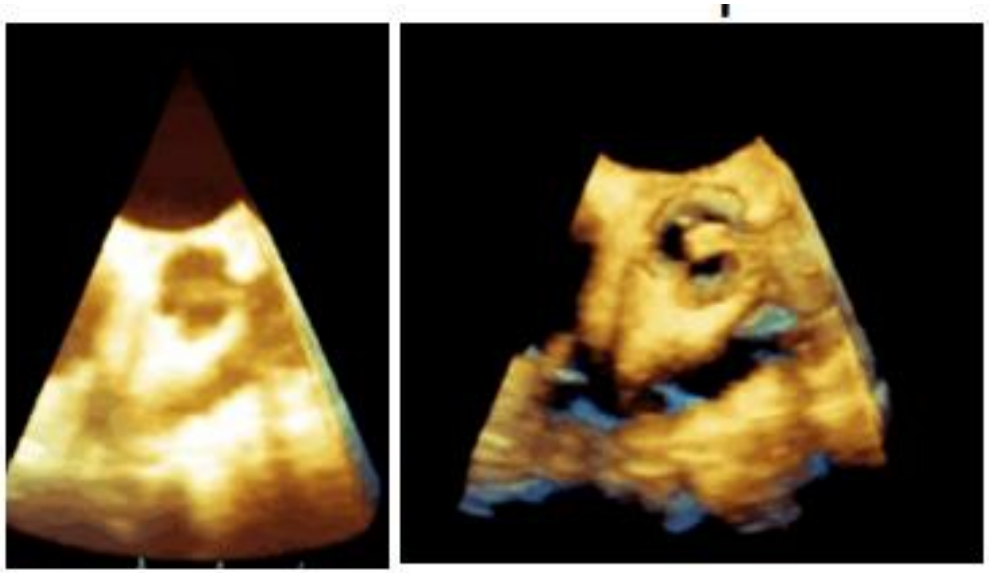

JASE 2008;21(9):979-89

Eco 3D en Endocarditis Infecciosa

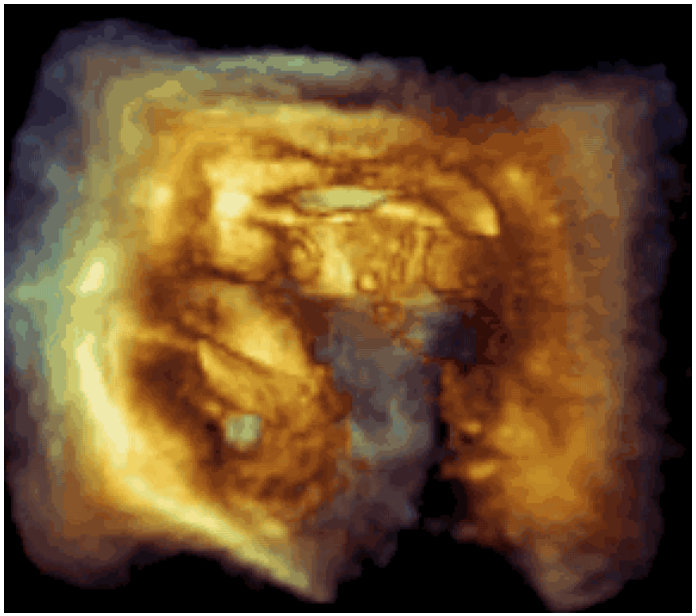

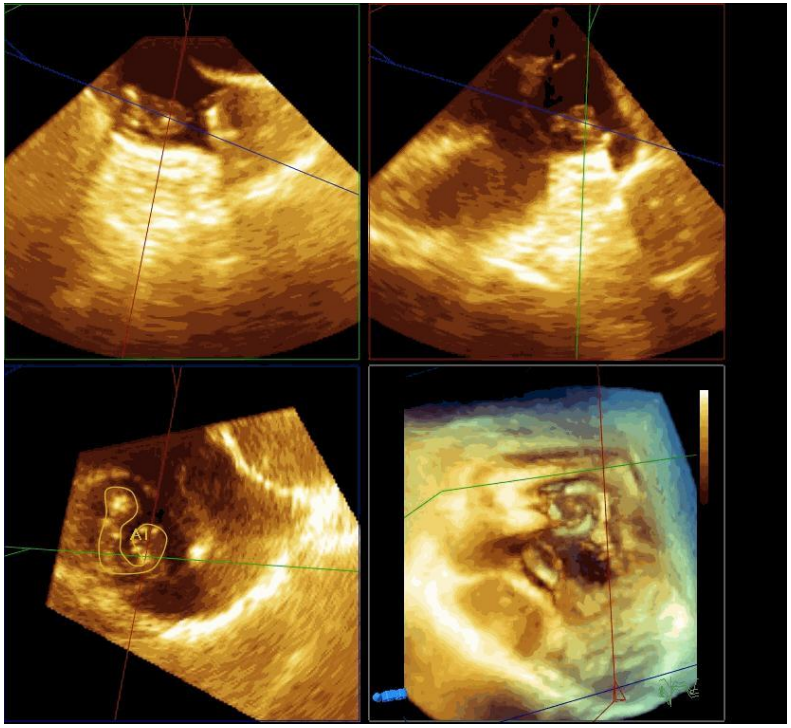

Artefactos de adquisición: número de latidos; ECG; apneas

JASE 2008;21(9):979-89

Eco 3D en Endocarditis Infecciosa

Resolución temporal

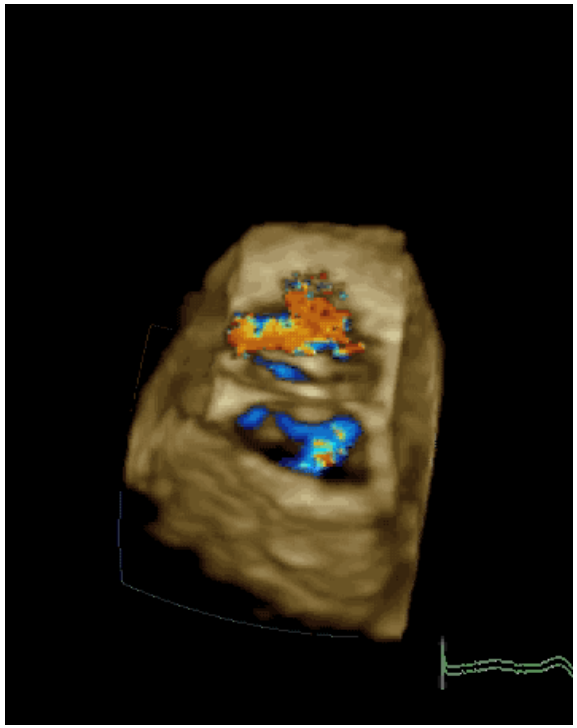

Vol completo color
1 latido (4Hz)

Vol completo color
4 latidos (17Hz)

Eco 3D en Endocarditis Infecciosa

Limitaciones de la técnica: Resolución espacial

% Visualización óptima

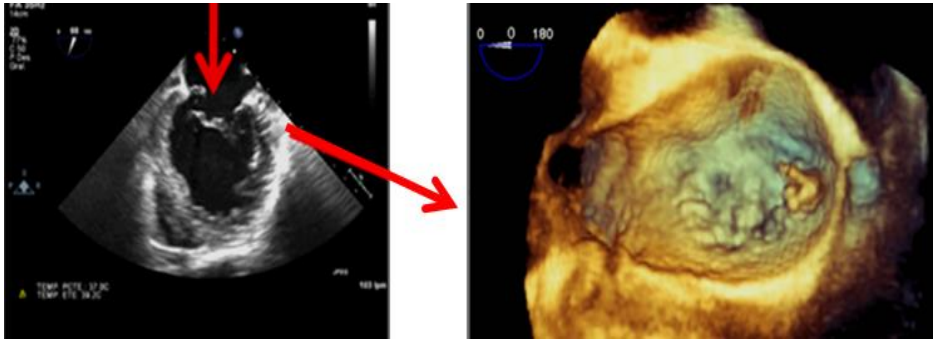

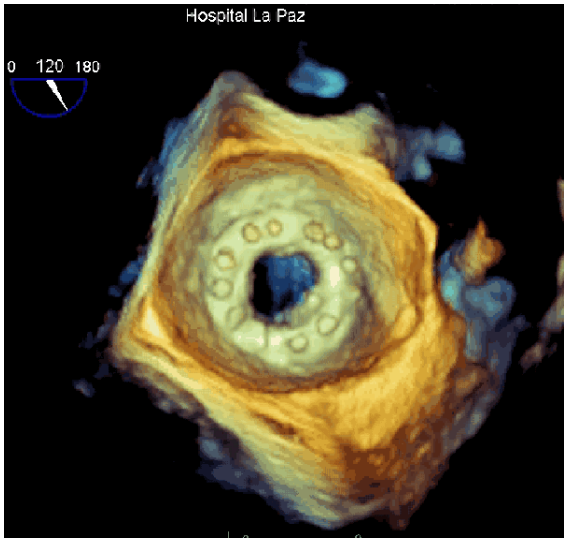

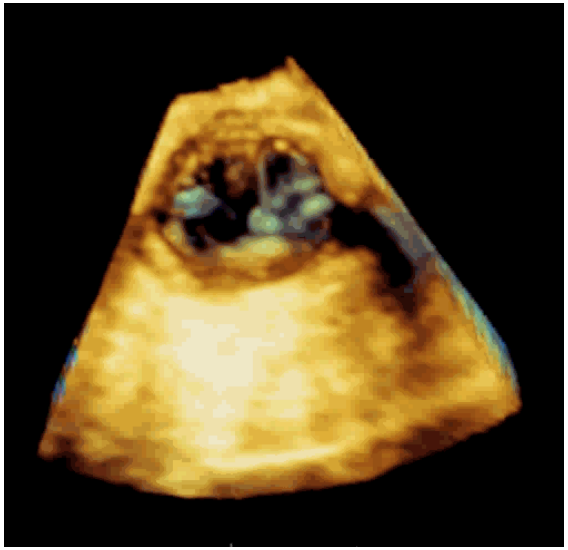

Eco 3D en Endocarditis Infecciosa

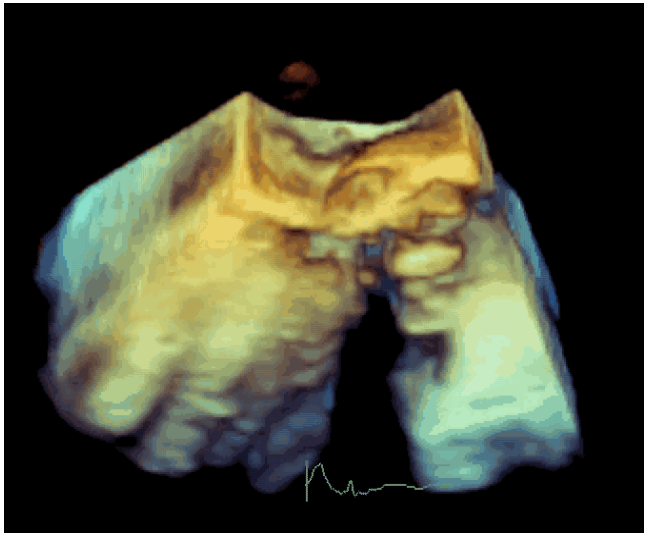

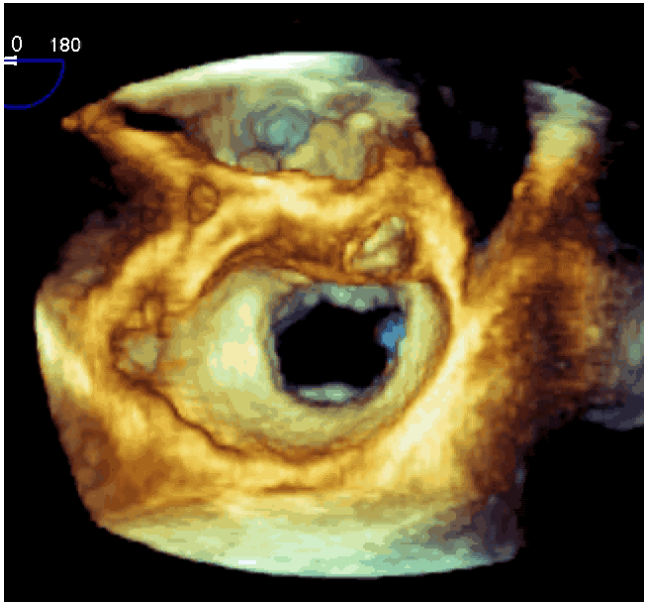

Mujer de 68 a.
Mayo 2010
EI aórtica
Pseudoaneurisma de la FMA

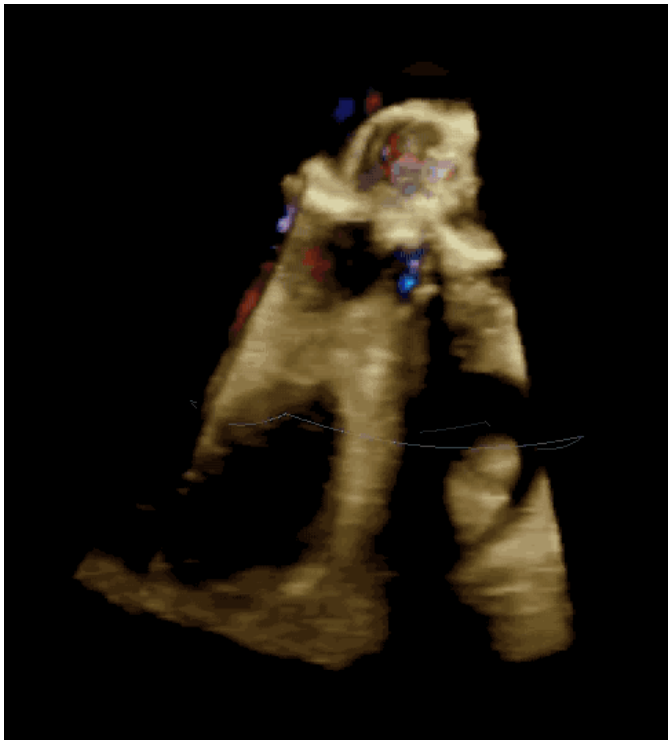

Eco 3D en Endocarditis Infecciosa

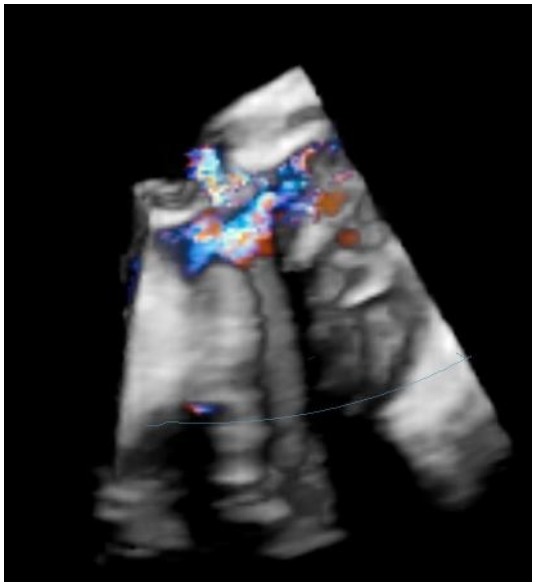

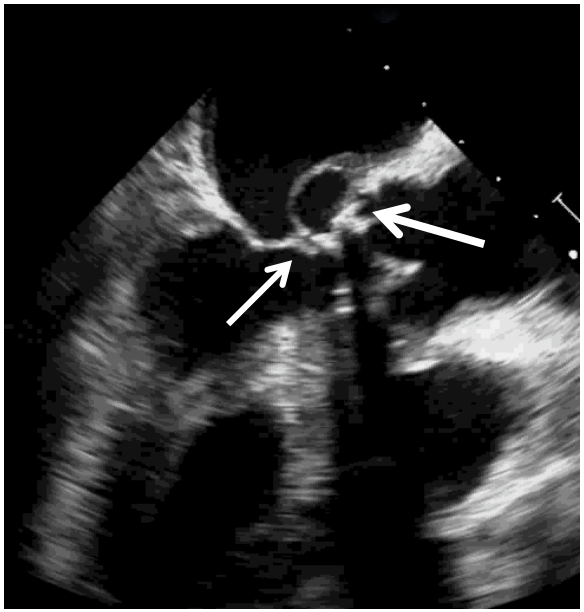

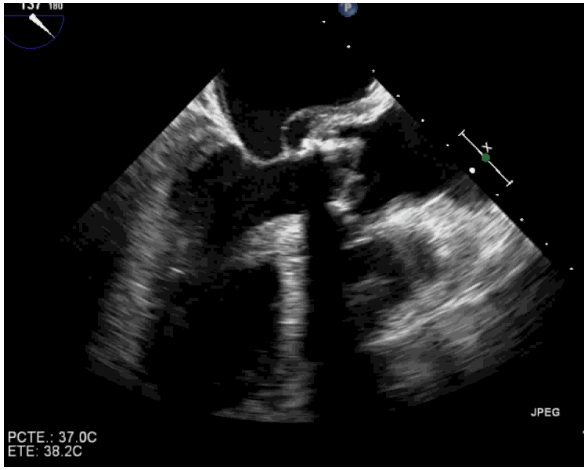

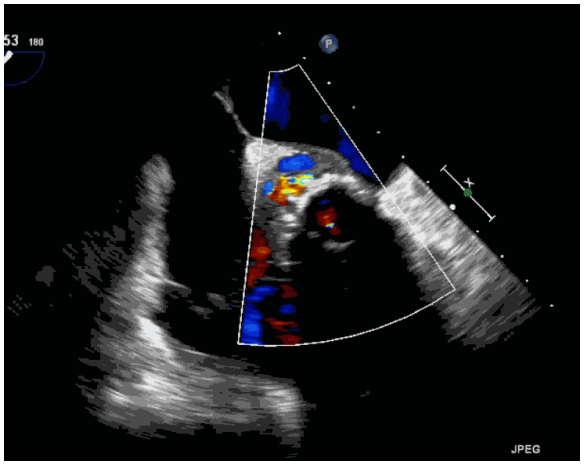

Eco 3D en Endocarditis Infecciosa

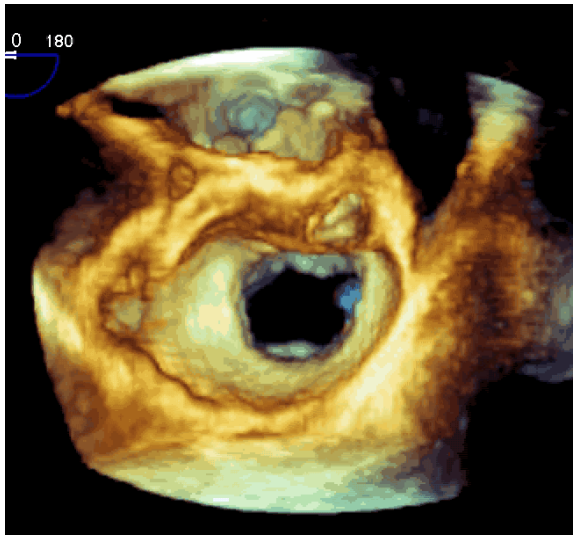

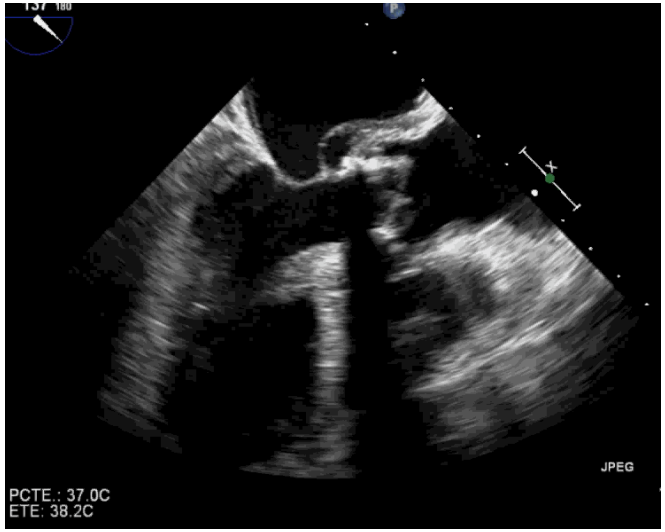

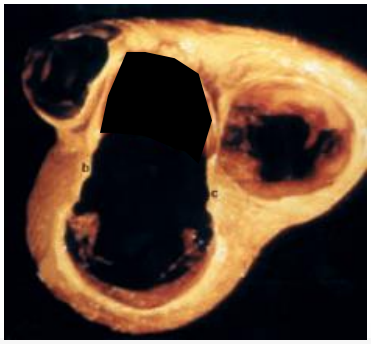

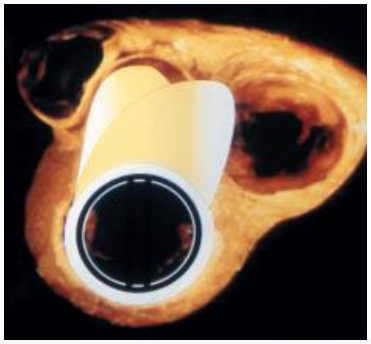

Cirugía de reconstrucción del cuerpo fribroso intervalvular en la endocarditis infecciosa activa

Enrique Rodríguez, Alberto Forteza, Fernando Enríquez, Luis L. Almodóvar, José Cortina, Enrique Pérez, Luis Maroto y Juan José Rufilanchas

Rev Esp Cardiol 2001; 54: 289-293

Marzo 2011. Ingresa por ICC

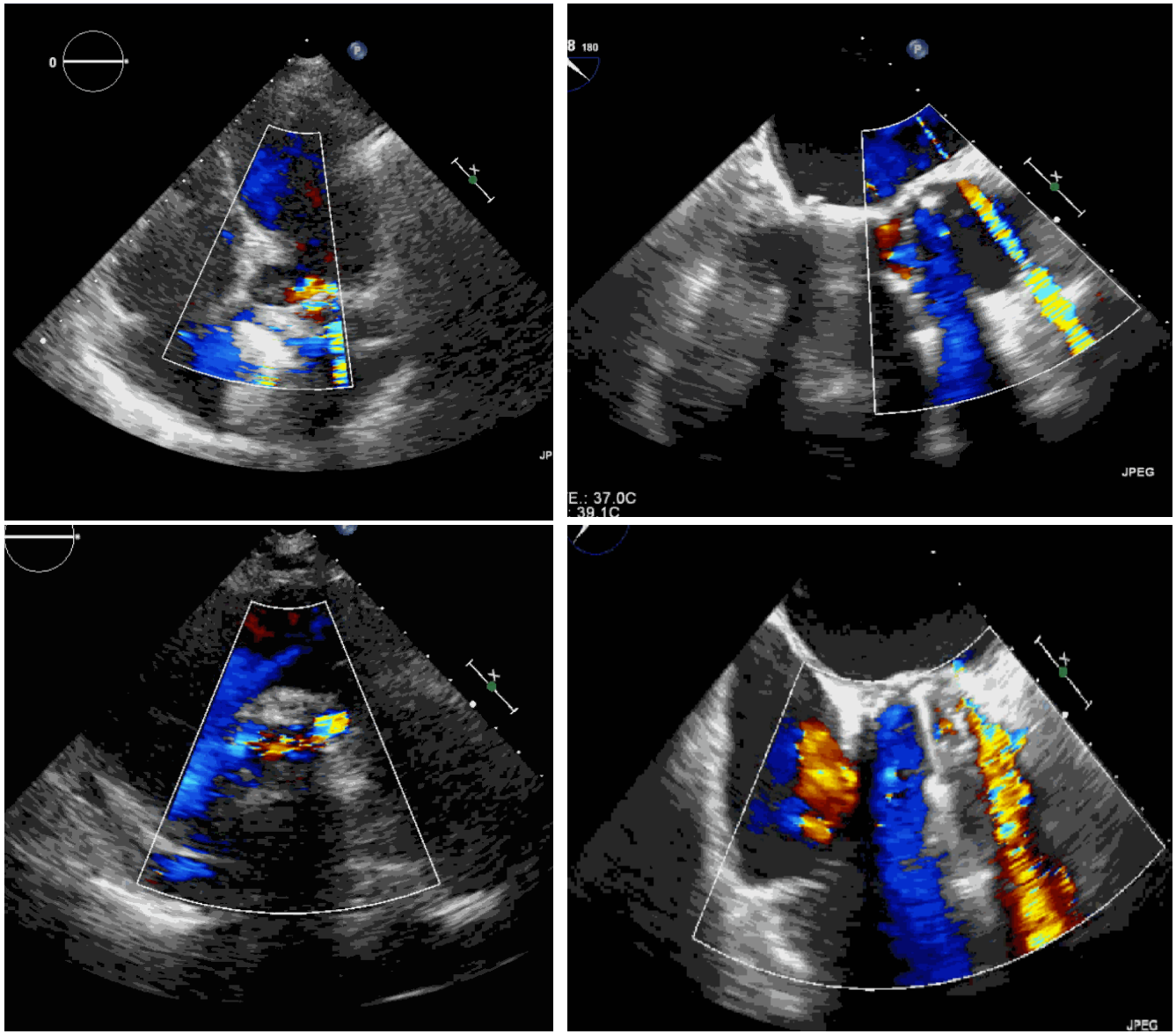

Eco 3D en Endocarditis Infecciosa

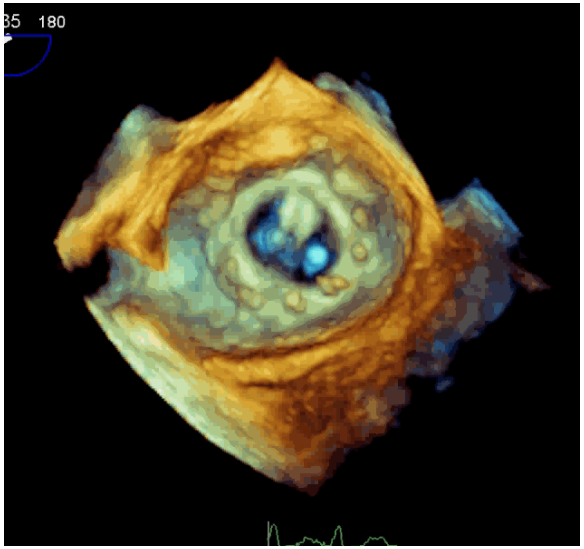

Marzo 2011. Ingresa por ICC
Afebril
Mejora con tto médico

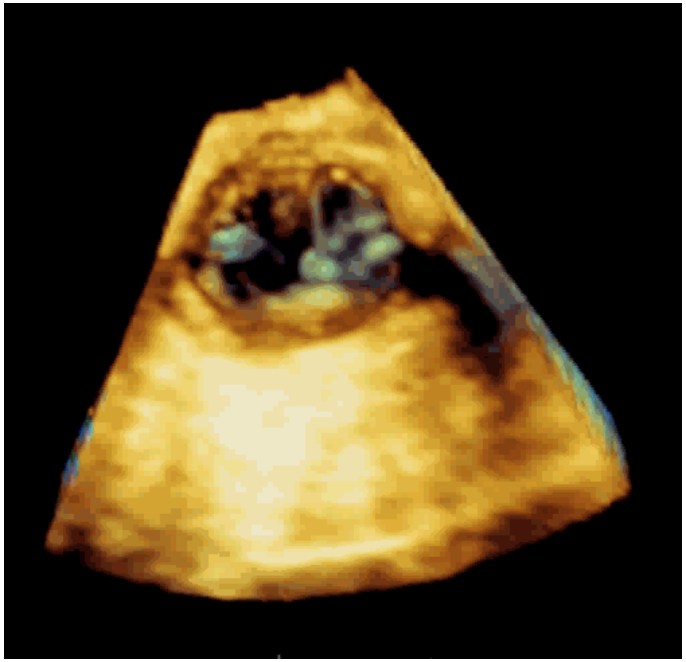

Eco 3D en Endocarditis Infecciosa

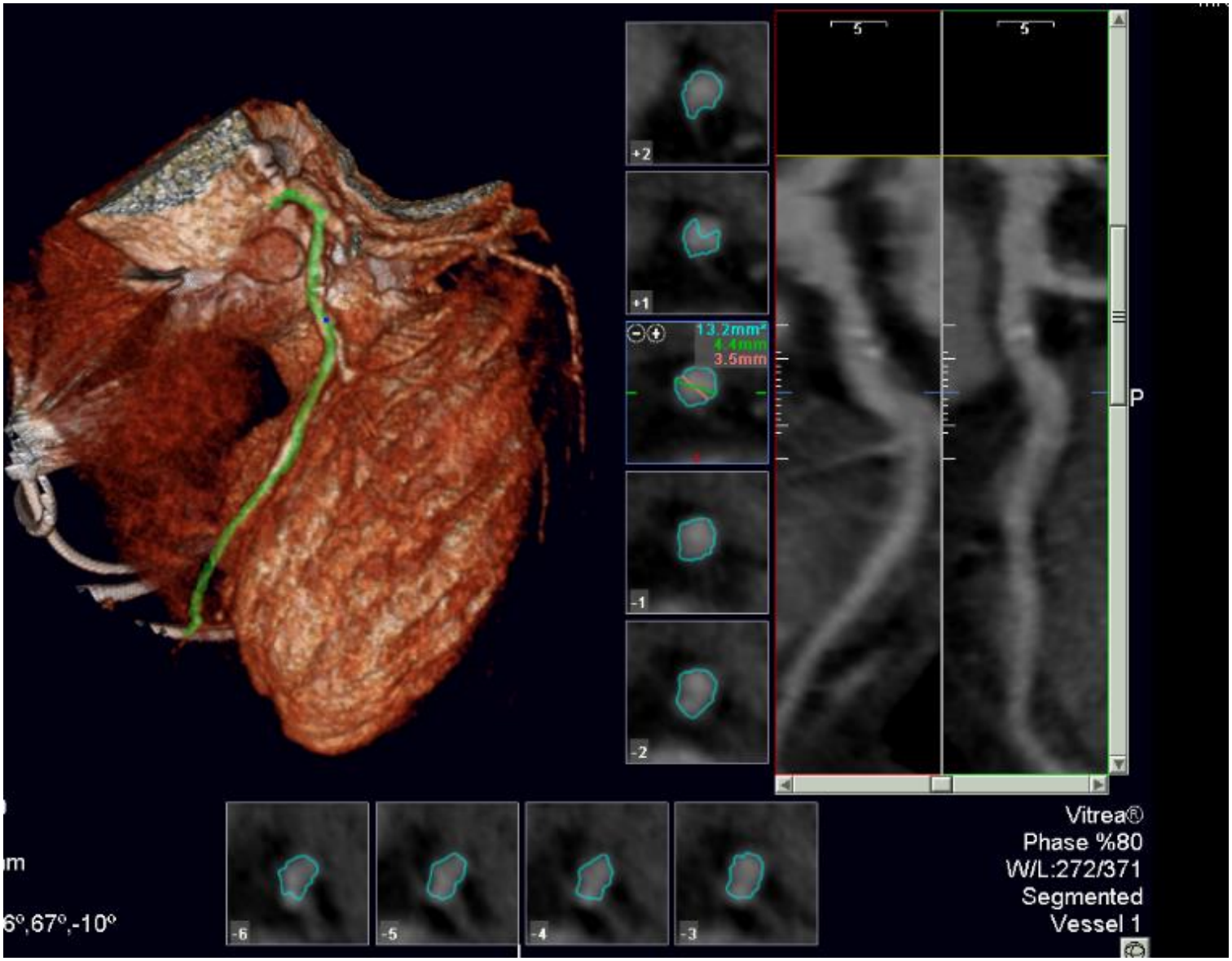

EI sobre válvula protésica

- Forma **más severa** de EI (10-30% de las EI)
- Incidencia de 0.3-1.2 por paciente-año
- Dos grupos: precoz <1 año (Staf, hongos y BGN)

  tardía >1 año (Staf, S.orales, S.bovis, Enterococo)

- Sin embargo, lo realmente importante, es si existe

  -**Contaminación perioperatoria**.:

  Dehiscencias, pseudoaneurismas, fístulas

  - **EIP tardía**: vegetaciones = disfunción protésica

European Heart Journal (2015) 36, 3075–3123

COMPREHENSIVE REVIEW ARTICLE

J Am Soc Echocardiogr 2010;23:1009-18

Pseudoaneurysm of the Mitral-Aortic Intervalvular Fibrosa (MAIVF): A Comprehensive Review

Selvin Sudhakar, MD, Asif Sewani, MD, Mayank Agrawal, MD, and Barry F. Uretsky, MD, *Fort Smith and Little Rock, Arkansas*

Presentación clínica

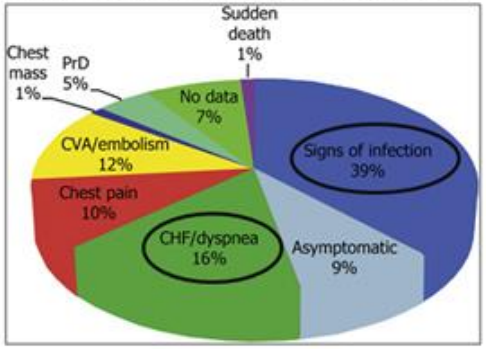

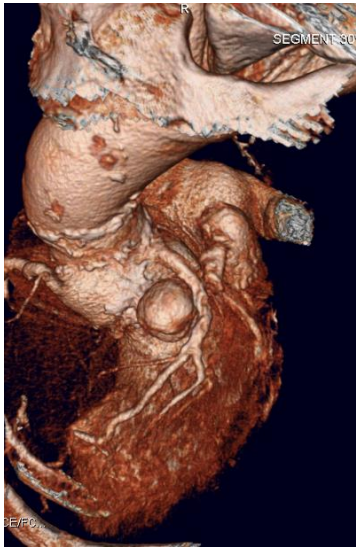

Table 3 Complications of P-MAIVF
Compression
Coronary artery: angina, thrombosis (myocardial infarction), dissection, aneurysm
Pulmonary artery: pulmonary hypertension
Mitral valve: mitral regurgitation
Fistula formation
Aorta
Left atrium
Rupture
Pericardial tamponade, death
Thrombosis
Transient ischemic attack, cerebrovascular accident
Infection
Endocarditis, fistula formation
Heart failure

Evolución

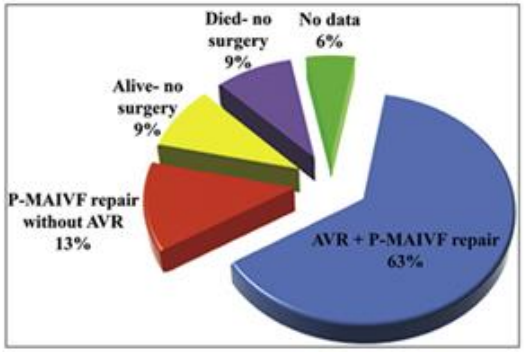

Dos grupos de riesgo

✓EI activa + abscesos FMA

✓Hª de EI o cirugía valvular

Eco 3D en Endocarditis Infecciosa

1. Detectar lesiones típicas de EI: p^{al} ETE
2. Limitaciones:
   - -Artefactos
   - -Resolución temporal
   - -Resolución espacial

   → Técnica
   Operador
3. ¿ Mejora la valoración anatómica?
   ¿ Resuelve las limitaciones del eco 2D?

DD masas cardiacas

Los resultados de la ecografía siempre deben interpretarse en el contexto clínico

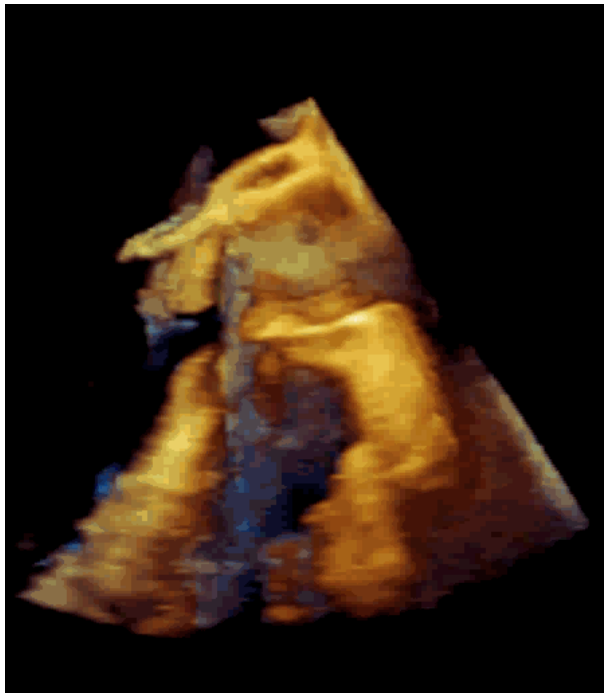

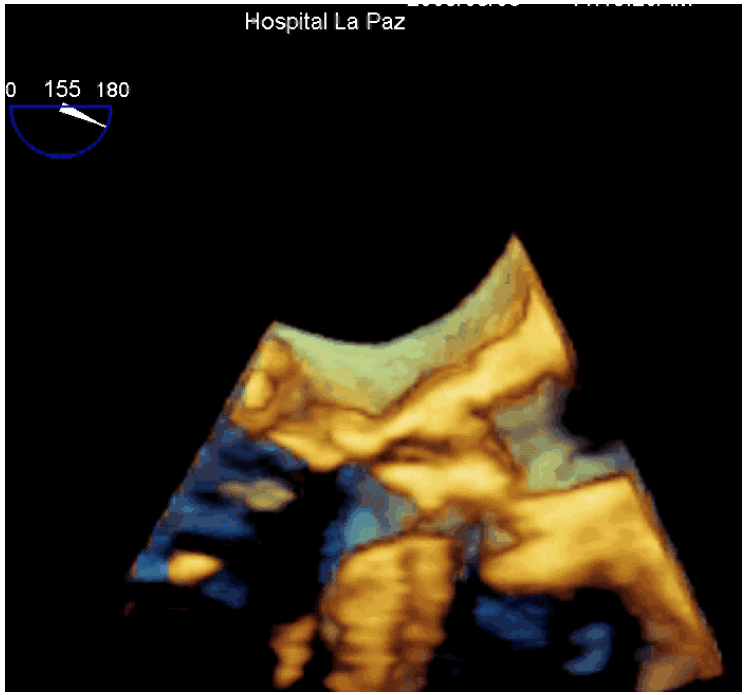

European Journal of Echocardiog 2010:202–219

European Heart Journal (2015) 36, 3075–3123

DD masas cardiacas

Los resultados de la ecografía siempre deben interpretarse en el contexto clínico

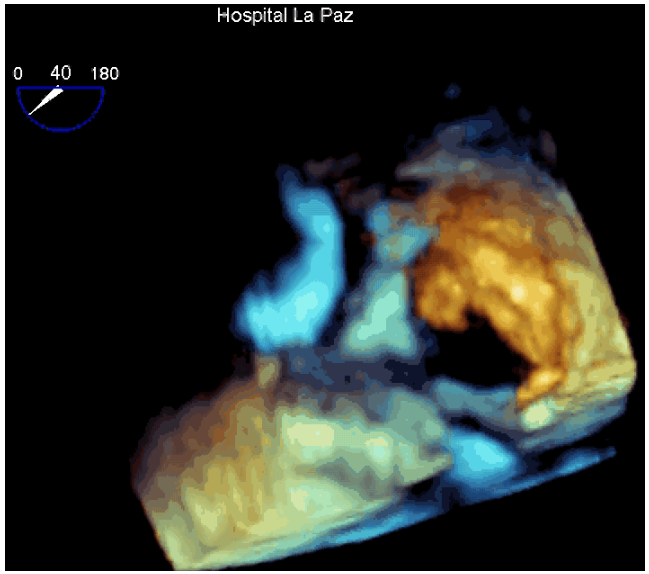

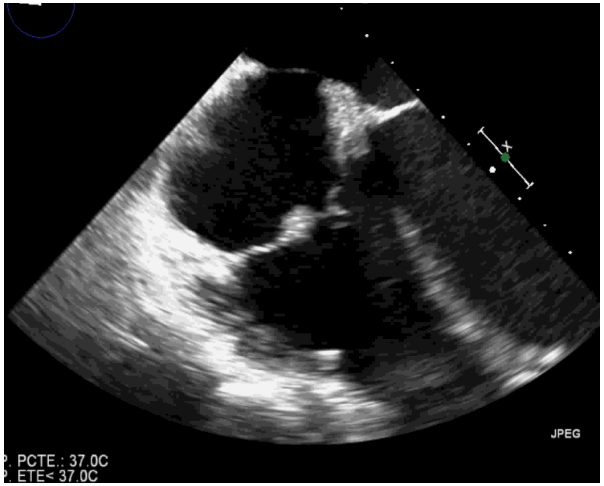

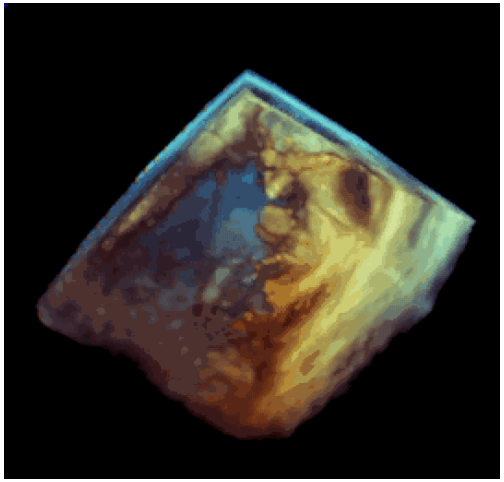

DD masas cardiacas

Los resultados de la ecografía siempre deben interpretarse en el contexto clínico

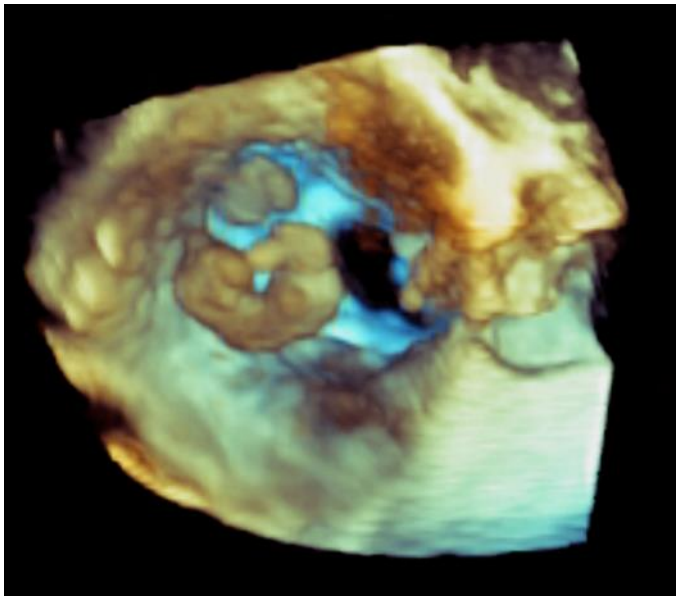

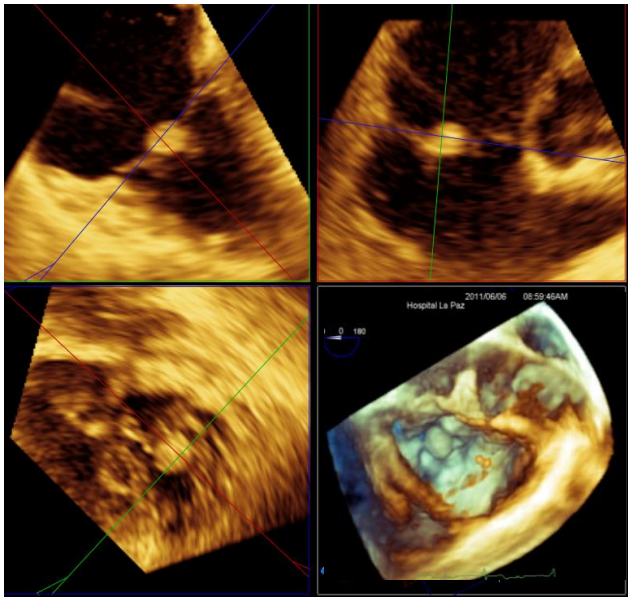

EI tricúspide

Fibroelastoma Tri.

DD masas cardiacas

Los resultados de la ecografía siempre deben interpretarse en el contexto clínico

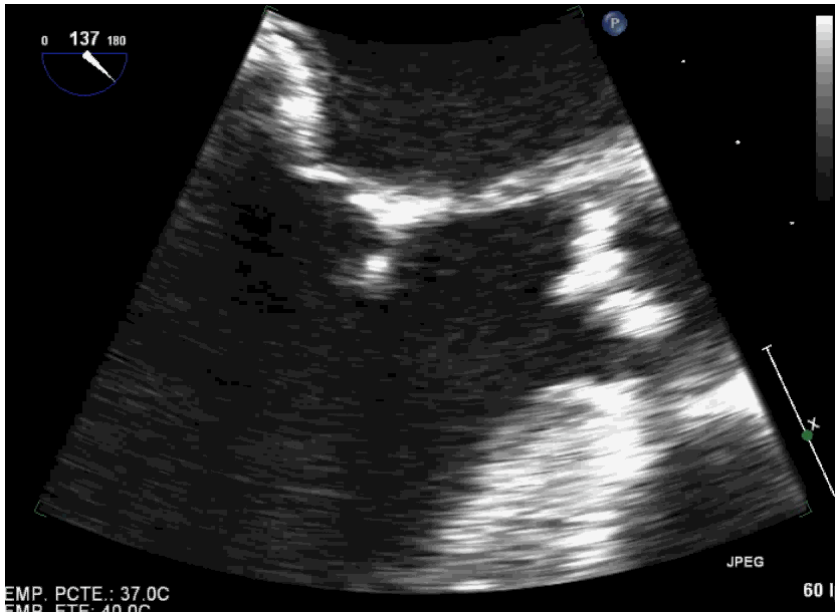

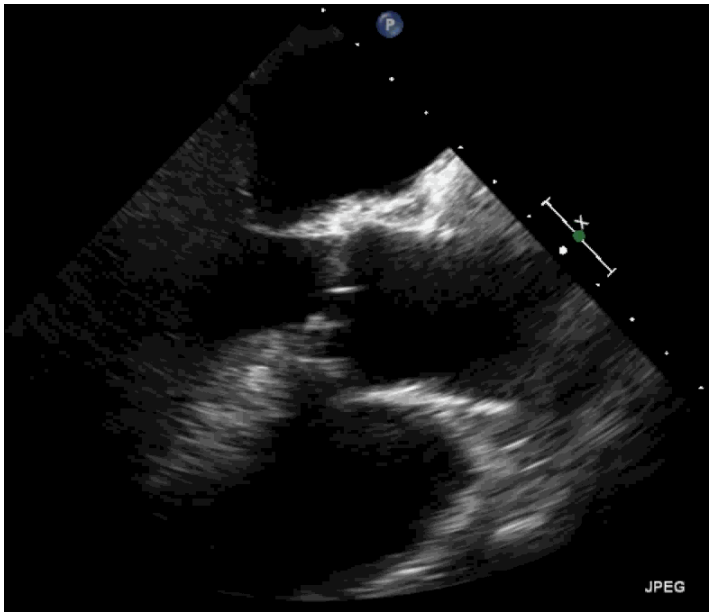

DD masas cardiacas

Los resultados de la ecografía siempre deben interpretarse en el contexto clínico

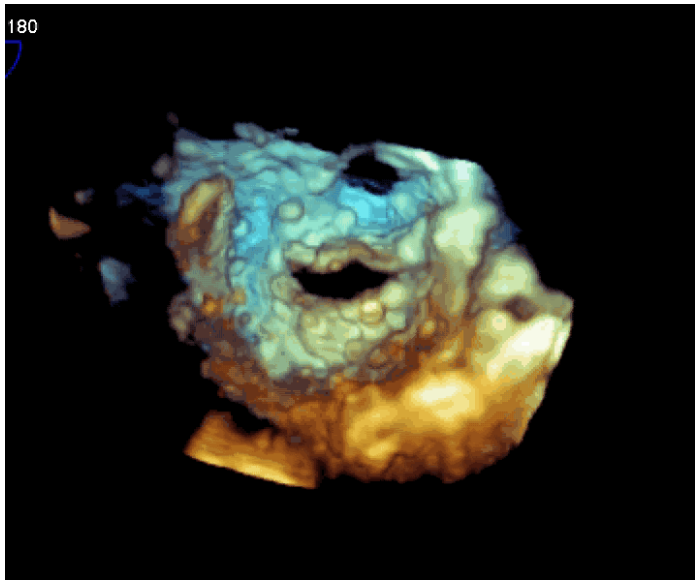

EI mitral

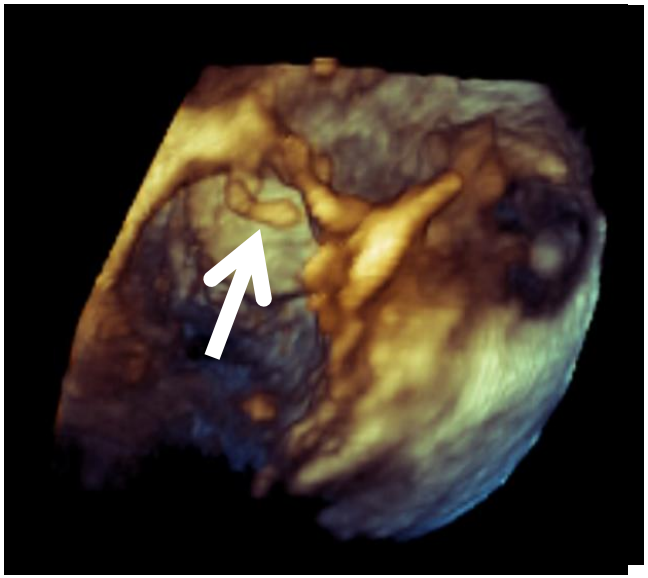

Fibroelastoma Ao

Eco 3D en Endocarditis Infecciosa

DD masas cardiacas

Vegetación atípica

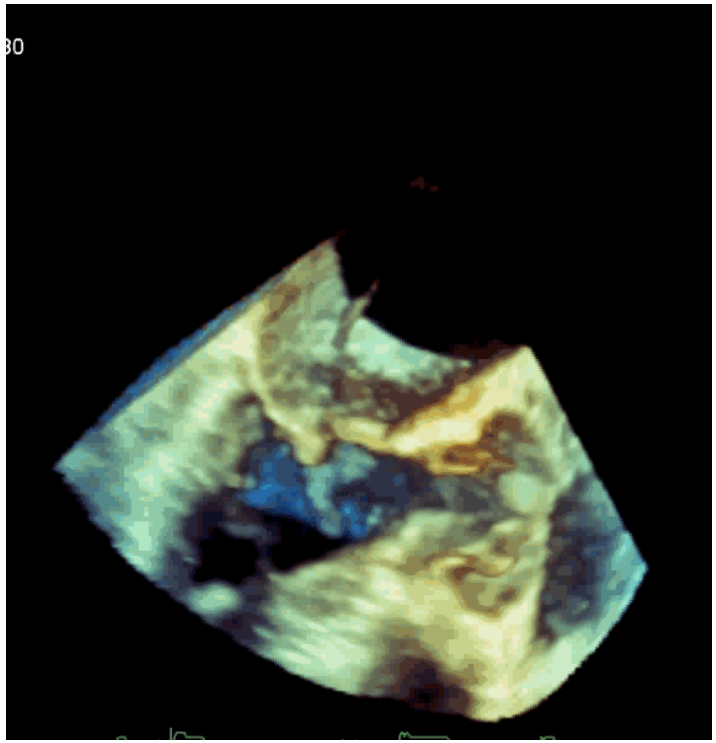

Eco 3D en Endocarditis Infecciosa

DD masas cardiacas

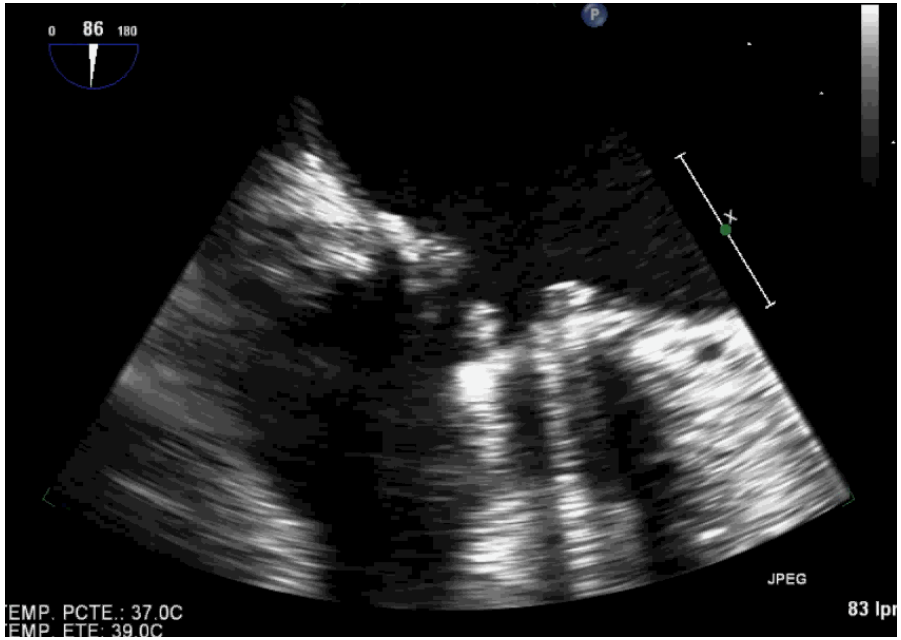

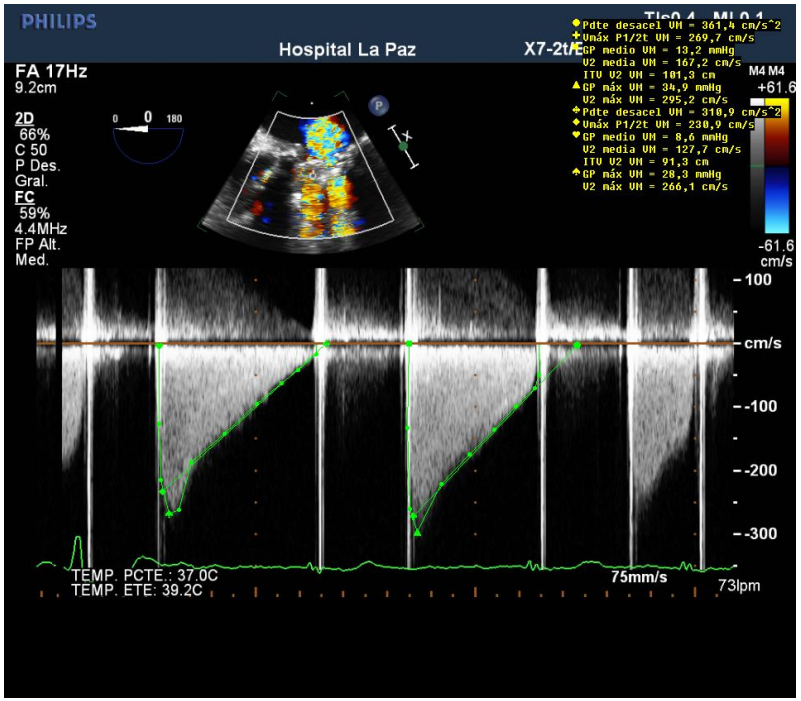

Eco 3D en Endocarditis Infecciosa

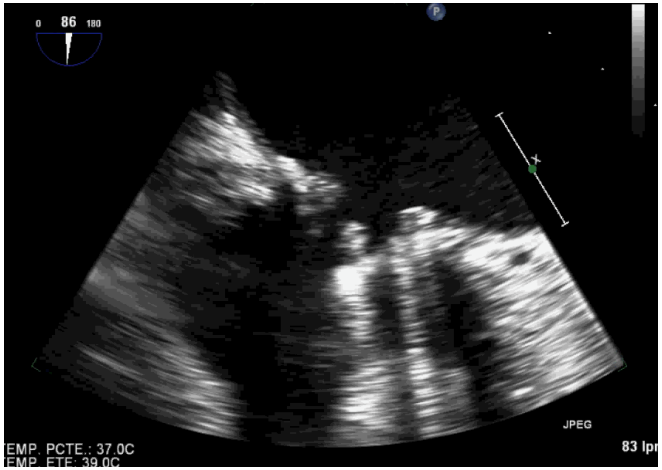

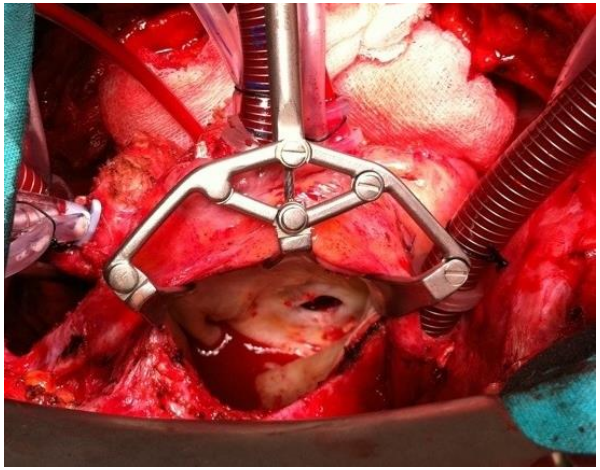

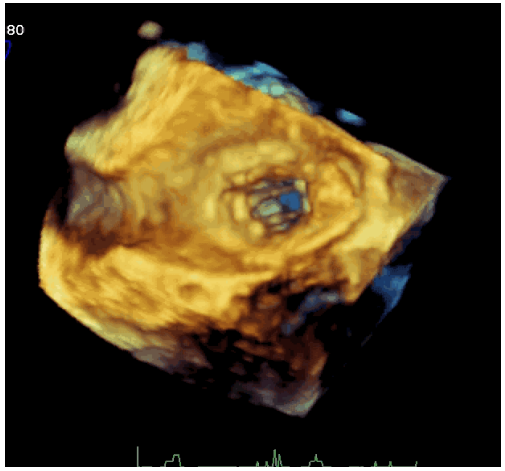

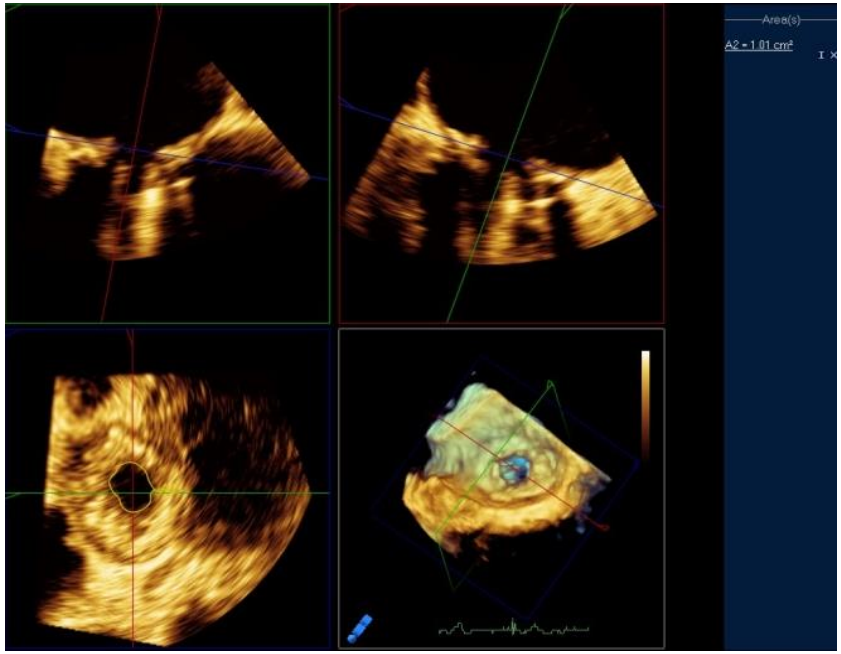

Eco 3D mejora la sensibilidad y especificidad del eco en el Dx de EI mitral

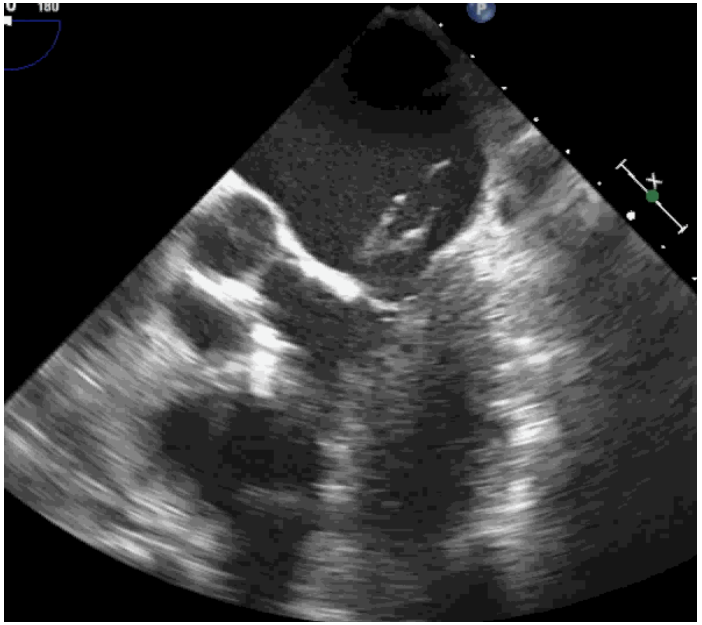

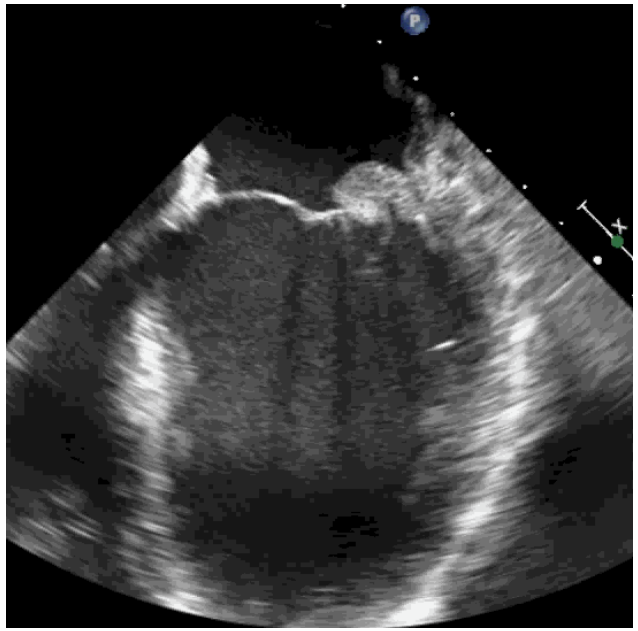

¿Endocarditis mitral?

Prolapso con rotura de cuerdas sin endocarditis

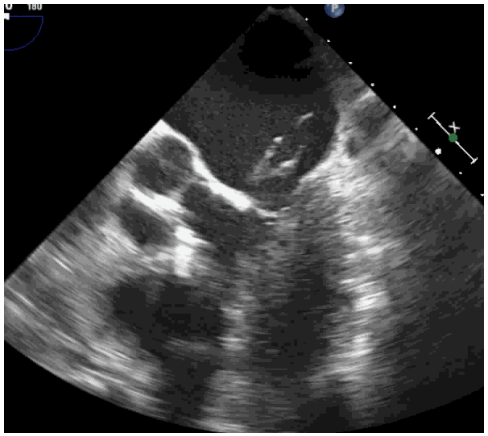

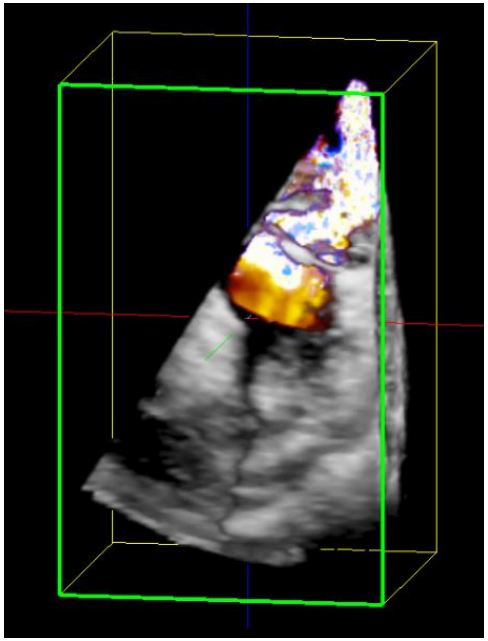

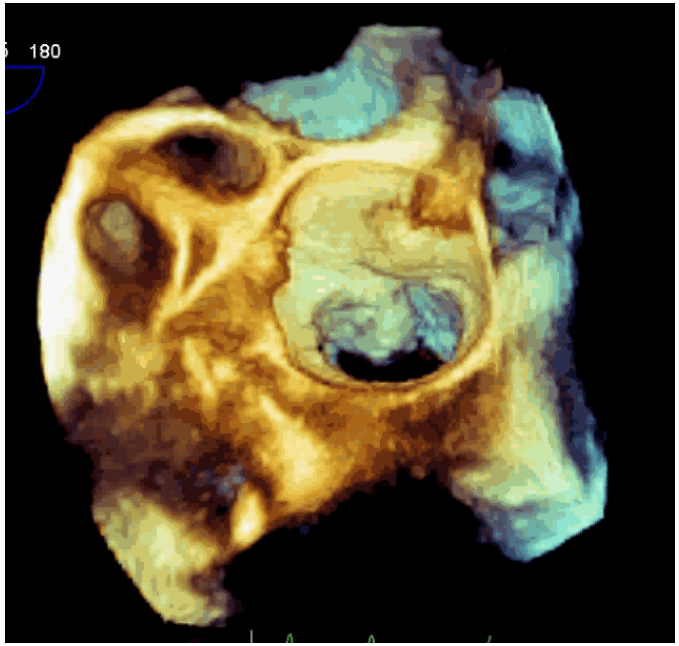

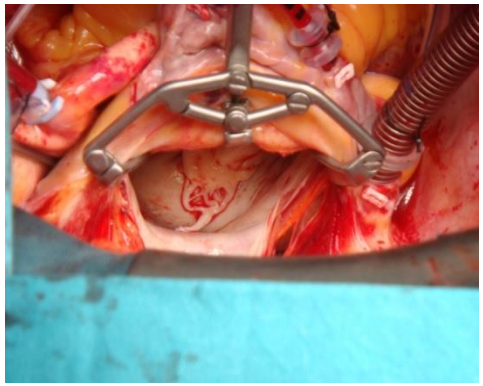

Endocarditis válvula nativa

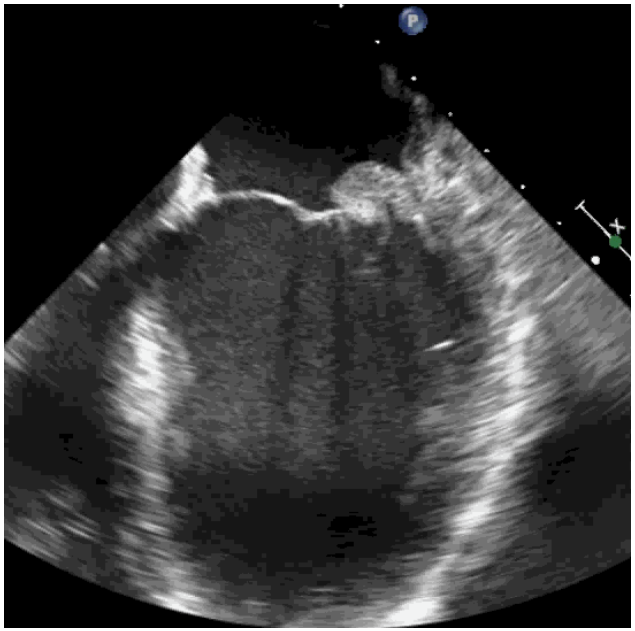

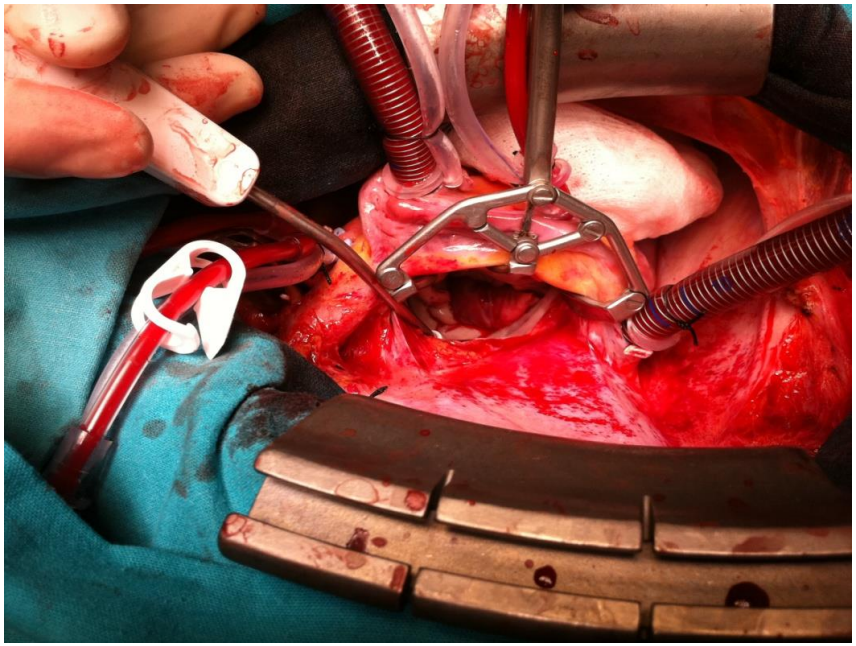

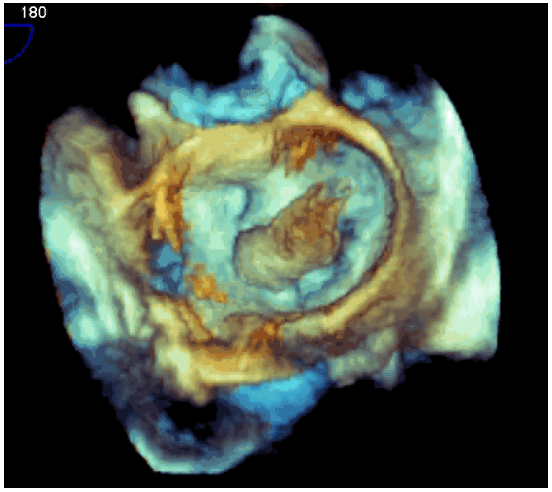

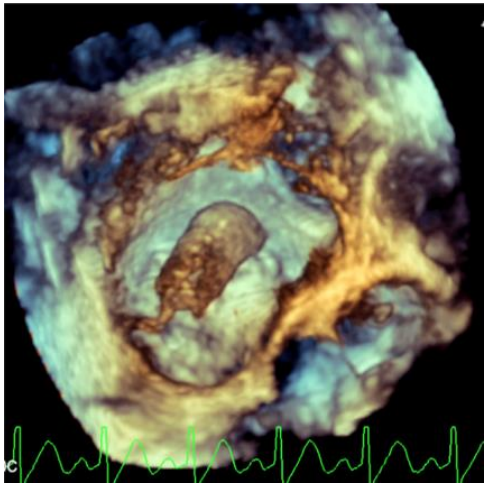

Eco 3D en Endocarditis Infecciosa

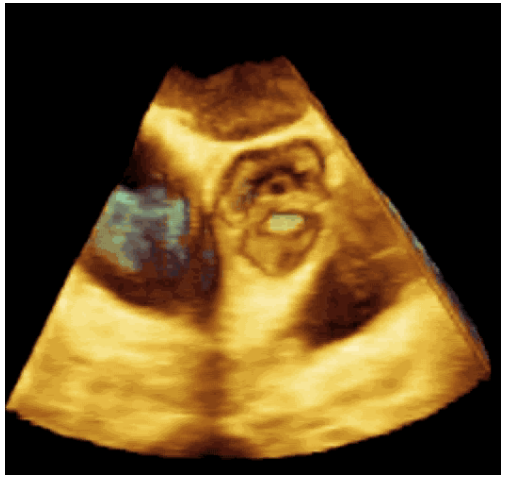

Válvula aórtica

- Cambios degenerativos
- Perforación
- Salida ostium coronarios
- Segmento proximal de DA-Cx

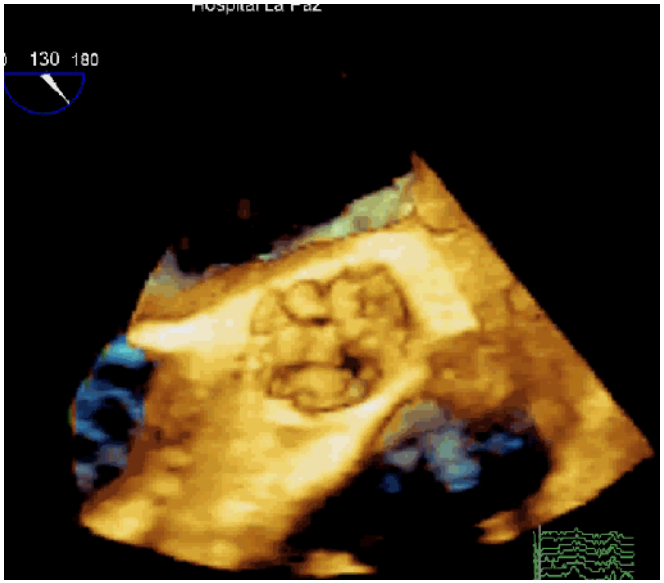

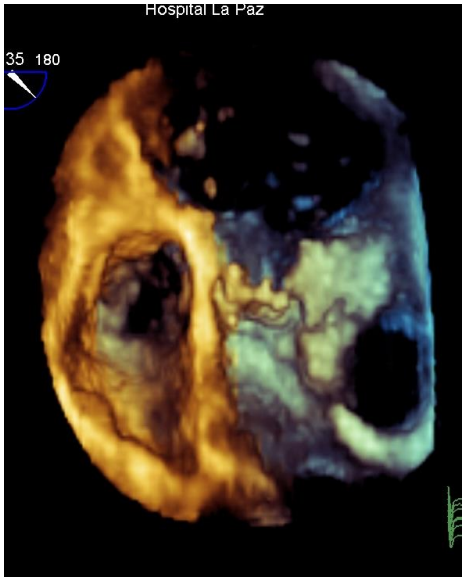

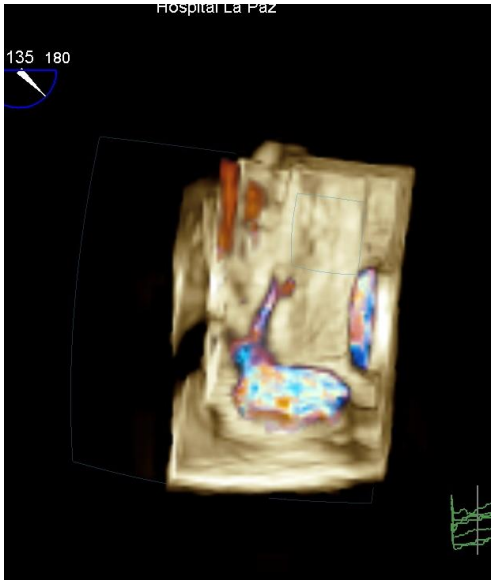

Eco 3D en EI sobre válvula aórtica

- Varón de 63 a. que ingresa por ictus transitorio (ACM-I)
- Fiebre al ingreso + soplo IAo + FA 110lpm
- ETT: Vegetación AO + I Ao severa.

  FSVI conservada

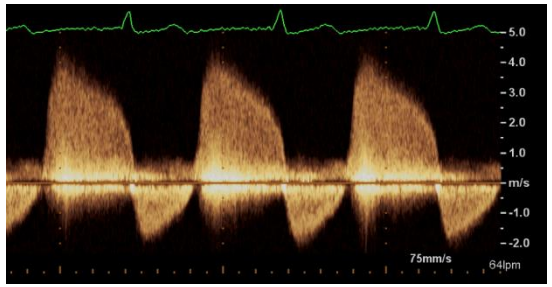

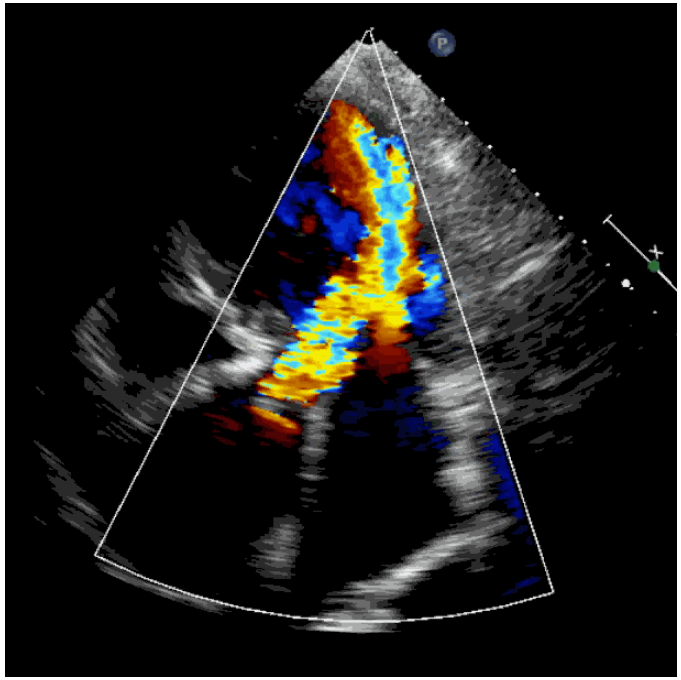

Eco 3D en EI sobre válvula aórtica

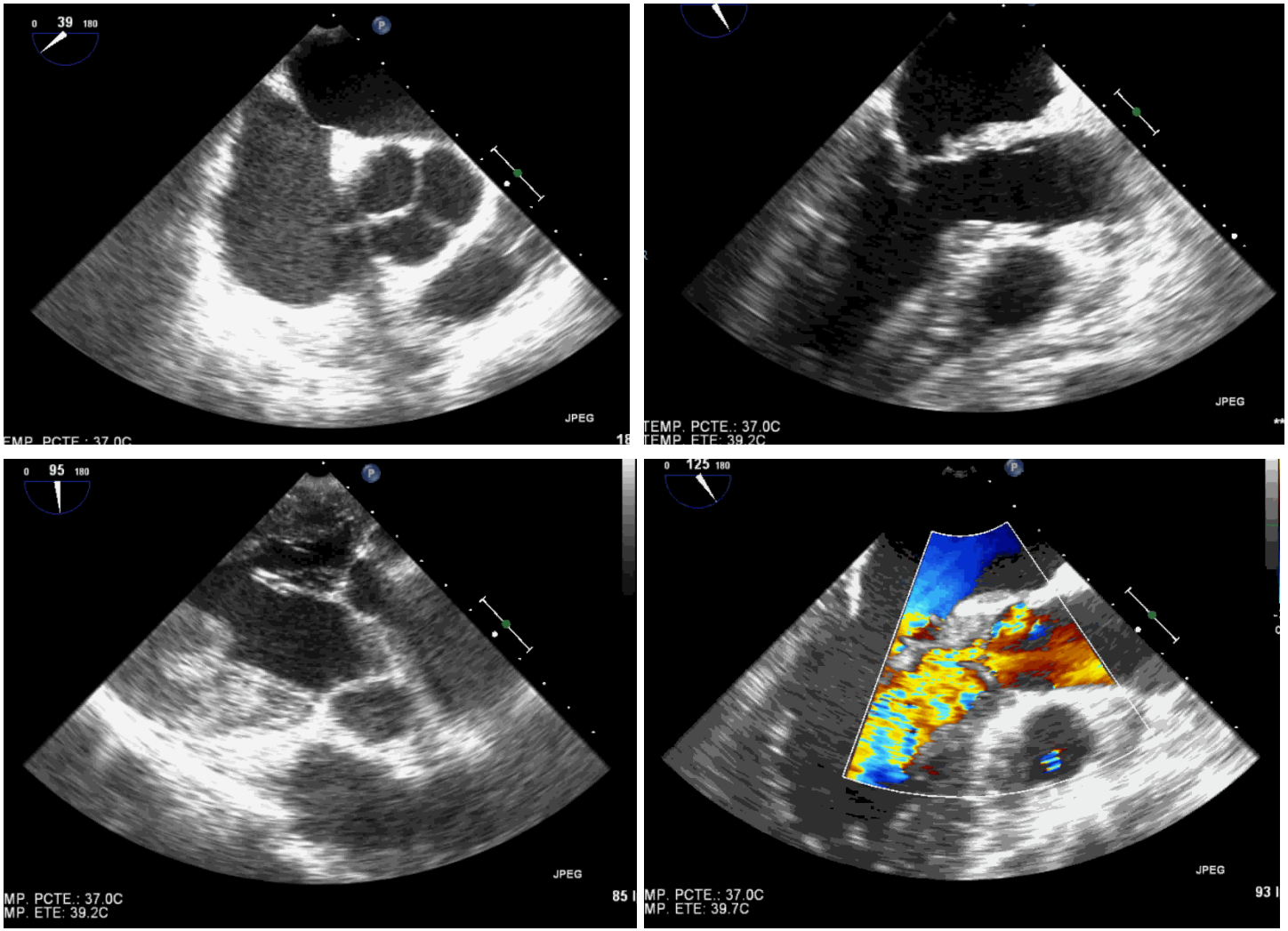

Eco 3D en EI sobre válvula aórtica

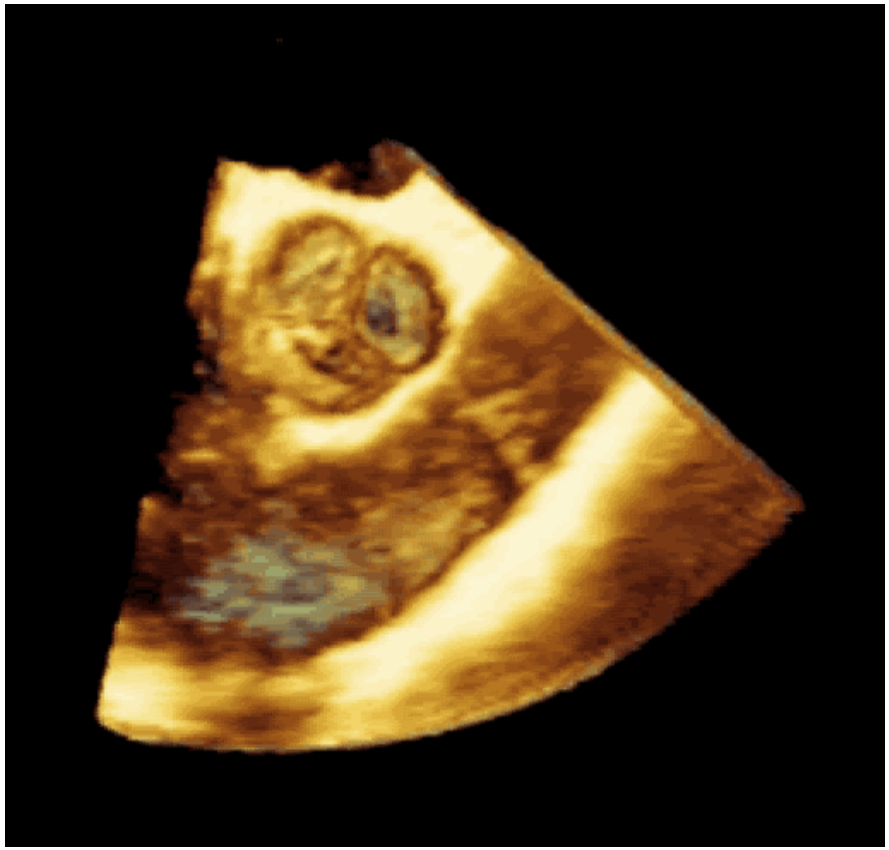

Eco 3D en EI sobre válvula aórtica

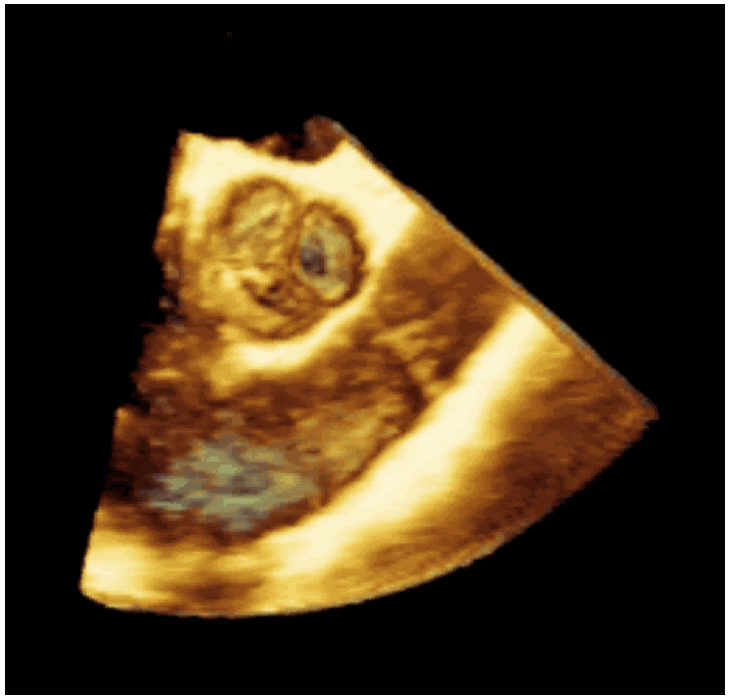

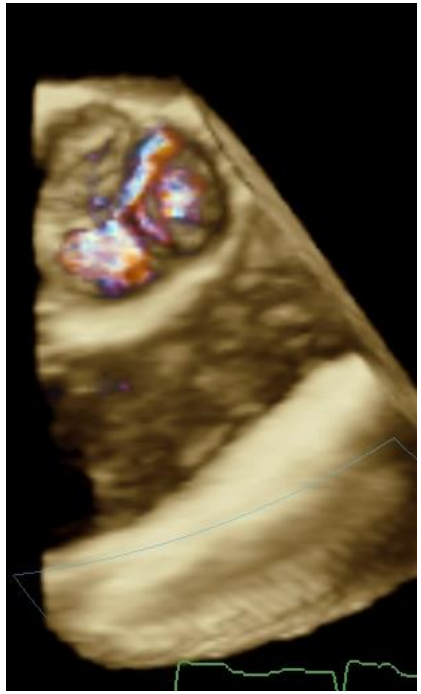

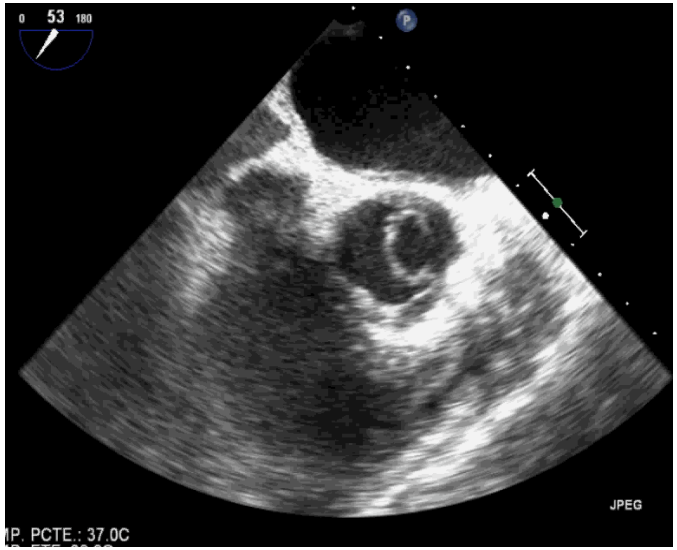

Eco 3D en EI sobre válvula aórtica

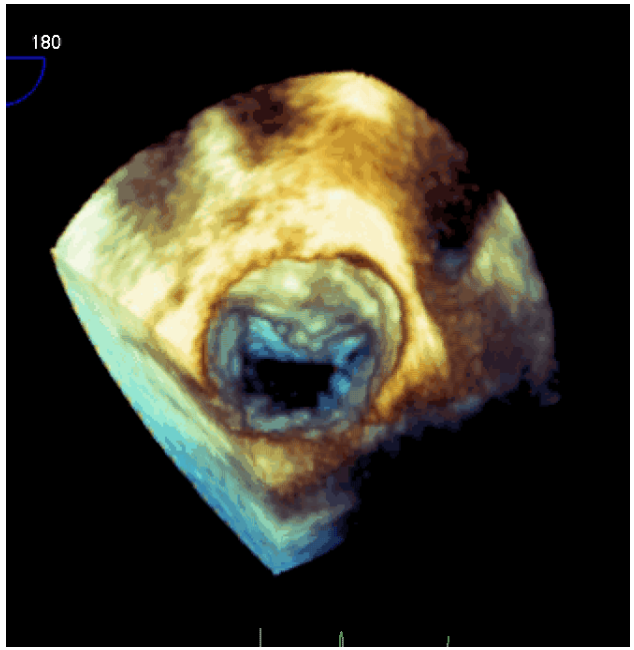

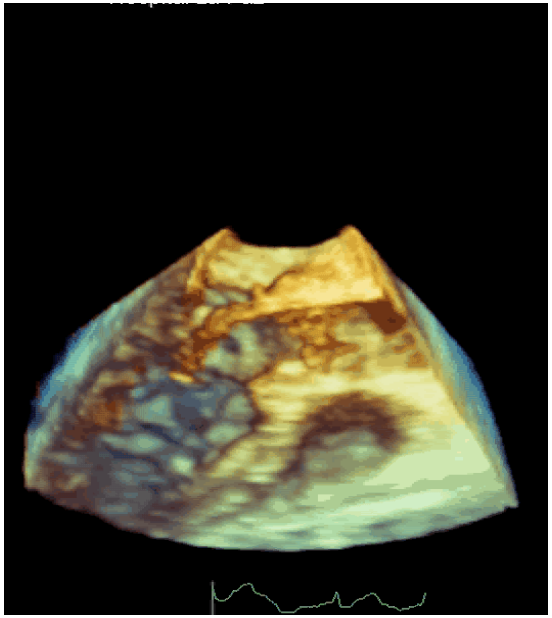

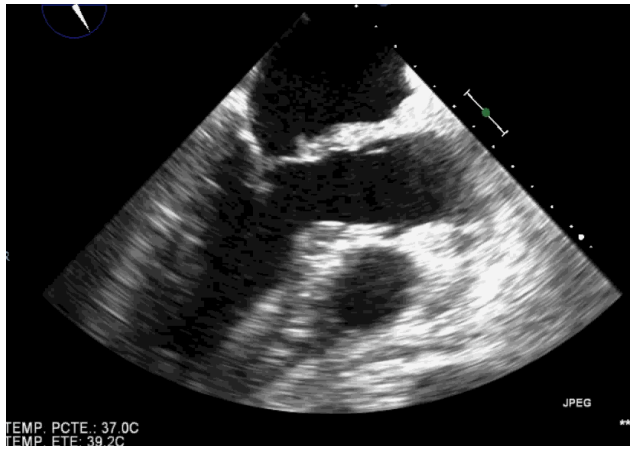

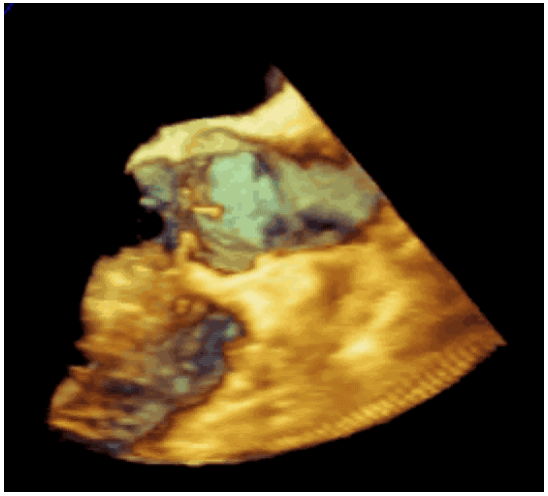

Eco 3D en Endocarditis Infecciosa

Válvula aórtica

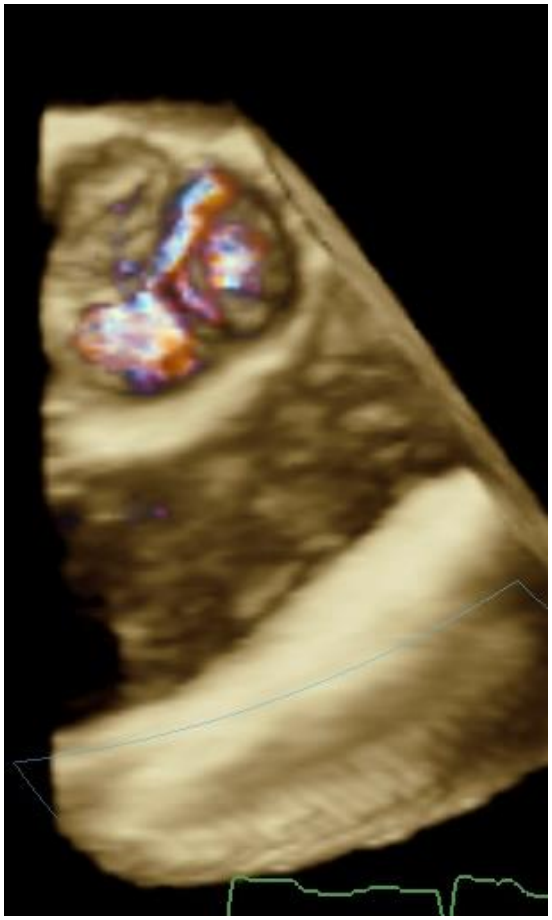

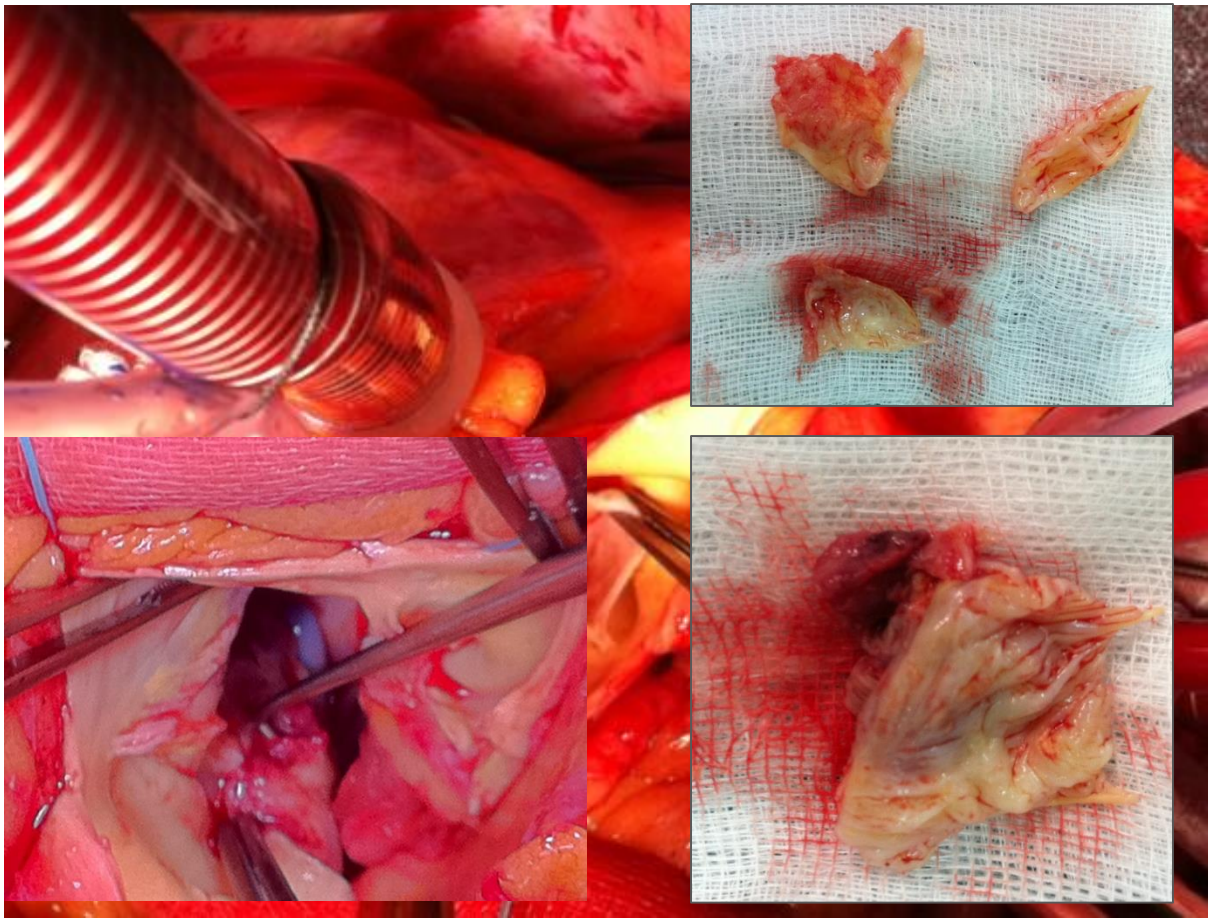

Eco 3D en Endocarditis Infecciosa

Válvula tricúspide

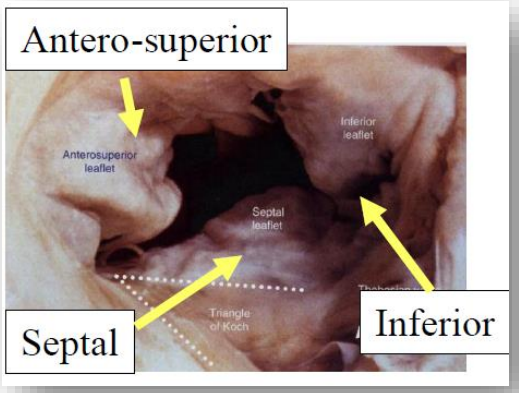

Score N=100	TV annulus	TV leaflets	TV area	TV commissures
Good (4)	60%	80%	55%	50%
Sufficient (3)	30%	10%	30%	20%
Inadequate (2)	10%	10%	15%	20%
Not visualized (1)	0%	0%	0%	10%
Mean score	3.5 ± 0.7	3.7 ± 0.6	3.4 ± 0.7	3.1 ± 1.0
Median score	3.0	3.0	3.0	2.5

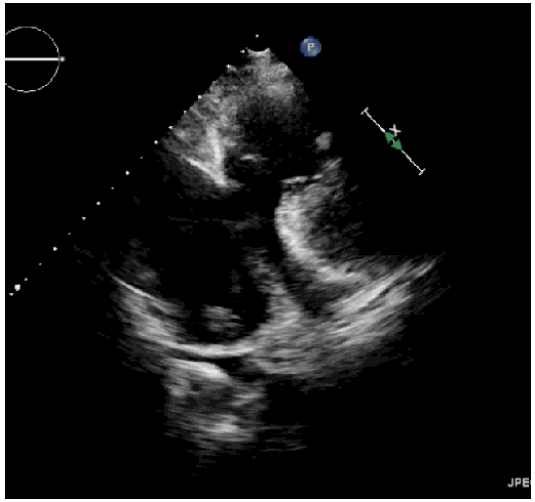

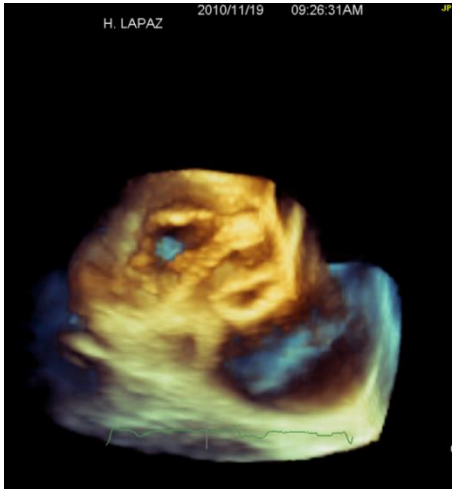

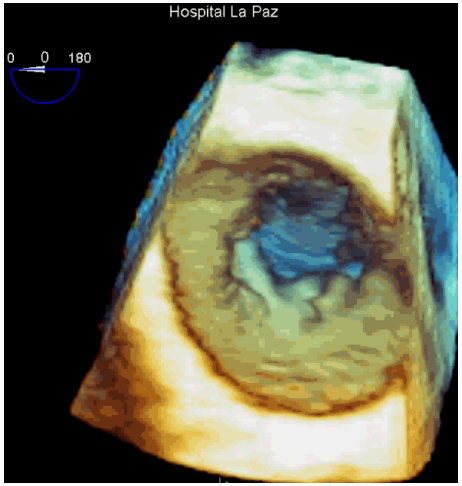

Anwar Am et al Int J Cardiovas Imaging 2007

Eco 3D en Endocarditis Infecciosa

Válvula tricúspide

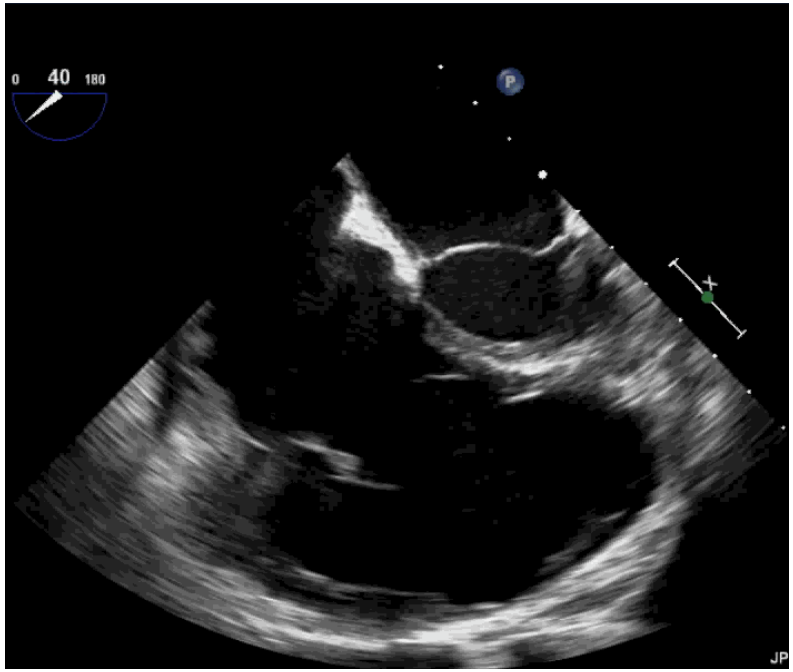

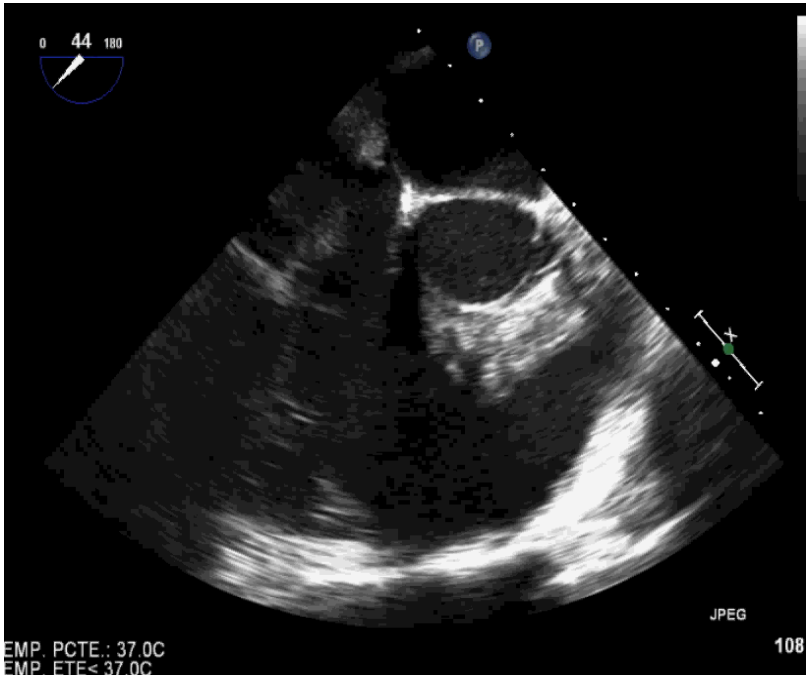

Eco 3D en EI tricúspide

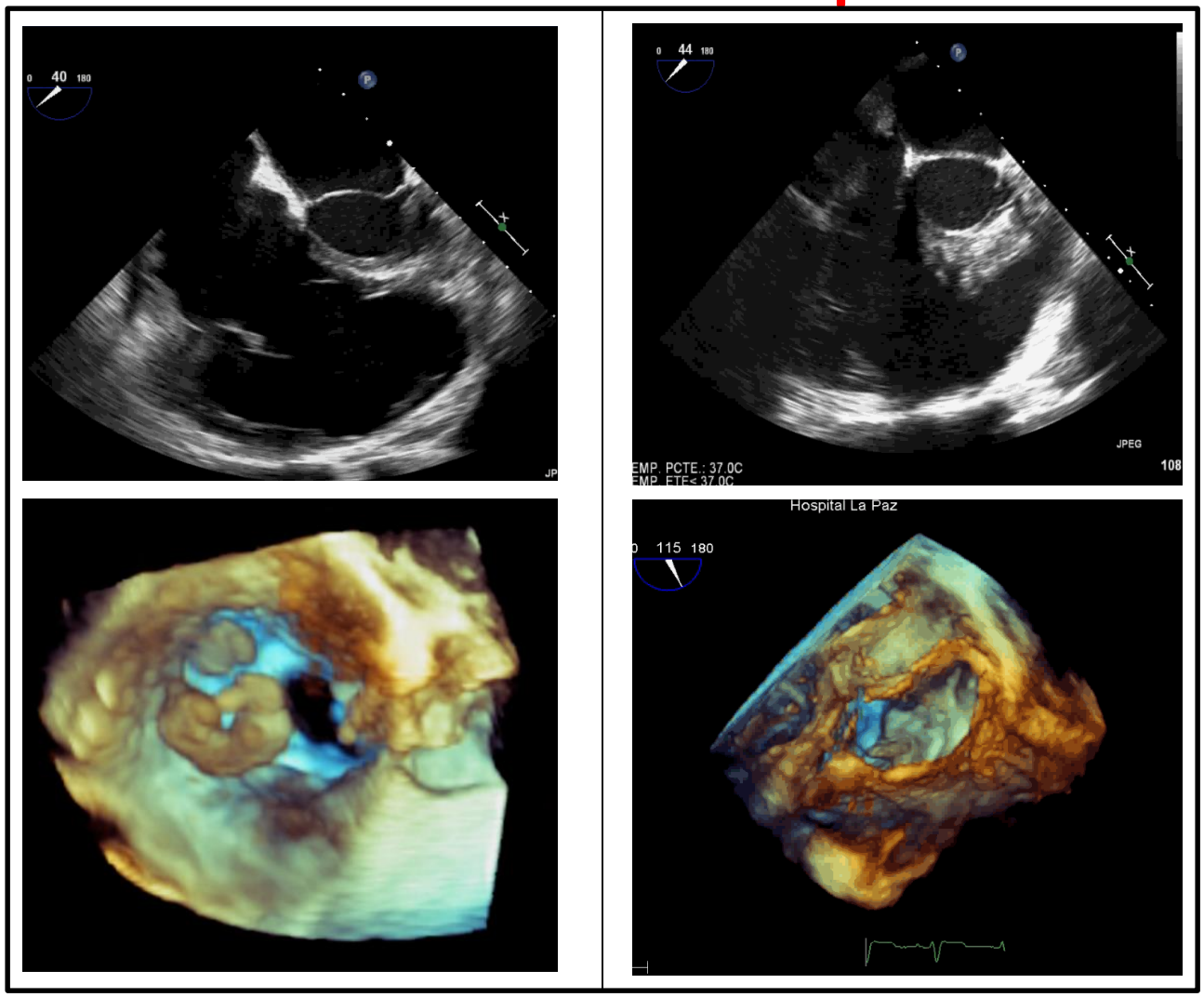

1. Localiza de forma precisa la vegetación
2. Explica las complicaciones de la endocarditis
3. Optimiza la técnica quirúrgica

Eco 3D en Endocarditis Infecciosa

EI derecha

- 60-90% S Aureus
- Otros: Ps aeruginosa, G-, hongos, enterococo, streptococos

Indicaciones QX (IIa (C))

1. Fungemia o bacteriemia >7d con tratamiento
2. Vegetaciones >20mm +TEP
3. IC derecha refractaria

Abordaje quirúrgico:

1. Vegectomía
2. Reparación- Prótesis
3. Valvulectomía sin reemplazo valvular en casos extremos

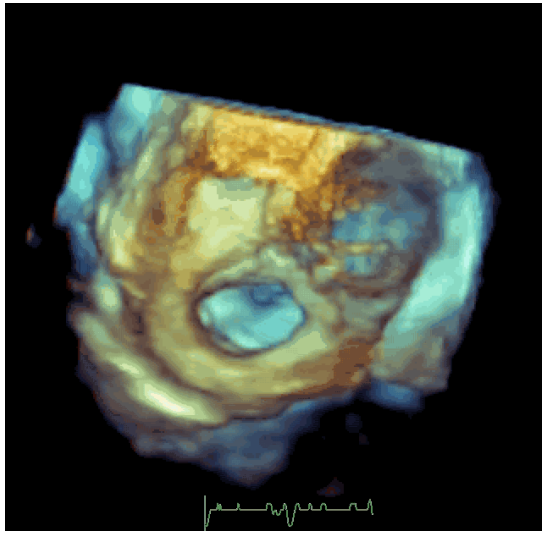

Eco 3D en EI protésica

. Varón de 82 años
. Prótesis mitral biológica
. Ingreso por ICC:
Insuficiencia mitral severa
± febrícula

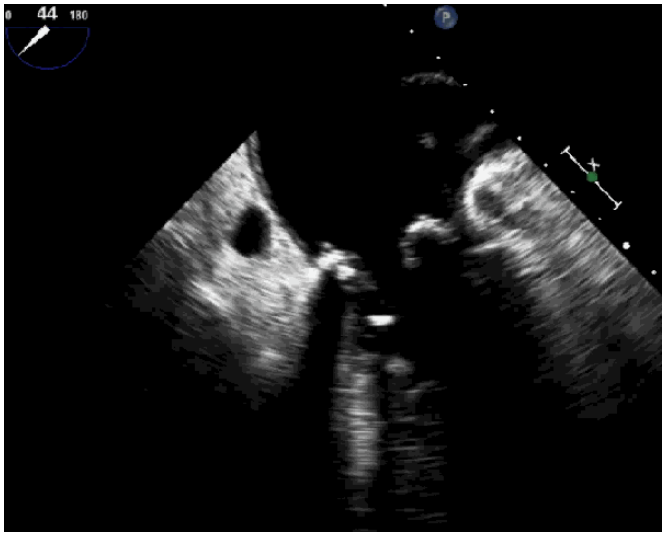

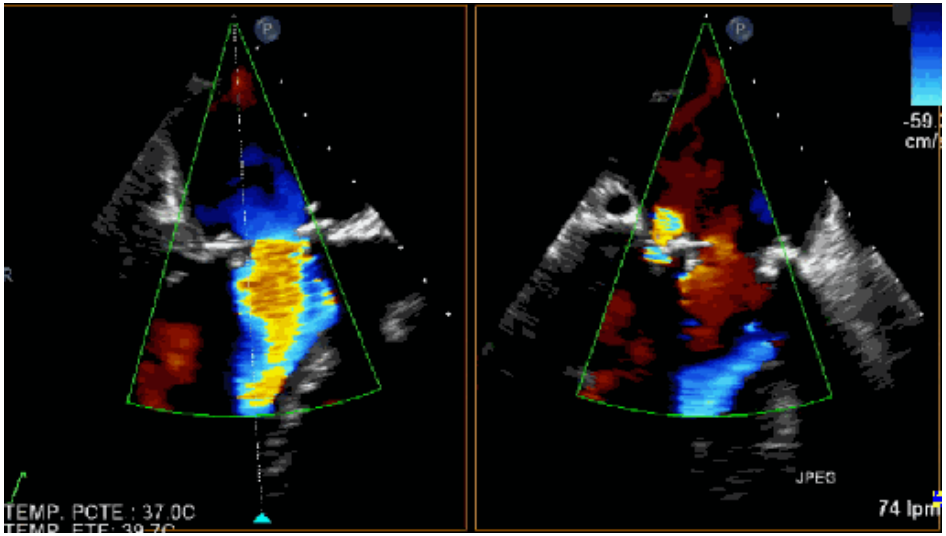

Eco 3D en EI protésica

. Varón de 82 años
. Prótesis mitral biológica
. Ingreso por ICC:
Insuficiencia mitral severa
± febrícula

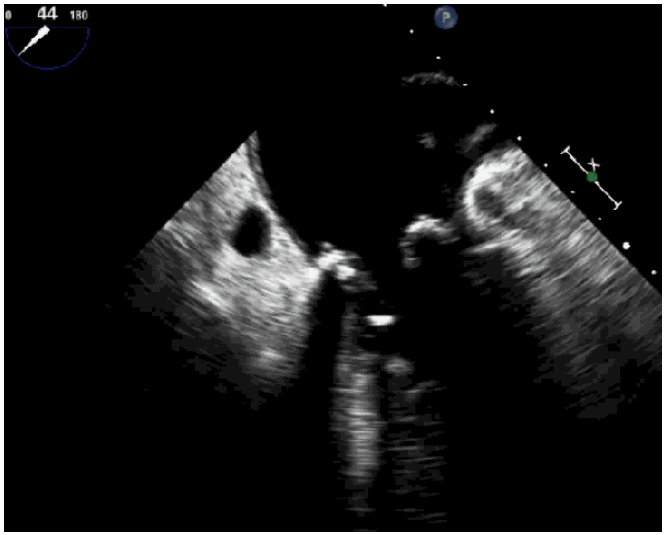

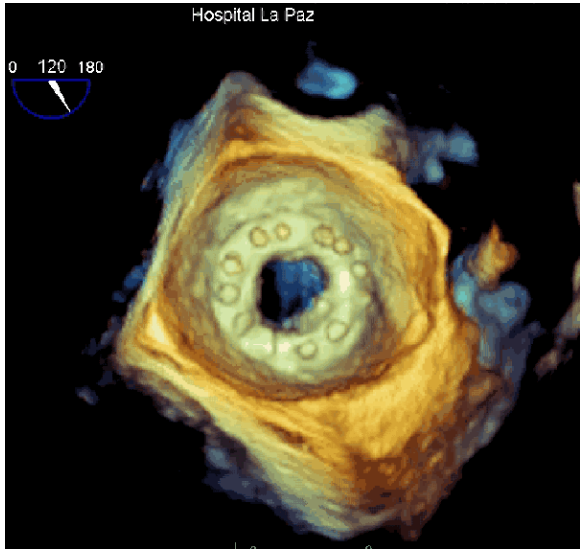

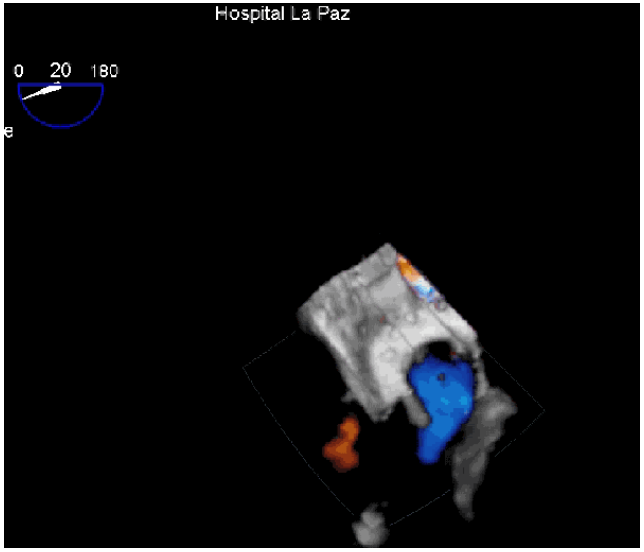

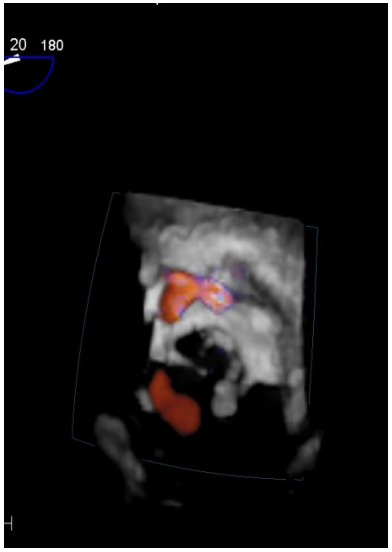

Obtener planos inaccesibles al 2D

Eco 3D en Endocarditis Infecciosa

Endocarditis protésica

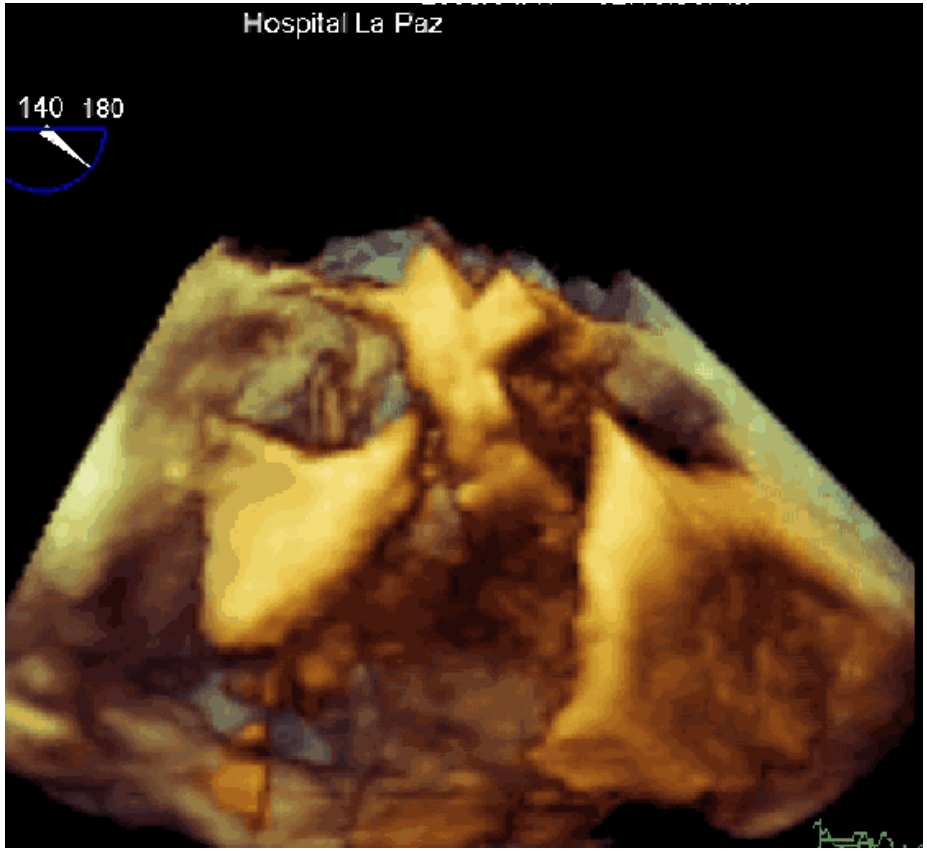

Reduce los artefactos ocasionados por la prótesis

Mejora la sensibilidad de la técnica

Eco 3D en Endocarditis Infecciosa

Endocarditis protésica

Abscesos vs cambios post QX

Paciente 1

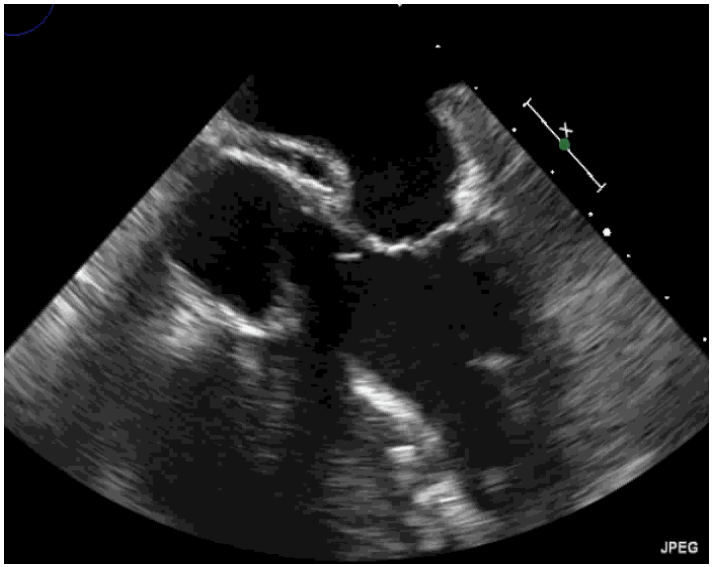

Paciente 2

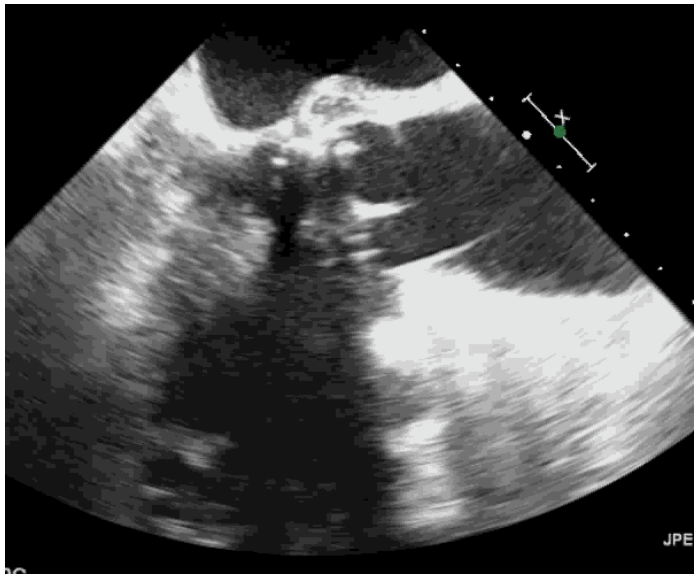

Paciente 1

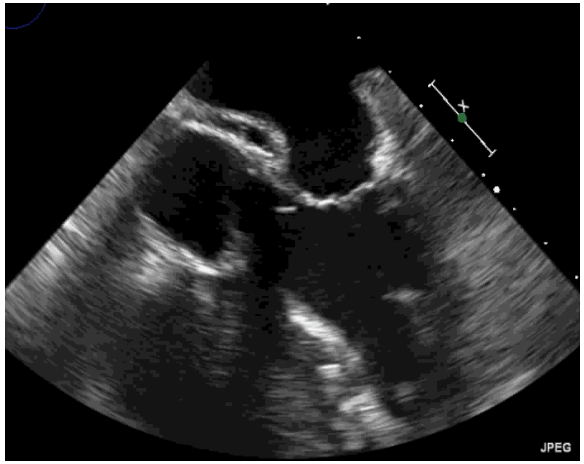

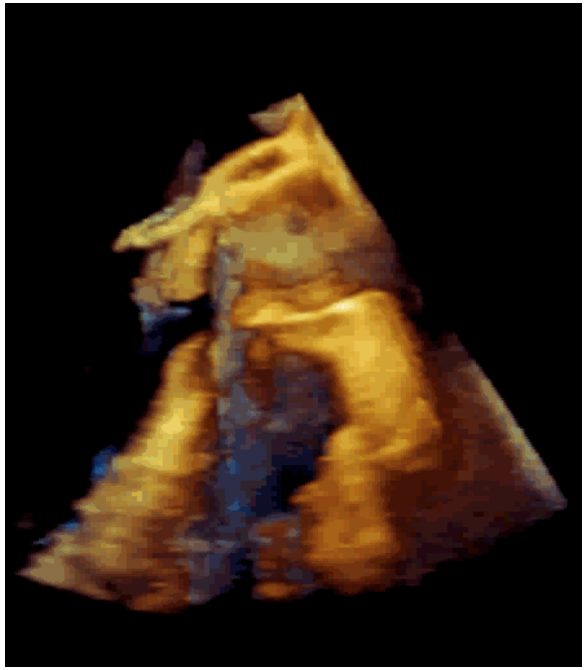

Paciente 2

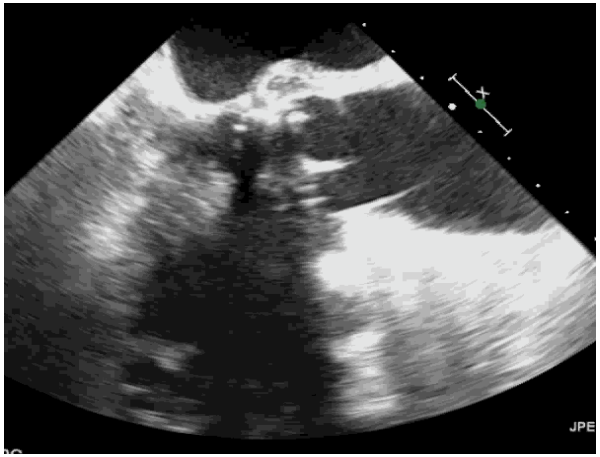

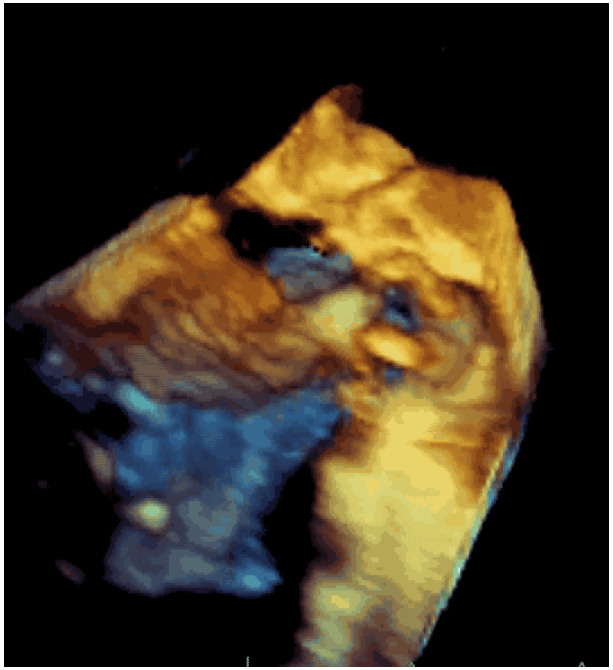

Paciente 1

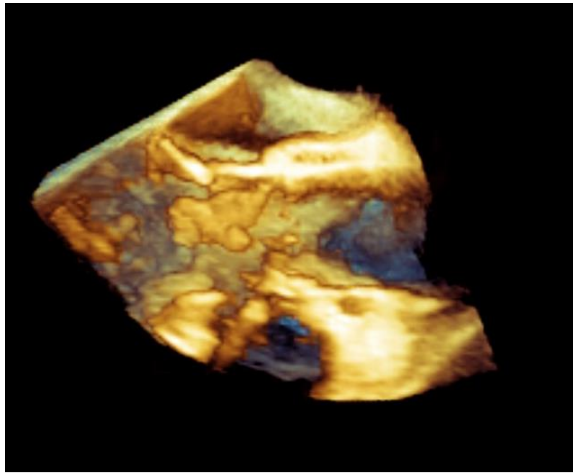

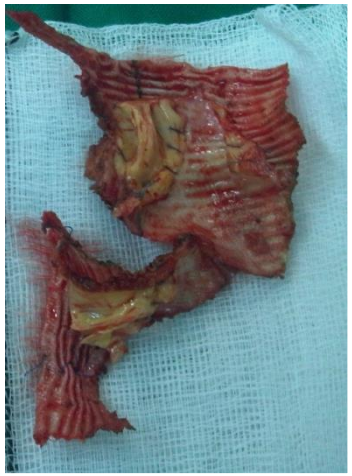

Paciente 2

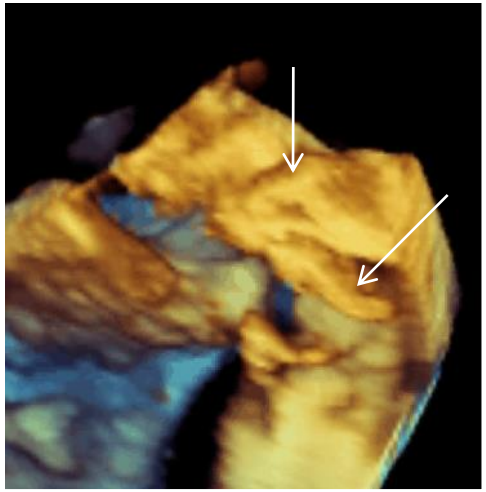

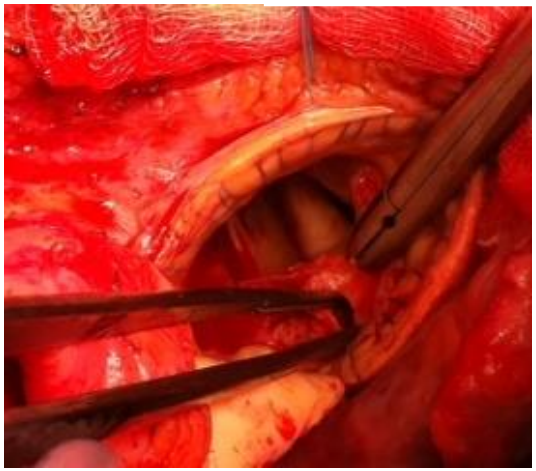

EI protésica

EI prótesis AO

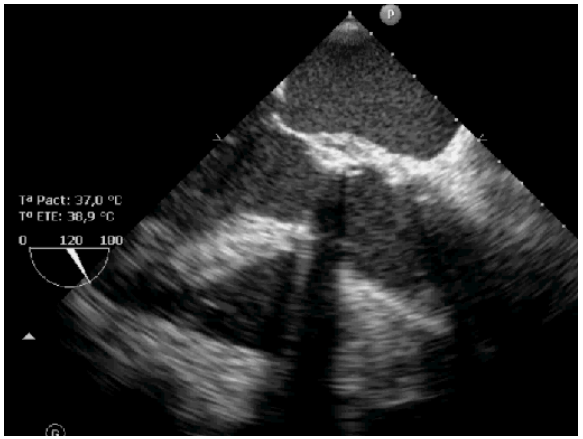

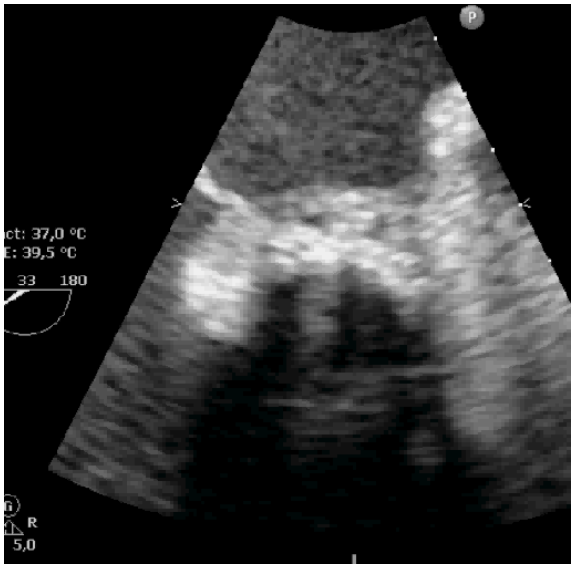

Post operatorio

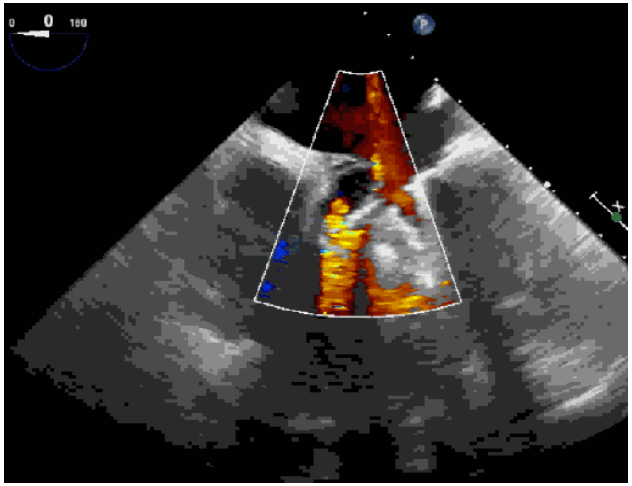

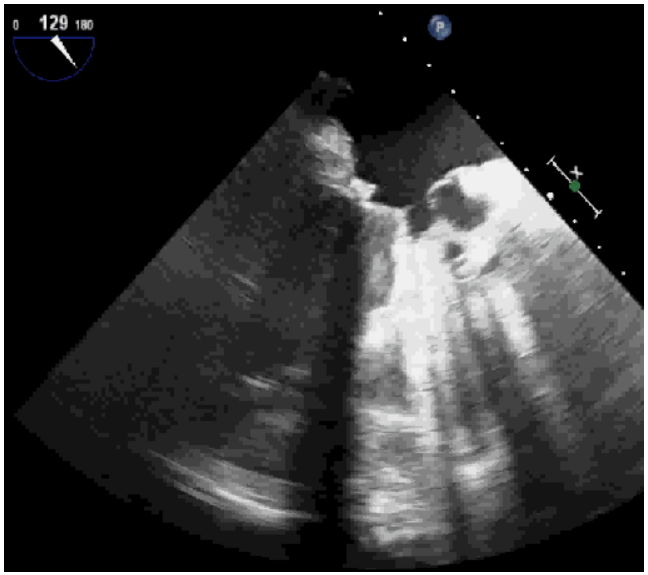

EI protésica: cambios post quirúrgicos

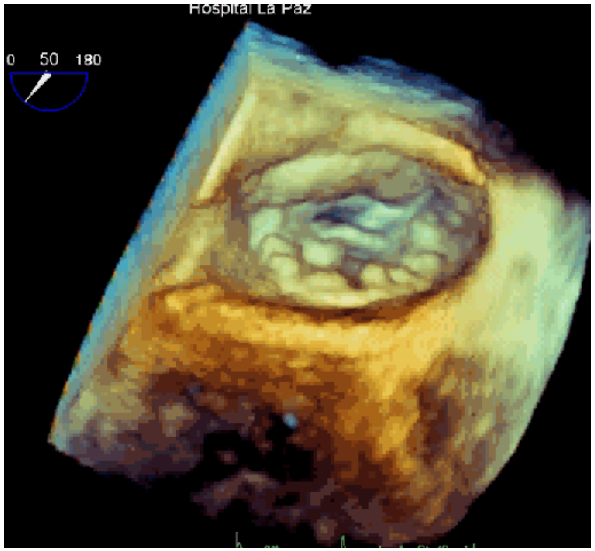

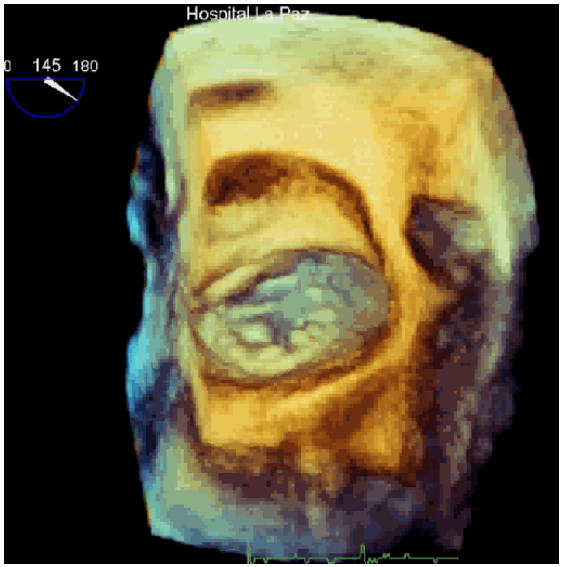

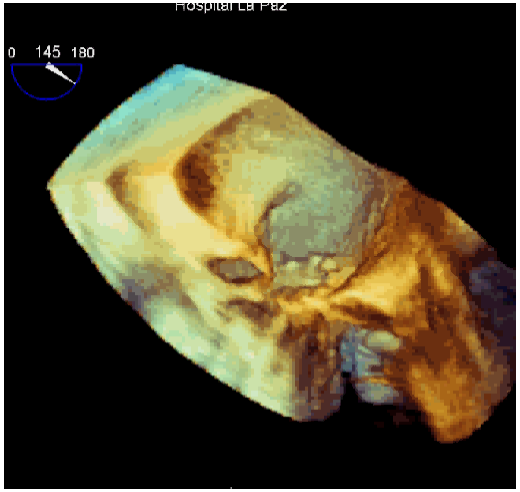

Eco 3D mejora la sensibilidad y especificidad del eco en el Dx de EI asociada a MP/DAI

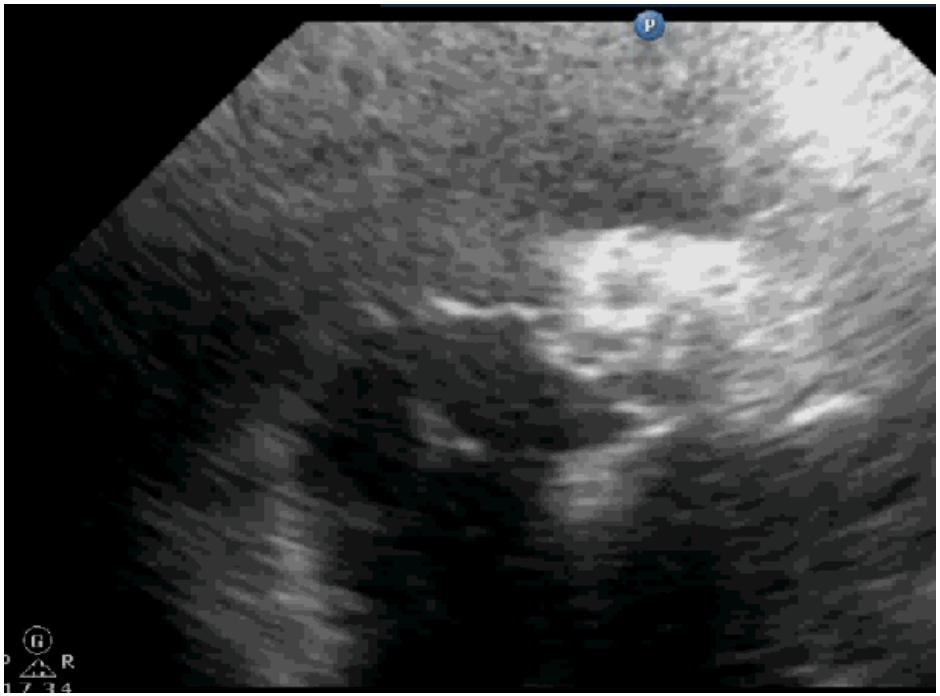

- Varón de 80 años
- EPOC
- Portador de MP
- Fiebre 1 semana sin foco
- Hc negativos

Eco 3D mejora la sensibilidad y especificidad del eco en el Dx de EI asociada a MP/DAI

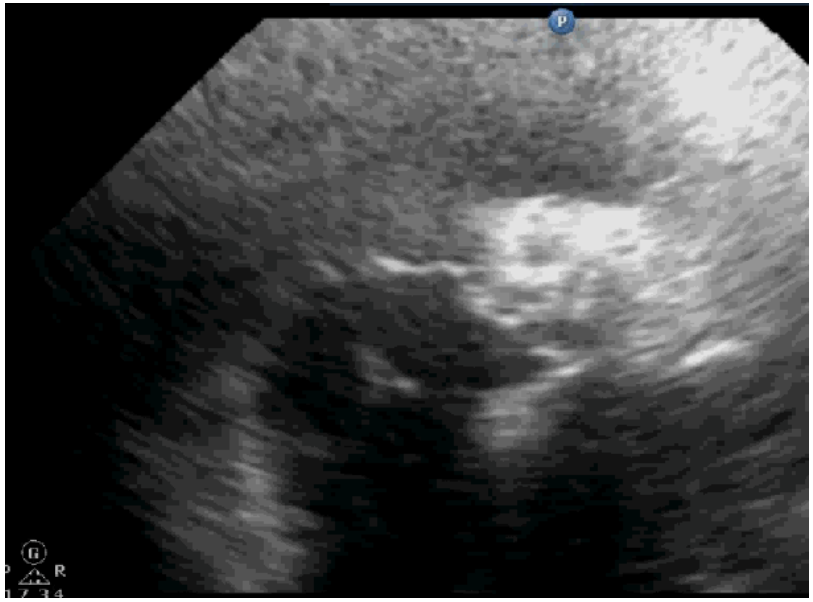

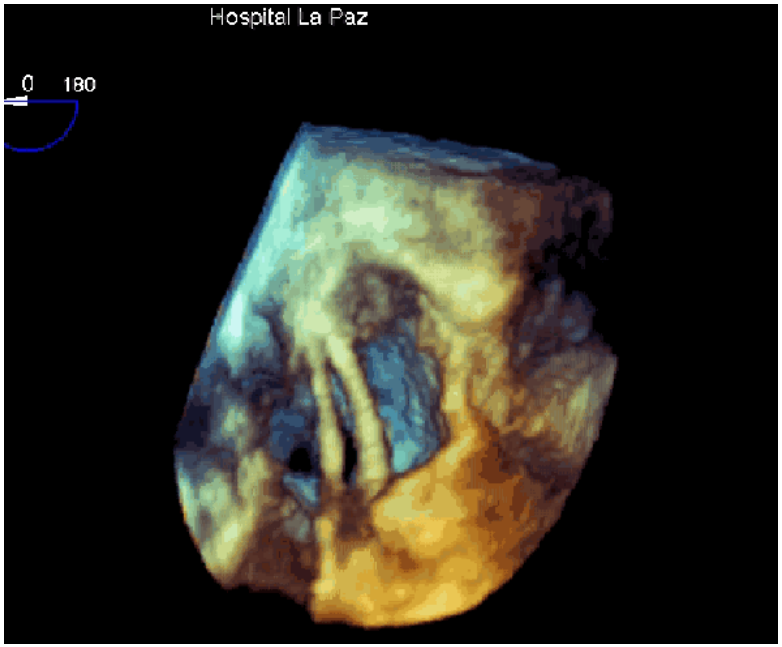

Diagnóstico diferencial de falsas imágenes en cables de marcapasos

Eco 3D en Endocarditis Infecciosa

Dispositivos intracardiacos

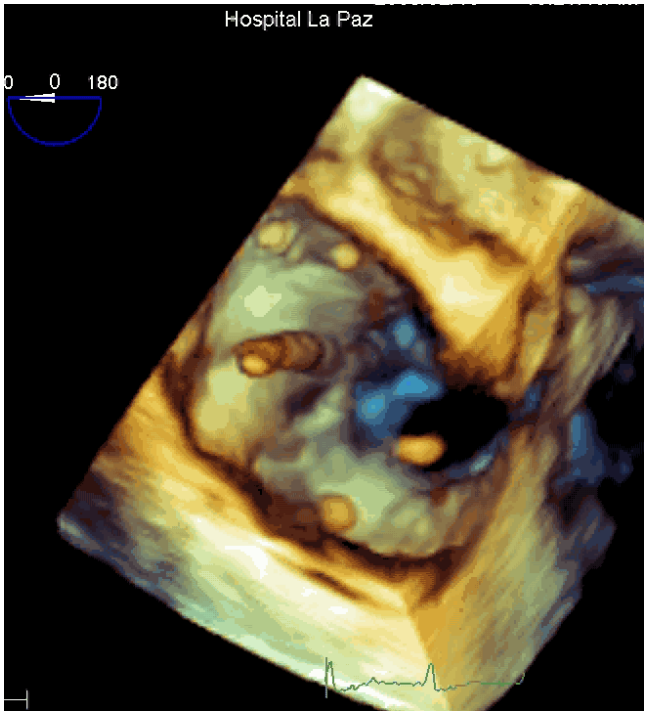

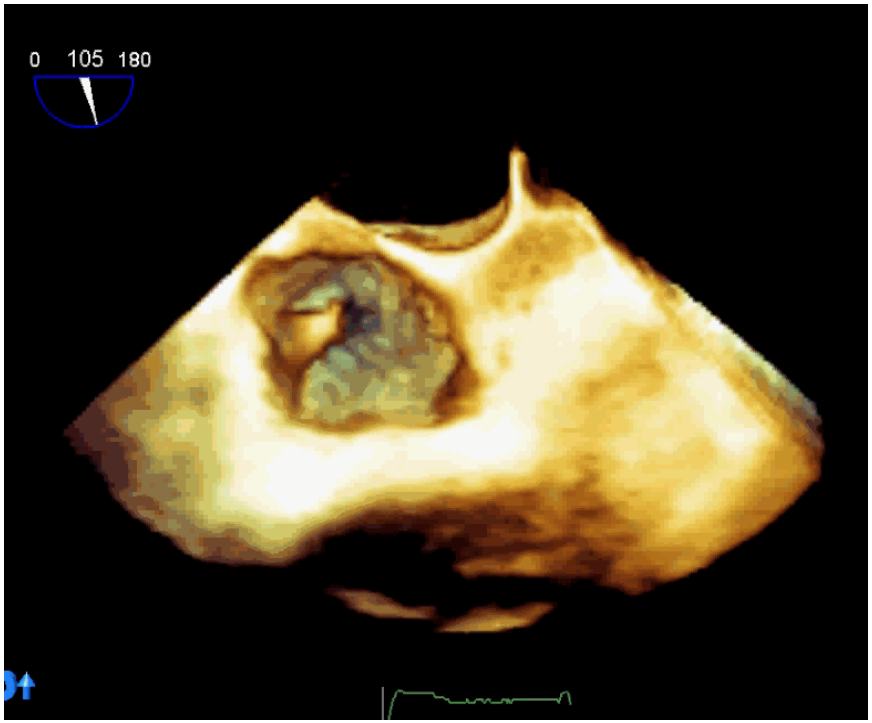

Permite un mejor seguimiento espacial de los cables

Rev Esp Cardiol 2009;62 Supl 3:1-226, pg 5

Valoración ecocardiográfica de EI en dispositivos

EI sobre cable de DAI + infección de la bolsa

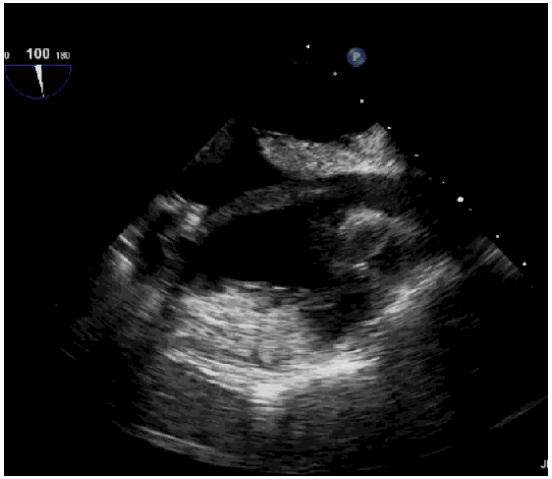

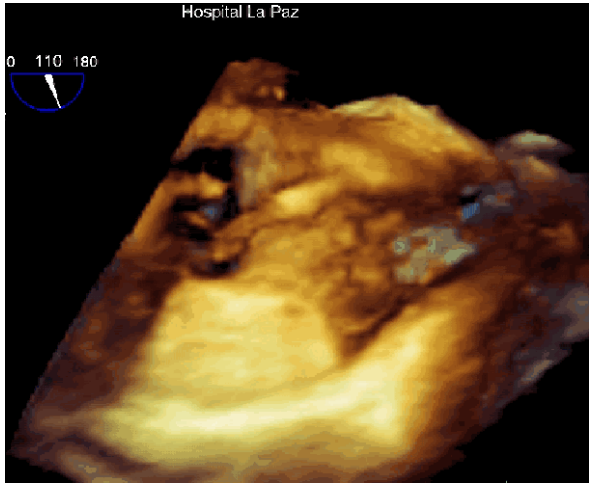

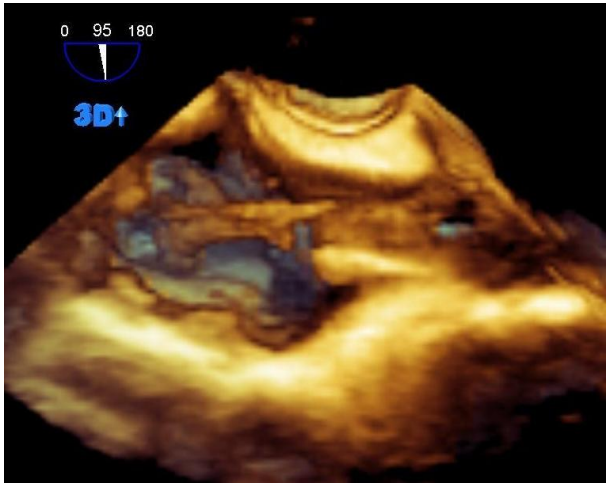

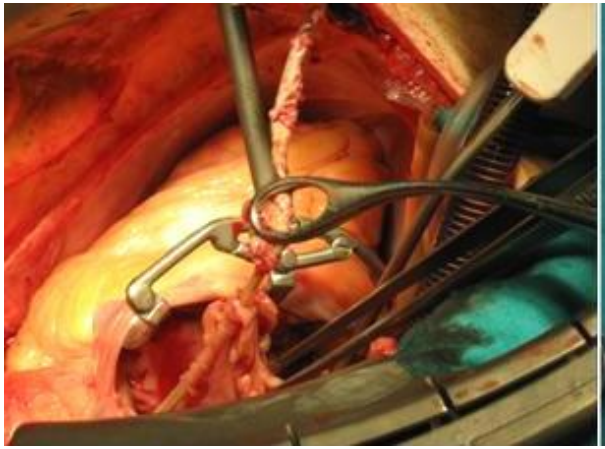

Valoración ecocardiográfica de EI en dispositivos

- Dos grupos:
  - ✓Infección local limitada a la bolsa (calor, erosión, inflamación,, drenaje purulento..)
  - ✓EI relacionada con dispositivos: infección que se extiende a los electrodos, válvulas o endocardio

- 60% con <90d post implante

J Cardiovasc Electrophysiol, 2010: 786-90

- Tratamiento antibiótico prolongado
- Extracción percutánea salvo vegetaciones grandes o destrucción tricúspide asociada
- Considerar recambio en EI izdas
- Reimplante lo mas tarde posible

European Heart Journal 2009: 2369-13

Valoración ecocardiográfica de EI en dispositivos

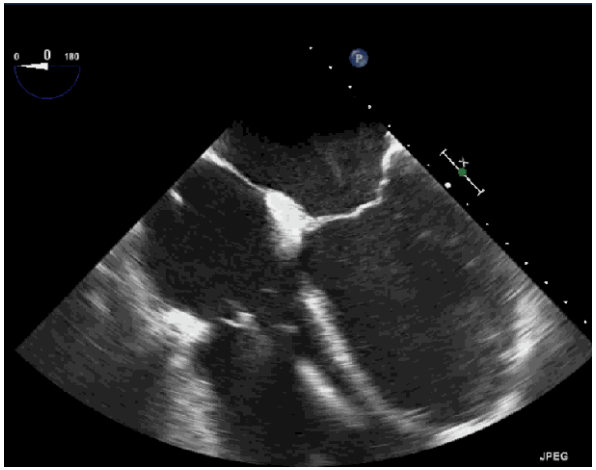

Endocarditis sobre cable MP

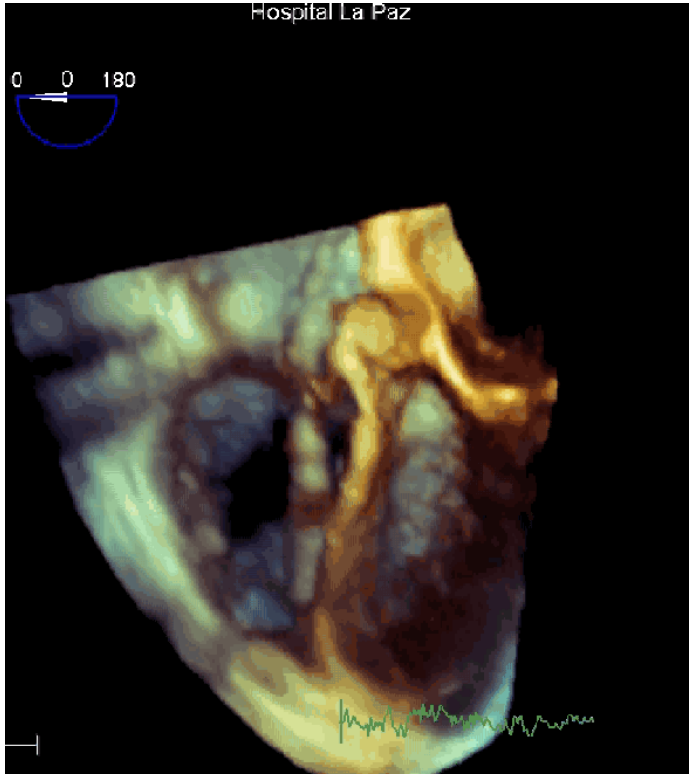

Mejora la sensibilidad diagnóstica

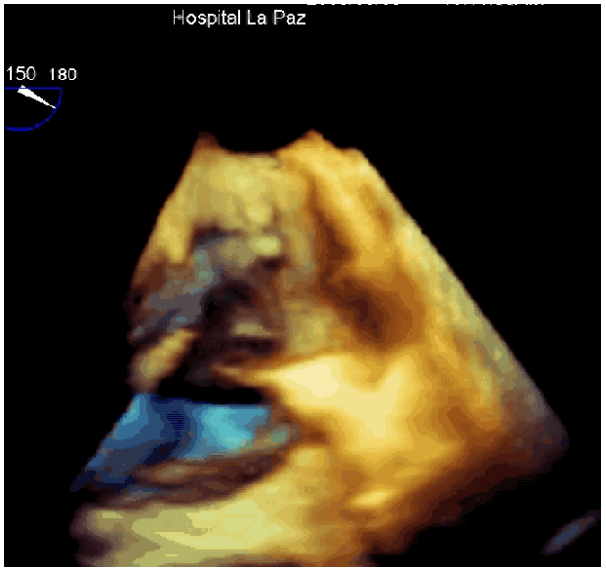

Valoración ecocardiográfica de EI en dispositivos

Vegetaciones y afectación tricúspide

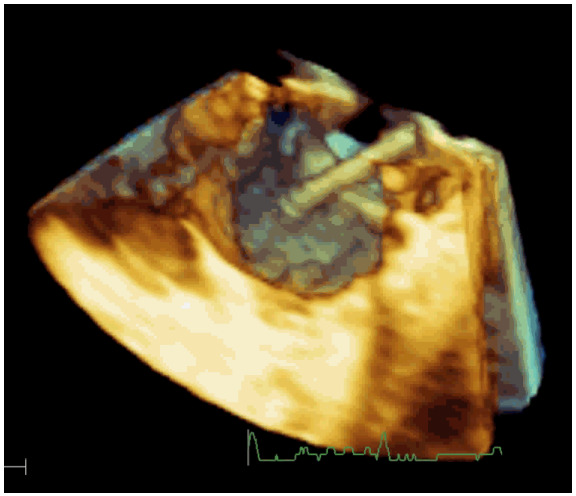

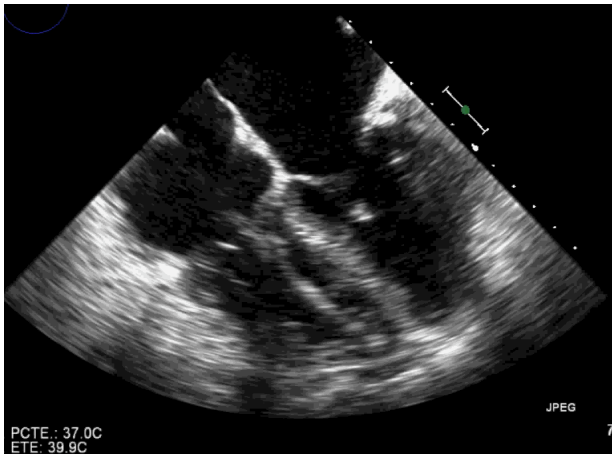

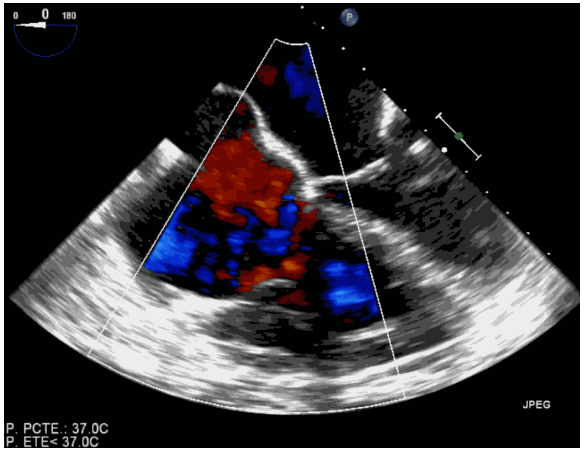

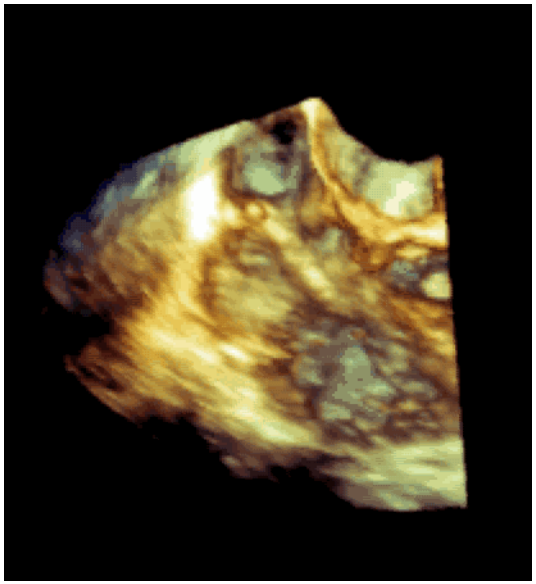

Valoración ecocardiográfica de EI en dispositivos

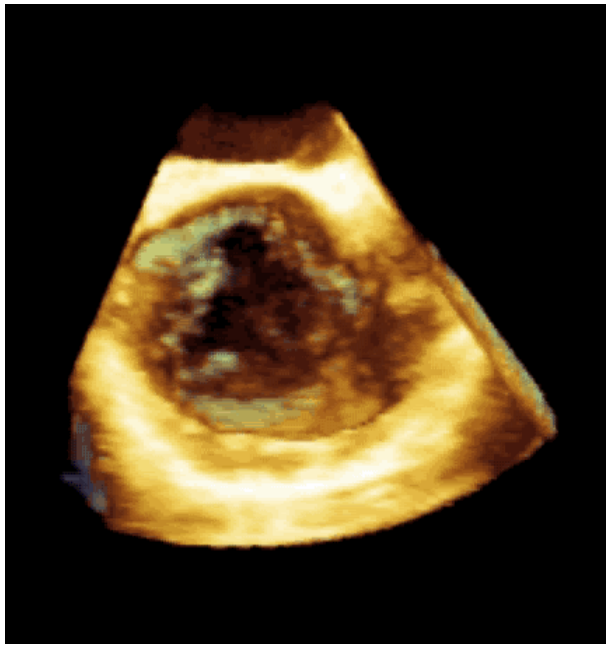

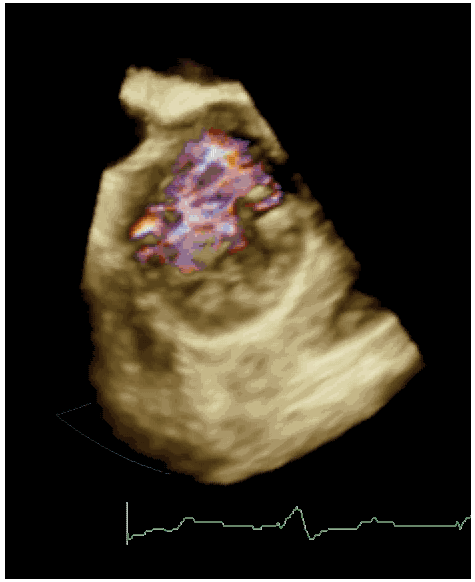

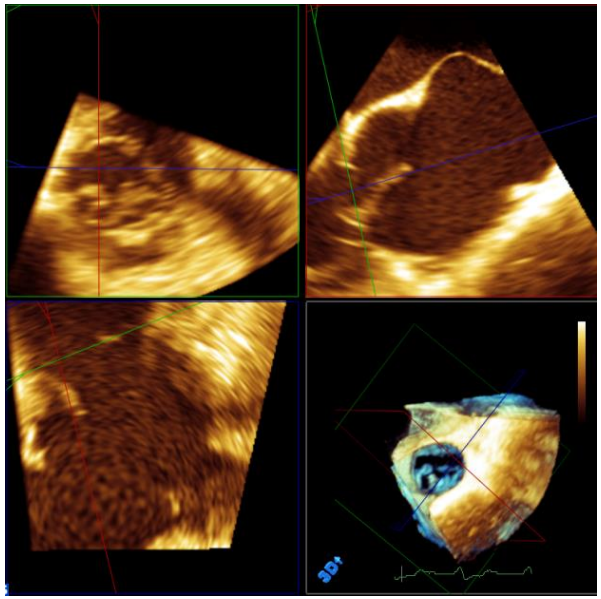

Seguimiento post extracción de MP

Diagnosis of Cardiac Device–Related Infective Endocarditis After Device Removal

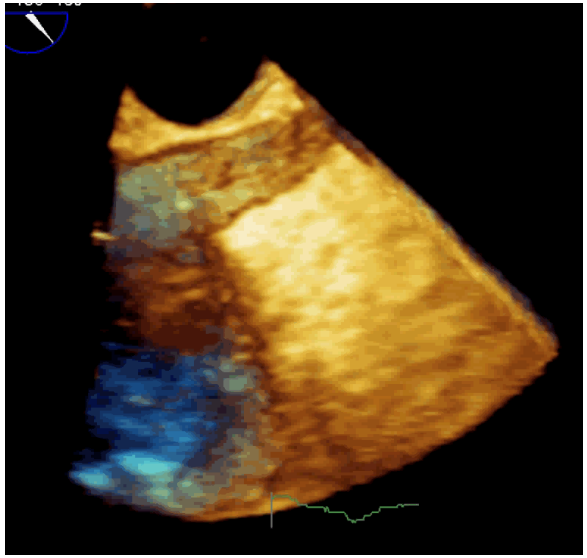

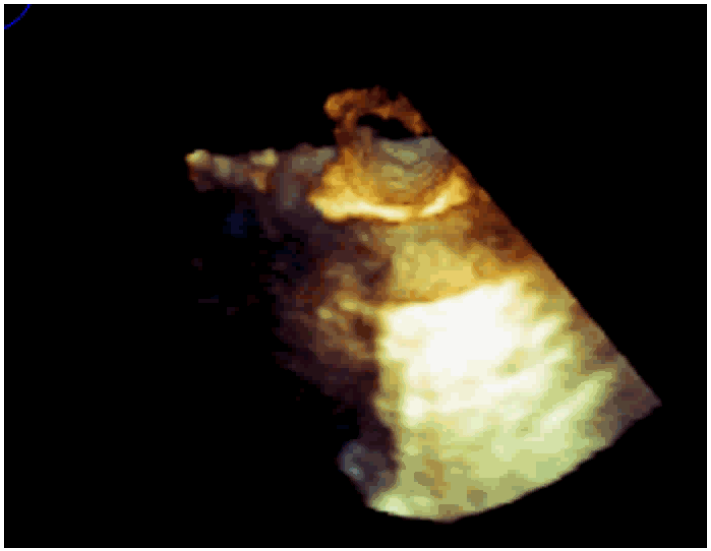

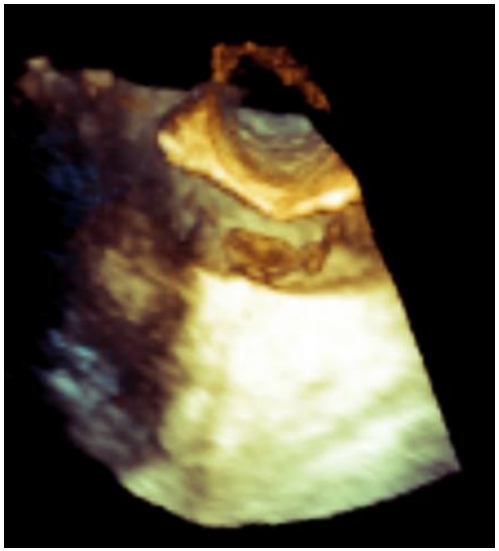

- Los "fantasmas" se observan en un **8% de pacientes**
- Su presencia es sugestiva de infección

J Am Coll Cardiol Img 2010;3: 673–81

Real-Time 3D TEE for the Diagnosis of Right-Sided Endocarditis in Patients With Prosthetic Devices

J. Am. Coll. Cardiol. Img. 2010;3;325-327

Tasneem Z. Naqvi, MD, Reza Rafie, MD, Mohammad Ghalichi, MD

PRECISE ASSESSMENT OF LOCATION OF VEGETATION MAY BE CHALLENGING IN THE PRESENCE OF PACEMAKER and intracardiac defibrillator leads as well as tricuspid annuloplasty ring or bioprosthetic tricuspid valve by transthoracic echocardiography (TTE) and transesophageal echocardiography (TEE), due to reverberation artifact produced by the catheter and prosthetic valve material. Identification of location of the vegetation on the lead versus prosthetic valve has therapeutic implications, particularly in patients with multiple prior cardiac surgeries in whom repeat surgery is not desirable. Cardiac magnetic resonance is currently not a feasible imaging option in patients with prosthetic devices. Real-time 3-dimensional transesophageal echocardiography (RT3D TEE) is able to demonstrate precise relationships among various anatomical structures and is also able to visualize intracardiac catheters, including catheter tip, without artifact associated with TTE and conventional TEE. The utility of RT3D TEE in suspected right-sided endocarditis in patients with pacemaker or intracardiac leads and bioprosthetic tricuspid valve or a tricuspid annuloplasty ring is described in this report. It is to be emphasized that lack of demonstrable vegetations by RT3D TEE may not necessarily imply lack of infection of the device.

RT3D TEE allows evaluation of precise location of vegetation on prosthetic devices such as intracardiac defibrillator (ICD) leads, pacemakers, or tricuspid valve prostheses. Precise delineation of location of vegetation in these patients allows therapeutic medical and surgical treatment decisions. Absence of demonstrable vegetations by RT3D TEE however does not entirely exclude endocarditis, which ultimately remains a clinical diagnosis.

Ecografía 3D en el diagnóstico de EI

1. La ecografía es una herramienta imprescindible para establecer el diagnóstico y orientar el pronóstico y tratamiento de la EI
2. La principal limitación: La sensibilidad y la especificidad de la ecografía no es 100%:
   15% EI no tiene un eco diagnóstico
3. Un estudio negativo no descarta EI: es necesaria una alta sospecha clínica
4. La eco 3D es ecografía…

European Heart Journal (2015) 36, 3075-3123

Eco 3D en Endocarditis Infecciosa

1. Detectar lesiones típicas de EI
2. Limitaciones:
   -Artefactos
   -Resolución temporal
   -Resolución espacial

   → Técnica
   Operador
3. Mejora la valoración anatómica: EI mitral, FMA, Prótesis, MP
4. Reduce los artefactos del material protésico
5. Buena correlación con la anatomía quirúrgica

The Starry Night Vicent van Gogh (1853-1890)