VII CONGRESO SEICAV
Sociedad Española de Infecciones Cardiovasculares
SEVILLA 16 Y 17 DE NOVIEMBRE DE 2018

Grupos de Apoyo al Manejo de la Endocarditis Infecciosa en España
10 Años
Con todo el corazón

Avances en el diagnóstico, nuevos criterios

9:30-9:50

Patricia Muñoz

Microbiología Clínica y Enfermedades Infecciosas
Hospital General Universitario Gregorio Marañón
Instituto de Investigación Sanitaria Gregorio Marañón
Centro de investigación biomédica en red en Enfermedades Respiratorias (CIBERES)
Departamento de Medicina. Universidad Complutense de Madrid. Spain

SaludMadrid
Hospital General Universitario Gregorio Marañón
SaludMadrid Comunidad de Madrid
IGM
ESCMID Collaborative Centre for Observerships
ciberes Centro de Investigación Biomédica en Red Enfermedades Respiratorias
Ministerio de Economía y Competitividad
Instituto de Salud Carlos III

Totalmente multidisciplinar

- **PCR**: Mercedes Marín

- **ETE**: Ana García Mansilla
  Antonia Delgado

- **PET**: Amaia Marí Hualde

- **CT**: Jesús de la Torre

European Heart Journal (2015) 36, 3075–3123
doi:10.1093/eurheartj/ehv319

ESC GUIDELINES

2015 ESC Guidelines for the management of infective endocarditis

The Task Force for the Management of Infective Endocarditis of the European Society of Cardiology (ESC)

Endorsed by: European Association for Cardio-Thoracic Surgery (EACTS), the European Association of Nuclear Medicine (EANM)

- **Immediate access, including TTE, TOE, multislice CT, MRI, and nuclear imaging.**
- **Immediate access to cardiac surgery** should be possible
- **Several specialists should be present on site** (the "Endocarditis Team"), including **at least** cardiac **surgeons, cardiologists, anaesthesiologists**, **ID specialists, microbiologists** and, when available,specialists in **valve diseases, CHD, pacemaker extraction, echocardiography and other cardiac imaging** techniques, **neurologists**, and facilities for **neurosurgery** and interventional **neuroradiology**.

GAMES

4474 ENDOCARDITIS

	Hecho	Positivo (del total de hechos)	Positivo (del total de EI)
Eco transtorácico *	4136 (92.4%)	3357 (81.1%)	75%
Eco transesofágico *	3509 (78.4%)	2855 (81.3%)	63.8%
Estudio abdominal (ECO o TAC)	2466 (55.1%)	939 (38.0%)	20.9%
Estudio craneal (TAC o RMN)	1428 (31.9%)	872 (61.0%)	19.4%
PET **	60 (1.3%)	52 (86.6%)	1.1%
Hemocultivos	4428 (98.9%)	3790 (85.5%)	84.7%
Otros cultivos	2110 (47.1%)	720 (34.1%)	16.0%
Serología	1112 (24.8%)	51 (4.5%)	1.1%
Molecular	934 (20.8%)	686 (73.4%)	15.3%

* Positivo de ETT y ETE basado en presencia de vegetación

** PET-CT no se registra. Depende de cómo se completen los textos libres. Yo intento ir actualizando este dato completandolo cuando lo convierto en querie en los casos más actuales (diría 2017 para acá) ***"Ivan dixit"***

Indice

1. **Microbiología**

2. Imagen

PCR 16S debería estar en los criterios

- 120 operated definite IE

- 16S rRNA
  - **21%:** clarified discrepant culture results or was the only dx method
  - **10%:** influenced antimicrobial therapy.
  - Resolved **56%** of BC negative or culture-negative IE

Clinical Microbiology and Infection (2017), doi: 10.1016/j.cmi.2017.06.008

Unyvero i60 ITI multiplex PCR system

- Comparación con 16S casera en válvulas naturales
  - No detecta *S. viridans* y otros (14 de los 40 casos)
    - **Sensitivity 40%** (modified Duke criteria as gold standard) versus 47.5% for VC and 55% for 16S rRNA
    - The specificity was 100% with both methods
- Tarda 5 horas vs 14 h 16S

De hemocultivos positivos

Técnica		Marcas	Comentarios
FISH		AdvanDX - QuickFISH® Accelerate -Pheno® Test BC	Staph, Enterococo, Candida, G- **30-90 minutos**
PCR	RT-PCR	GeneXpert BD MAX	Caras, dianas limitadas, fáciles (SAMR, SAMS..)
	PCR + array	Luminex Nanosphere VERIGENE® Biofire-Film array® Gen Mark DX- ePlex BCID Curetis Unyvero™ - BCU Sepsis Flow Chip Assay	G+, G-, resistencia. Múltiples dianas. Fácil. Caros. **2,5 h**
	PCR + secuenciación	NGS platforms: Illumina ThermoFisher Oxford Nanopore Paci c Bioscience	Número ilimitado de patógenos Requiere recursos tecnológicos no habituales FUTURO
MALDI-TOF		Brucker BioMerieux	Fácil, barato, rápido. No datos de resistencia todavía
	Hemo incubado 12 h y negativo	Momentum Bioscience – Cognitor® Minus	Aún muy laborioso. VPN **99,5%**

Gentileza de Dra. Ana Uría

Hemo +

A Prospective Evaluation of Two Rapid Phenotypical Antimicrobial Susceptibility Technologies for the Diagnostic Stewardship of Sepsis

MALDI+Alfred 4-6h y más barato.

Nosotros usamos esta combinación

- ALFRED: concordancia con microdilución 95,7% G+, 91% G-.
  - Cada laboratorio puede utilizar los antibióticos más convenientes.
- MALDI: id 100% monomicrobianas

Giordano *et al*, Biomed Research International 2018

De muestra directa

- **Sangre**
  - **Septifast**
  - **SeeGene Magicplex Sepsis**
  - **T2 *Candida* y T2 *Bacteria***
- Muestras **periféricas** (SNC, TRI, TGI)
  - **Filmarray**
  - **GeneXpert**

Gentileza de Dra. Ana Uría

SeeGene Magicplex Sepsis

- Extracción y amplificación de DNA, combinando PCR a tiempo real y endpoint-PCR.
- 73 gram positivos, 12 gram neg, mecA, vanA/B, 6 hongos (90% patógenos)
- La identificación + genes de R: **6 horas**
- **En un estudio de 696 pacientes, S 47%, E 66%, VPP 23%, VPN 87% (valorar Ct)**

Ziegler et al, Plos One 2016

Blood culture-negative IE

Table 1 | **Diagnostic options for blood culture-negative IE**

Technique	Description	Pathogens identified	Limitations
Serology[20,94]	Detection of serum antibodies against specific pathogens may identify causative agents	*C. burnetii**, *Bartonella* spp., *Chlamydophila* spp., *Brucella* spp., *Mycoplasma* spp. and *Legionella pneumophila*	Cross-reactions limit interpretability of *Bartonella* spp. and *Chlamydia* spp.; IE due to *Mycoplasma* spp. and *Legionella pneumophila* are very rare
Histopathology[77,205]	Enhanced examination of resected valves, such as by using special stains (for example, Warthin–Starry stain for *Bartonella* spp. or Periodic acid–Schiff stain for *T. whipplei*)	Streptococci, staphylococci, *Bartonella* spp., *T. whipplei*, *C. burnetii* and fungi	Requires an experienced microbiologist
PCR[20,205,206]	Amplification of 16S ribosomal DNA for bacteria or 18S ribosomal DNA for fungi, which can then be sequenced for pathogen identification	Streptococci, staphylococci, *Bartonella* spp., *T. whipplei* and *C. burnetii*	Low sensitivity on blood samples and requires cardiac valve tissue
Immunohistology[205]	Specific monoclonal or polyclonal antibodies may enable antigen detection in valve tissue	*Bartonella* spp., *T. whipplei* and *C. burnetii*	Unknown sensitivity and specificity, and use is limited to specialized laboratories
Autoimmuno-histochemistry[207]	Uses a peroxidase-based method with the patient's own serum as a source of antibodies against specific pathogens in valve-tissue specimens	*Bartonella* spp., *T. whipplei* and *C. burnetii*	Reported in a single publication from a specialized laboratory
Metagenomic analysis[208]	DNA is extracted from the resected valve and then next-generation sequencing is used to identify bacterial genome fragments	Case reports for *Enterococcus faecalis*, *Streptococcus mutans* and *Streptococcus sanguinis*; in theory, could identify a broad range of bacteria, fungi and viruses	Reported in a limited number of studies thus far; should be considered exploratory only
Host gene signatures[209,210]	Analysis of host inflammatory response, which may be unique for specific pathogens	*Staphylococcus aureus*	Technique in development and has not been used to make a clinical IE diagnosis

C. burnetii, *Coxiella burnetii*; IE, infective endocarditis; *T. whipplei*, *Tropheryma whipplei*. *Serology for *C. burnetii* is included in the modified Duke criteria.

Holland et al. Nature Reviews 2016

Criterios y métodos diagnósticos de infección de dispositivos intracardíacos

4 escenarios clínicos

1. lead **thrombus or vegetation** on echocardiography
2. **local inflammatory changes** at the **generator pocket site** (erythema,swelling, pain, discomfort, drainage, or erosion of the generator and/or leads through the skin);
3. **fever** and no local changes at the generator pocket site;
4. **bacteremia** and no local changes at the generator pocket site

DeSimone DC. J Clin Microbiol 2018 Volume 56 Issue 7 e01683-17

Cardiovascular implantable electronic devices infection

Criterios Clínica MAYO

CIED infection classification criteria

1. Definite CIED infection: combination of any 2 major clinical findings or 1 or more pocket findings.
2. Probable CIED infection: 1 major clinical finding and 1 or more minor clinical findings.
3. Possible CIED infection: suspected CIED infection case that does not meet "Definite" or "Probable" criteria.

Proposed Mayo CIED infection classification criteria

Pocket findings

1. Physical exam: device erosion through skin, purulence emanating from pocket, fluctuance, or sinus tract.
2. Intraoperative findings: purulence within the generator pocket site.
3. Cultures: positive cultures (significant microbial growth, i.e., tissue and swab sample growth when colonies grow on ł2 quadrants of the culture plate and device sonication sample growth when ł20 colonies are isolated from 10 ml of sonicate fluid [10]) from explanted CIED.

DeSimone DC. J Clin Microbiol 2018 Volume 56 Issue 7 e01683-17

SaludMadrid
Comunidad de Madrid

Clinical findings

Major

1. Two or more positive blood cultures for organisms typical of CIED infection, such as *S. aureus*, coagulase-negative staphylococci (CoNS), or enterococci, with no alternative source.
2. TEE findings consistent with vegetation on the device lead and/or heart valve.
3. Positron emission tomography-computed tomography (PET-CT) imaging consistent with device infection.

Minor

1. Prolonged bacteremia (>72 h) with microorganisms other than listed in major criteria.
2. TEE findings not meeting major criteria.
3. Recent pocket manipulation (<3 months prior to presentation).
4. Fever (38°C or higher).
5. Embolic phenomena (typically septic pulmonary emboli from lead vegetations or right-sided endocarditis).
6. Pocket erythema or tenderness.

DeSimone DC. J Clin Microbiol 2018 Volume 56 Issue 7 e01683-17

J Antimicrob Chemother 2015; **70**: 325–359
doi:10.1093/jac/dku383 Advance Access publication 29 October 2014

Journal of Antimicrobial Chemotherapy

Guidelines for the diagnosis, prevention and management of implantable cardiac electronic device infection. Report of a joint Working Party project on behalf of the British Society for Antimicrobial Chemotherapy (BSAC, host organization), British Heart Rhythm Society (BHRS), British Cardiovascular Society (BCS), British Heart Valve Society (BHVS) and British Society for Echocardiography (BSE)

Jonathan A. T. Sandoe[1]*, Gavin Barlow[2], John B. Chambers[3], Michael Gammage[4], Achyut Guleri[5], Philip Howard[1], Ewan Olson[6], John D. Perry[7], Bernard D. Prendergast[8], Michael J. Spry[9], Richard P. Steeds[10], Muzahir H. Tayebjee[1] and Richard Watkin[11]

- Interpretación cuidadosa de resultados en función del contexto clínico
- PCR's si cultivo NEGATIVO.
- Más estudios para establecer el papel de la sonicación

Muestras A ENVIAR:
Hemocultivos (antes y después de retirar el dispositivo)
Cables: distal y proximal
Vegetaciones
Tejido y exudado del bolsillo del generador
Generador

AMERICAN SOCIETY FOR MICROBIOLOGY Journal of Clinical Microbiology®

MINIREVIEW

Approach to Diagnosis of Cardiovascular Implantable-Electronic-Device Infection

Daniel C. DeSimone,[a,b] M. Rizwan Sohail[a,b]

Intraoperative

1. Swab samples from the device.
   - Send to microbiology laboratory for Gram staining, bacterial cultures, and susceptibility testing.
   - If suspected, consider fungal and mycobacterial cultures, including fungal and acid-fast bacillus (AFB) smears.
2. Generator pocket tissue samples for culture and susceptibility testing.
3. Device sonication.
   - Place extracted device into a sterile jar/container with 50 to 100 ml of sterile saline and seal before submitting to microbiology laboratory.

DeSimone DC. J Clin Microbiol 2018 Volume 56 Issue 7 e01683-17

Diagnóstico infección DIC retirado

- **Punta de cables mejor que tejido** ***(92'5% vs 59%,*** *Golzio PG. PACE 2009)*

- **Tejido del bolsillo mejor que torunda del bolsillo peri generador** ***(69% vs 31%,*** *Chua JD. PACE 2005)*

- **Sonicación**: aumenta algo la sensibilidad respecto a tejido
  Posibles "Falsos positivos"

- **Molecular**: Poca información

Indice

1. Microbiología

2. Imagen
- ETT, ETE
- Imagen abdominal y del SNC
- PET-TC
- SPECT con leucocitos marcados
- Angio-TC sincronizado con ECG
- RMN
- Otros

Criterios diagnósticos de imagen

2. Imaging positive for IE

a. Echocardiogram positive for IE:
- Vegetation;
- Abscess, pseudoaneurysm, intracardiac fistula;
- Valvular perforation or aneurysm;
- New partial dehiscence of prosthetic valve.

b. Abnormal activity around the site of prosthetic valve implantation detected by ^{18}F-FDG PET/CT (only if the prosthesis was implanted for >3 months) or radiolabelled leukocytes SPECT/CT.

c. Definite paravalvular lesions by cardiac CT.

Se incluyen 3 puntos nuevos en los criterios:

(1)En caso de EI sobre válvula **protésica**, la actividad anormal por **PET o SPECT** alrededor del sitio de captación (si la protésis se implantó hace > de 3 meses) debe ser considerado un **criterio mayor**.

(2)La identificación de lesiones **paravalvulares** por **TC cardiaco** debe considerarse un **criterio mayor**.

(3) La identificación del **embolismos periféricos** por las técnicas de imagen (silentes) debe considerarse un **criterio menor**.

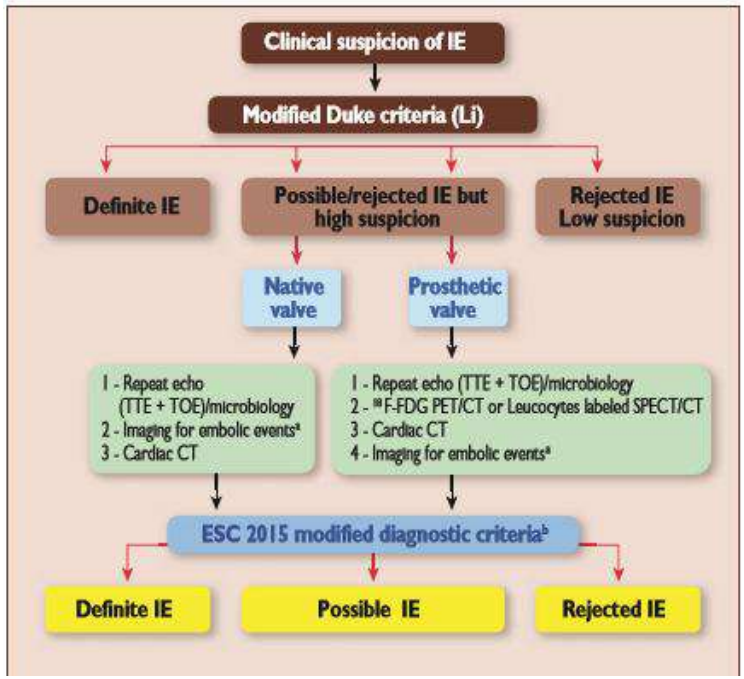

Ecocardiograma

- La ecocardiografía **es la base del diagnóstico** de EI por imagen.
  - Buen rendimiento en endocarditis sobre válvula nativa.
  - Limitaciones:
    - Precisa q ya haya alteración anatómica/hemodinámica.
    - Prótesis intracardiacas **ETT S 40-70%,** E 90, **ETE S 77-90%,** E 90
    - Intolerancia o contraindicaciones para realización de ecocardiograma transesofágico.

Prognostic implications of a negative echocardiography in patients with infective endocarditis☆,☆☆

Lourdes Vicent[a], Hugo González Saldivar[a], Emilio Bouza[b], Patricia Muñoz[b], Gregorio Cuerpo[c], Aristides de Alarcón[d], Bárbara Vidal[e], Manuel Cobo[f], Miguel Ángel Goenaga[g], Fernando Carrasco-Chinchilla[h], Miguel Montejo[i], Juan Gálvez-Acebal[j], Carmen Hidalgo-Tenorio[k], David Vinuesa-García[l], Manuel Martínez-Sellés[a,m,*], on behalf of the GAMES investigators

- 3467 pts (2765 definite IE, 702 possible IE)
  - **Negative TEE 674 (19.4%);** 14% definite; 41% possible
- Positive TEE: more complications (cardiac and extracardiac)
  - definite IE 35.5% vs. 16.8%, $p < 0.001$
  - possible IE 20.8% vs. 7.6%, $p < 0.001$

Positive echocardiography was a predictor of in hospital death by logistic regression modelling,

-definite IE (OR 1.3, p=0.036)
-possible IE (OR 1.6, p=0.036)

Vicent L., European Journal of Internal Medicine (2018)
https://doi.org/10.1016/j.ejim.2018.01.033

Contribution of echocardiography in the diagnosis of definitive infective endocarditis: the infectious disease specialist's point of view

B. Davido[1] · A. Moussiegt[1] · A. Dinh[1] · O. Senard[1] · L. Deconinck[1] · O. Auzel[2] · X. Repesse[3] · M. Sirol[4] · M. Morgan[1] · J. Salomon[1]

- TEE plays a major role in the Dx of IE: before echo only 37.2% classified as definitive IE

- 19.8% of the IE normal echocardiography.
  - Less surgery needed
  - Same embolisms and mortality

Eur J Clin Microbiol Infect Dis 2018
DOI 10.1007/s10096-017-3064-y

Observational Study

Medicine

OPEN

Detection of spleen, kidney and liver infarcts by abdominal computed tomography does not affect the outcome in patients with left-side infective endocarditis

José A. Parra, MD, PhD[a,*], Luis Hernández, MD[b], Patricia Muñoz, MD, PhD[c], Gerardo Blanco, MD[d], Regino Rodríguez-Álvarez, MD[e], Daniel Romeu Vilar, MD[f], Arístides de Alarcón, MD[g], Miguel Angel Goenaga, MD[h], Mar Moreno, MD[i], María Carmen Fariñas, MD, PhD[j,*], on behalf of the Spanish Collaboration on Endocarditis-Grupo de Apoyo al Manejo de la Endocarditis Infecciosa en España (GAMES)

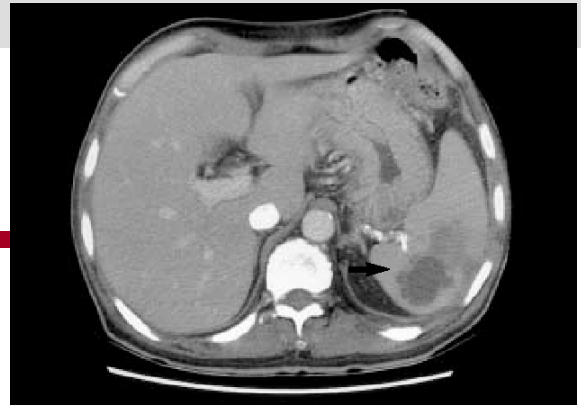

- 147 patients with LS-IE had abdominal CT
  - Fifty (**34%**) CT +: 46 splenic, 15 renal, 1 liver infarct, and 2 liver abscesses.
  - **RF: Male** patients with **native** LS-IE who had **liver disease** and **nonabdominal emboli**
  - No difference in site of acquisition, clinical characteristics, microbiology, surgical treatment, days of treatment!!, hospitalization, hospital death, and 1-year mortality.
- **Indicated only when signs or symptoms**

Medicine (2018) 97:33(e11952)

Utility of Brain Magnetic Resonance Imaging in the Surgical Management of Infective Endocarditis

Tia Chakraborty, MD,* Eugene Scharf, MD,† Alejandro A. Rabinstein, MD,† Daniel DeSimone, MD,‡ Abdelghani El Rafei, MD,‡ Waleed Brinjikji, MD,§ Larry M. Baddour, MD,‡‖ Eelco Wijdicks, MD, PhD,* Walter Wilson, MD,‡ James M. Steckelberg, MD,‡ and Jennifer E. Fugate, DO*

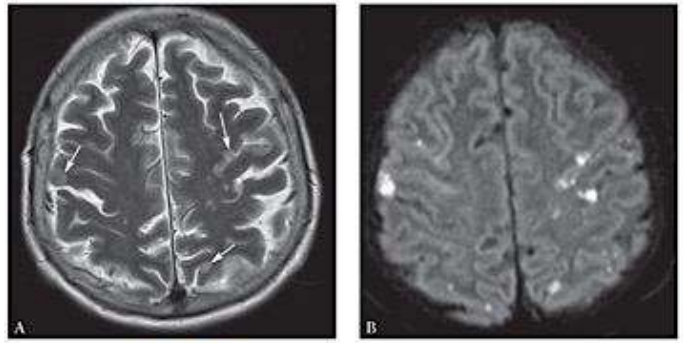

FIGURE 34.3 Brain MRI of a patient with *Staphylococcus aureus* endocarditis: weighted imaging (DWI) (B), and T1 sequence postcontrast (C) showing multip with an abscess in the right central region *(arrowhead)*.

- 95 (48.7%) of operated IE underwent preoperative MRI (symptoms 58.9%)
  - Postoperative neurologic complications 24 of 195 (**12.3%**) patients
    - **No difference with and without preoperative MRI or with MRI findings**.

- **In patients undergoing valve replacement surgery, preoperative MRI findings were not associated with differences in postoperative**

J Stroke Cerebrovasc Dis. 2017 Nov;26(11):2527-2535

Radiología nuclear

PET-TC ^{18}FDG

PET/TC-^{18}FDG

Emplea radiotrazadores para la detección de áreas de captación.

PET (imagen gammagráfica)

-Emplea como radiotrazador 18FDG, análogo de la glucosa.

-Marca tejidos con alta demanda metabólica.

-Medición semicuantitativa de la acumulación de radiotrazador (**SUV**).

-Tiempos de detección: **1-3 horas**.

TC:

-Topograma.

-**Su potencia es variable según los centros**.

Modifica el abordaje terapéutico en un 15-35% de pacientes

ESCASA SENSIBILIDAD EN VALVULA NATURAL (6-14%)

Gentileza Dr. Juan Carlos López-Azor García

Van Riet et al. Eur J Nucl Med Mol Imaging 2010; .Kouijizer et al. Eur J Nucl Med Mol Imaging 2013 ; Ozcan et al. Int J Cardiovasc Imaging 2013; Asmar et al. Eur Heart J Cardiovasc Imaging 2014; Orvin et al. Clin Microbiol Infect 2015

Molecular Imaging for the diagnosis of infective endocarditis: A systematic literature review and meta-analysis☆

Daniel Juneau [a,d], Mohammad Golfam [b], Samir Hazra [a], Fernanda Erthal [a], Lionel S. Zuckier [b], Jordan Bernick [a], George A. Wells [a], Rob S.B. Beanlands [a,c], Benjamin J.W. Chow [a,c,*]

- **18F-FDG** (with adequate cardiac preparation) for the diagnosis of IE
  - **Pooled sensitivity 81%** (95% CI, 73%–86%); pooled specificity **85%** (95% CI, 78%–91%): AUC 0.897
- **WBC** for the diagnosis of IE
  - **Pooled sensitivity 86%** (95% CI, 77%–92%); pooled specificity **97%** (95% CI, 92%–99%). AUC 0.957

Int J Cardiol (2017), https://doi.org/10.1016/j.ijcard.2017.10.116

Meta-analysis of 18F-FDG PET/CT in the diagnosis of infective endocarditis

Maryam Mahmood, MbChB,[a] Ayse Tuba Kendi, MD,[b] Saira Ajmal, MD,[a] Saira Farid, MD,[a] John C. O'Horo, MD, MPH,[a,c] Panithaya Chareonthaitawee, MD,[d] Larry M. Baddour, MD,[a,d] and M. Rizwan Sohail, MD[a,d]

- **18F-FDG** (with adequate cardiac preparation) for the diagnosis of IE
  - **Pooled sensitivity 76.8%** (95% CI 71.8–81.4%); **pooled specificity 77.9%** (95% CI 71.9–83.2%)
  - PV IE: sensitivity **80.5%** (95% CI 74.1–86.0); pooled specificity **73.1%** (95% CI 63.8–81.2%)

Journal of Nuclear Cardiology 2017; doi:10.1007/s12350-017-1092-8

Role of ^{18}F-FDG PET in Patients with Infectious Endocarditis

Martha Kestler[1,2], Patricia Muñoz[1,3], Marta Rodríguez-Créixems[1], Amanda Rotger[4], Felisa Jimenez-Requena[4], Amaia Mari[4], Javier Orcajo[4], Luis Hernández[5], Juan C. Alonso[4], and Emilio Bouza[1,3], in collaboration with the Spanish Group for the Management of Infectious Endocarditis (GAMES)

- The validity values for efficacy of PET-CT for the diagnosis of **infectious embolisms*** were as follows:
  - **Sensitivity 100%**
  - **Specificity 80%**
    - 3 FP (6.4%): abnormal uptake on their initial PET-CT not subsequently confirmed (left radius, diaphragm, and soft tissue)
  - Positive predictive value 90%
  - Negative predictive value 100%

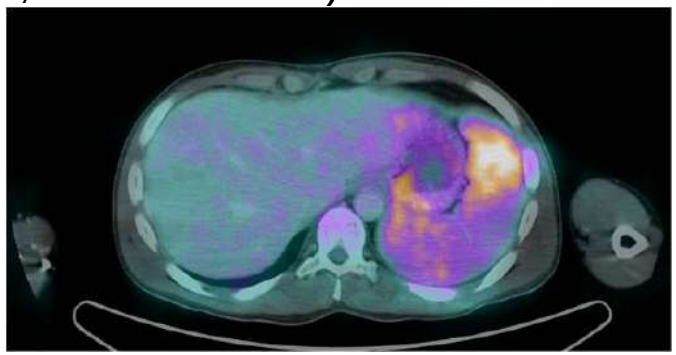

J Nucl Med 2014; 55:1–6

* Incidental non-infectious findings excluded

Util en EI VP y DIC

Table 6. Diagnostic Performance of the DC at Admission, PET/CT, and DC+PET/CT in Prostheses (n=64) and Devices (n=28) Relative to the IE Unit Final Diagnosis

	DC	PET/CT*	DC+PET/CT
Sensitivity (95% CI), %			
Prosthetic valves	51.3 (34.8–67.6)	87.2 (72.6–95.7)	89.7 (75.8–97.1)
Devices	50 (24.7-75.3)	87.5 (61.7–98.4)	93.8 (69.8–99.8)
Specificity (95% CI), %			
Prosthetic valves	92 (74–99)	92 (74–99)	88 (68.8–97.5)
Devices	100 (73.5–100)	100 (73.5–100)	100 (73.5–100)
Positive predictive value (95% CI), %			
Prosthetic valves	90.9 (71.9–97.5)	94.5 (81.8–98.5)	92.1 (80.1–97.1)
Devices	100 (75–100)	100 (75–100)	100 (75–100)
Negative predictive value (95% CI), %			
Prosthetic valves	54.7 (46.2–63)	82.1 (66.7–91.3)	84.6 (68.2–93.3)
Devices	60.1 (48–71.1)	85.8 (62.3–95.7)	92.3 (64.4–98.8)

- Diagnóstico alternativo en 19/35 casos con EI rechazada

DC: Duke criteria

Pizzi M. Circulation. 2015; 132: 1113-26

ORIGINAL RESEARCH ARTICLE

Improving the Diagnostic Performance of ^{18}F-Fluorodeoxyglucose Positron-Emission Tomography/Computed Tomography in Prosthetic Heart Valve Endocarditis

Bioglue PCR >40

Editorial, see p 1428

Laurens E. Swart, MD*
Anna Gomes, MD, PhD*

- 160 pts VP y sospecha de EI y 77 pts VP con otra indicación de PET
- Re-evaluación restrospectiva por experto
  - **S 74%** /specificity 91% / PPV 89% /NPV 78%,
- Confounders
  - **Low inflammatory activity (C-reactive protein <40 mg/L)** at the time of imaging
  - Use of **surgical adhesives** during prosthetic heart valve implantation
- **After exclusion of confounders: S 91%/SP 95%/PPV 95%/ NVP91%**
- **SUV ≥2.0** was a 100% sensitive and 91% specific predictor of PVE (not so silly useless value anymore!!!)

Circulation. 2018;138:1412–1427. DOI:10.1161/CIRCULATIONAHA.118.035032

PET-TC 18FDG

- Buena disponibilidad. Alta sensibilidad para 1) válvulas protésicas (implante > 1-2 m); 2) focos embolígenos. 3) Inf herida quirúrgica y cable de dispositivos cardiacos.
- Relativo alto coste. Alto nivel de radiación. Requiere preparación dietética.
- No tan útil para válvula nativa.
- El empleo de PET asociado a TC cardiaco sincronizado aumenta la potencia diagnóstica.

Radiología nuclear

SPECT/TC

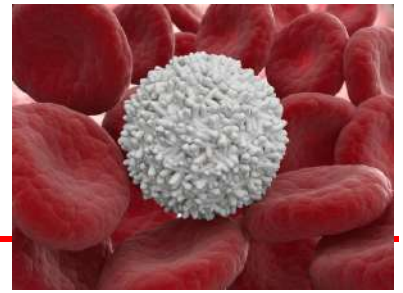

La **Escintigrafía (SPECT-TC)**: *single photon emission tomography and CT with technetium99m-hexamethylpropyleneamineoxime—labeled leukocytes (99mTc-HMPAO-SPECT/CT)*

SPECT

-Emplea leucocitos marcados con radiotrazadores (^{99}Tc-HMPAO) que liberan directamente radiación gamma.

-Técnica **barata**.

-**Específica** para la detección de áreas de infección activa.

-**Menor radiación** que PET.

-Detección a las 2 y a las 24 horas.

-Requiere manejo de hemoderivados.

TC

-Topograma de baja resolución.

-Escasa radiación.

Radiología nuclear

SPECT/TC

Added Value of ^{99m}Tc-HMPAO–Labeled Leukocyte SPECT/CT in the Characterization and Management of Patients with Infectious Endocarditis

Paola A. Erba[1], Umberto Conti[2], Elena Lazzeri[1], Martina Sollini[1], Roberta Doria[3], Salvatore M. De Tommasi[4], Francesco Bandera[2], Carlo Tascini[3], Francesco Menichetti[3], Rudi A.J.O. Dierckx[6], Alberto Signore[6,7], and Giuliano Mariani[1]

[1]*Regional Center of Nuclear Medicine, University of Pisa Medical School, Pisa, Italy;* [2]*Laboratory of Echocardiography, Cardiology Unit, Azienda Ospedaliero-Universitaria Pisana, Pisa, Italy;* [3]*Infectious Disease Department, Azienda Ospedaliero-Universitaria Pisana, Pisa, Italy;* [4]*Cardiology Department, Azienda Ospedaliero-Universitaria Pisana, Pisa, Italy;* [5]*Cardiovascular Department "E. Malan," IRCCS Policlinico San Donato Milanese, Milan, Italy;* [6]*Nuclear Medicine and Molecular Imaging Department, University Medical Center Groningen, Groningen, The Netherlands; and* [7]*Nuclear Medicine Unit, S. Andrea Hospital, University of Rome, Rome, Italy*

Erba et al. (J Nucl Med 2012). Retrospectivo. n = 131 pacientes con sospecha de EI sobre **válvula nativa o protésica.** GS: Criterios de Duke evolutivamente.

- Diagnóstico de endocarditis infecciosa: **S 90, E 100**, VPP 100, VPN 94.
- Detección de embolismos sépticos: **S 77, E 81**, VPP 90, VPN 61.
- Permite diagnóstico de EI definitiva en un **13%** de pacientes con EI probable.

Trine et al (Int J Cardiovasc Imaging, 2017). Retrospectivo. n = 55 pacientes con diagnóstico definitivo de EI (sobre válvula nativa y/o protésica).

- PET vs SPECT en la detección de **embolismos extracardiacos.**
- PET: 32 + (91 focos). **2.8 focos** por paciente con resultado positivo.
- SPECT: 24 + (37 focos). **1.6 focos** por paciente

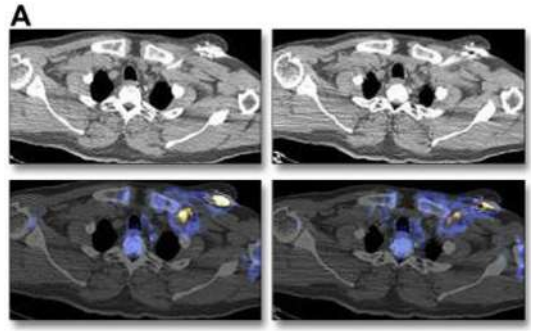

JACC: CARDIOVASCULAR IMAGING
VOL. 6, NO. 10, 2013
ISSN 1936-878X/$36.00
http://dx.doi.org/10.1016/j.jcmg.2013.08.001

Radiolabeled WBC Scintigraphy in the Diagnostic Workup of Patients With Suspected Device-Related Infections

Paola A. Erba, MD,*† Martina Sollini, MD,† Umberto Conti, MD,‡ Francesco Bandera, MD,‡ Carlo Tascini, MD,§ Salvatore M. De Tommasi, MD,‡ Giulio Zucchelli, MD,‡ Roberta Doria, MD,§ Francesco Menichetti, MD,§ Maria Grazia Bongiorni, MD,‡ Elena Lazzeri, MD, PhD,*† Giuliano Mariani, MD*†
Pisa and Reggio Emilia, Italy

Erba et al. JACC 2013. Retrospectivo. n = 63 pacientes con sospecha de infección asociada a **dispositivos intracardiacos:**

-SPECT vs diagnóstico en seguimiento a 12 meses (**S 94, E 100**, VPP 100, VPN 94)

-Mayor S que la ecocardiografía para inf **accesos vasculares y cable de dispositivo.**

-**Permite descartar infección asociada a dispositivo** en todos los casos con fiebre en el postimplante de dispositivo cardiaco.

Radiología nuclear

SPECT/TC

Hiafil et al (Eur J Cardiovasc Imaging, 2013). Retrospectivo. n = 42 pacientes con sospecha de EI sobre **prótesis valvular** con ecocardiografía no diagnóstica:

- Buen rendimiento para diagnóstico de complicaciones perivalvulares.
- Los sujetos con SPECT positivo se sometieron en mayor proporción a cirugía (43% vs 11%)

Estudio comparativos PET/TC vs SPECT en diagnóstico de endocarditis infecciosa sobre válvula protésica:

Francois Rouzet et al (J Nucl Med, 2014). Retrospectivo. 39 pacientes con sospecha EI sobre válvula **protésica y ecocardiografía no concluyente**. GS: Criterios de Duke a los 3 meses.

- **Concordancia PET/SPECT 69%.**
- PET/TC: **S 93, E 71**, **VPP 68**, VPN 80.
- SPECT/TC: **S 64, E 100**, **VPP100**, VPN 81.

Falsos **negativos** del SPECT: relación con agentes no piogénicos (Coxiella, Candida).

Falsos **positivos** PET: inflamación en postoperatorio de Svprotésica (< 2 meses).


Role of radiolabelled leucocyte scintigraphy in patients with a suspicion of prosthetic valve endocarditis and inconclusive echocardiography


Respective Performance of ^{18}F-FDG PET and Radiolabeled Leukocyte Scintigraphy for the Diagnosis of Prosthetic Valve Endocarditis

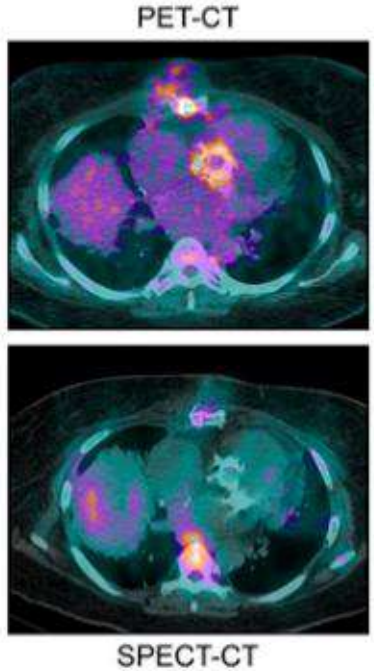

SPECT-TC

- Menor disponibilidad. Requiere manejo de hemoderivados. Al menos dos visitas del paciente.

- **Mayor especificidad que PET/TC en diagnóstico de EI. IDEAL para pruebas CERCA DE LA CIRUGÍA**
- Menor coste. Menor radiación. Bien tolerado. No requiere preparación
- Buen rendimiento para infecciones asociadas a dispositivos cardiacos.

TC Cardiaco sincronizado

Características generales

Utiliza radiación X de forma selectiva a lo largo del ciclo cardiaco guiado por ECG.

Características:

-Requiere cooperación mínima por parte del paciente.

-Requiere empleo de contraste.

-Permite obtener **imágenes estructurales cardiacas y vasculares con** detalle.

-Permite la **valoración de arterias coronarias** de forma preoperatoria.

Valor en diagnóstico de endocarditis sobre válvula nativa

Feuchtner et al (JACC, 2009).

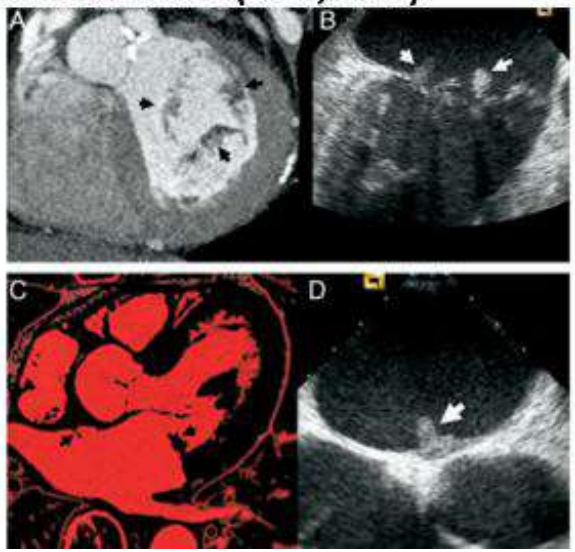

1) Vegetaciones sobre válvula mitral.
2) Vegetación. Abceso perivalvular

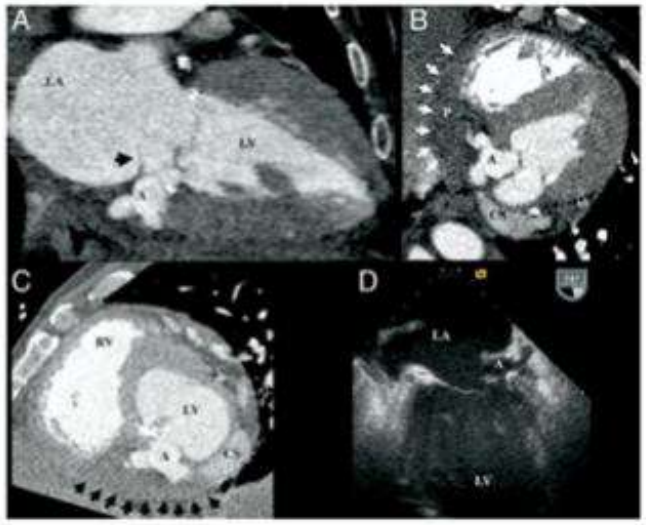

TC Cardiaco sincronizado

Valor en diagnóstico de endocarditis sobre válvula protésica

Fagman et al (Eur Radiol. 2012). Prospectivo. n = 62 pacientes con EI sobre **prótesis valvular aórtica** diagnosticada por **ecocardiografía**.

TC cardiaco demostró **S del 93%.**

-Correlación ETE –TC cardiaco (índice Kappa):

- Dehiscencia 0.75 (0.48-1.0)
- Abceso 0.68 (0.40-0.97)
- Vegetación 0.55 (0.26-0.88).

Eur Radiol (2012) 22:2407–2414
DOI 10.1007/s00330-012-2491-5

CARDIAC

ECG-gated computed tomography: a new role for patients with suspected aortic prosthetic valve endocarditis

Erika Fagman · Sossio Perrotta · Odd Bech-Hanssen · Agneta Flinck · Carl Lamm · Lars Olaison · Gunnar Svensson

Habets et al (Int J Cardiovasc Imaging 2014). Prospectivo. n = 28 pacientes con sospecha de EI sobre prótesis valvular.

-**S: 100%.** E: 83%.

-**Mayor** potencia para detección de **aneurismas micóticos**. Menor para detección de vegetaciones, dehiscencias y abcesos.

-Los hallazgos por TC producen cambio significativo en el manejo en el 25% de los pacientes.

Cardiac computed tomography angiography results in diagnostic and therapeutic change in prosthetic heart valve endocarditis

Jesse Habets · Wilco Tanis · Lex A. van Herwerden · Renee B. A. van den Brink · Willem P. Th. M. Mali · Bas A. J. M. de Mol · Steven A. J. Chamuleau · Ricardo P. J. Budde

Received: 28 August 2013 / Accepted: 19 November 2013 / Published online: 30 November 2013

TAC cardíaco sincronizado

- Buena disponibilidad. Bien tolerado. No requiere preparación.
- Alta correlación con ETE. Mayor sensibilidad para detección de **aneurismas micóticos**.
- **Complemento Dx** (tb ECO 3D) y **PREPARACIÓN CIRUGÍA (coronarias)**.

- Menor utilidad para detección de vegetaciones, dehiscencias y abcesos.

RM cardiaca

Evidencia limitada.

Dursun et al. (Diagn Interv Radiol. 2015).

The utility of cardiac MRI in diagnosis of infective endocarditis: preliminary results

Memduh Dursun, Sabri Yılmaz, Erdem Yılmaz, Ravza Yılmaz, İmran Onur, Hüseyin Oflaz, Aygün Dindar

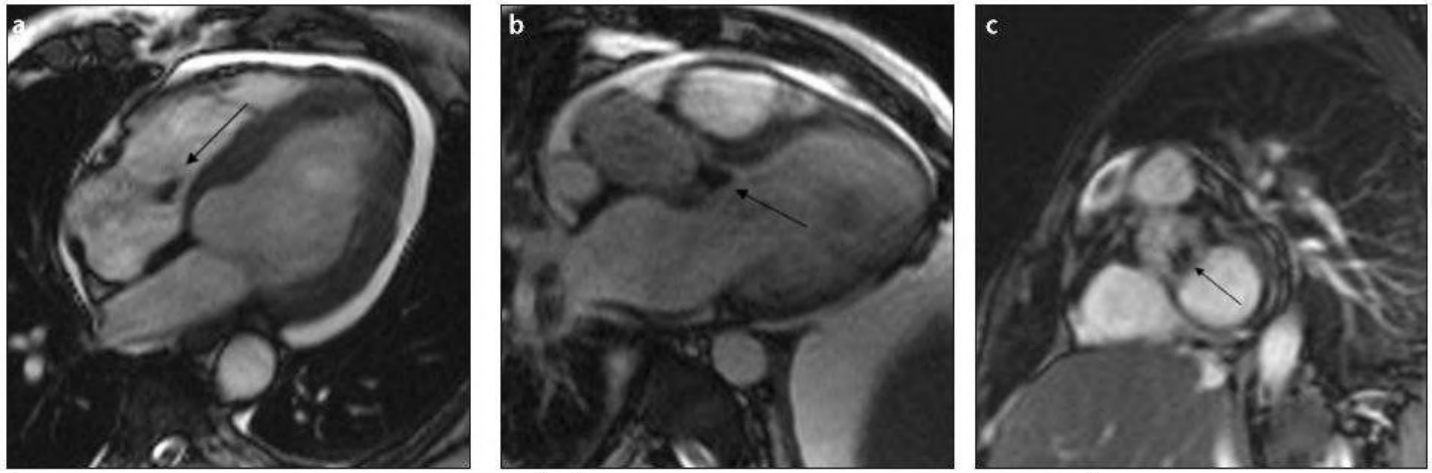

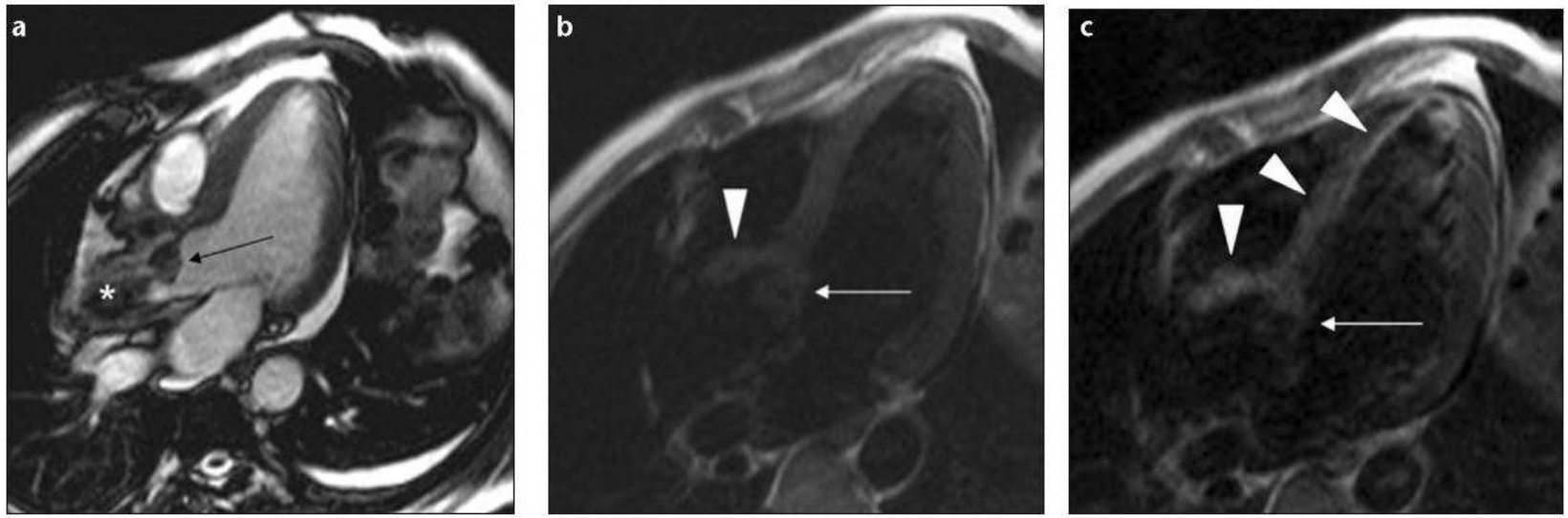

Métodos diagnósticos de EI

	PET-TC 18FDG	SPECT	TAC cardíaco	RM
Válvula nativa	✗	✓	✓	✓
Válvula protésica	✓	? ✓	✓	?
DIC	✓	✓	✗	✗
Embolismos sistémicos	✓	✗	✗	✗

Diagnostic value of imaging in infective endocarditis: a systematic review

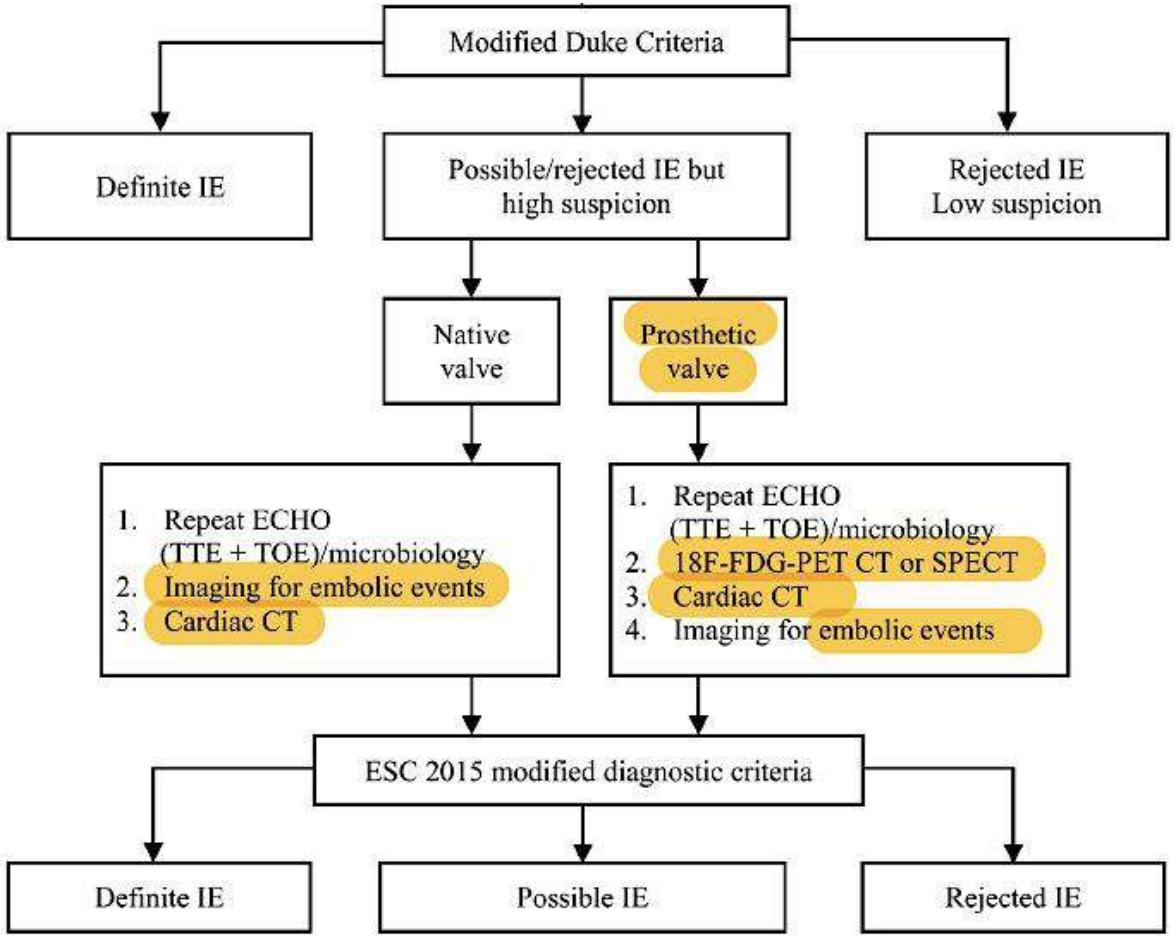

Figure 1. Diagnostic criteria for infective endocarditis. Taken from the 2015 European Society of Cardiology (ESC) guidelines for the management of infective endocarditis (IE)[9]. 18F-FDG PET, 18F-fluorodeoxyglucose positron emission tomography; CT, computed tomography; ECHO, echocardiogram; SPECT, single-photon emission computed tomography; TOE, transoesophageal echocardiography; TTE, transthoracic echocardiography.

Harding D. F1000Research 2018, 7(F1000 Faculty Rev):674
(doi: 10.12688/f1000research.13791.1

Diagnostic value of imaging in infective endocarditis: a systematic review

- Metaanálisis (EI naturales y protésicas)
  - F18FDG-PET/TAC (24), SPECT leucocitos marcados (5), ECG-angioTAC (3).
  - 19 prospectivos.
- Conclusiones:
  - Lo ideal es utilizar varias técnicas radiológicas para complementar los hallazgos clínicos, microbiológicos y radiológicos
  - PET-TAC: mayor **sensibilidad** en diagnóstico de EVP, dispositivos y lesiones extracardiacas.
  - SPECT: mayor **especificidad** en EVP precoces y lesiones extracardiacas.
  - AngioTAC: util en EVN, complicaciones perianulares. Detalles anatómicos.

Gomes et al. Lancet Infect Dis 2017

	TEE	ECG-gated MDCTA	ECG-gated MRI	^{18}F-FDG PET/CT	Leucocyte scintigraphy with SPECT/CT
Contraindications	Oesophageal pathology	Pregnancy, iodinated contrast allergy, renal insufficiency (eGFR <60 mL/min per 1·73m²)	Pregnancy, most ICDs and pacemakers, gadolinium allergy, arenal insufficiency (eGFR <30 mL/min per 1·73m²), claustrophobia	Pregnancy, uncontrolled diabetes	Pregnancy, low leucocyte count
Patient preparation	4–6 h fasting	2 h fasting, intravenous contrast	Intravenous contrast	≥6 h fasting, 24 h low-carbohydrate, fat-allowed diet	Laborious preparation involving drawing and reinjection of leucocytes
Monitoring of unstable patients possible	Good	Moderate	Moderate	Moderate	Moderate
Anatomical vs functional	Anatomical images, functional data (motion)	Detailed anatomical images	Detailed anatomical images, functional data (oedema)	Functional data (molecular)	Functional data (molecular)
Anatomical resolution	Good	Very good	Good	Good	Sufficient
ECG gating required	Not applicable	Yes	Yes	Yes	No
Duration	30 min	15 min	≥30 min	80 min (60 min preparation, 20 min scan time)	24 h (four visits, two scans)
Radiation dose	None	High (10 mSv)	None	Moderate (4 mSv)	Moderate (4 mSv)
Quantification possibilities	Possible	Not possible	Excellent	Good	Possible
Diagnostic accuracy	Sensitive and specific	Sensitive and specific	Unclear	Sensitive	Specific
Susceptibility to artifacts	Metallic (very susceptible)	Metallic (moderately susceptible)	Metallic (moderately susceptible), cardiac and respiratory (moderately susceptible)	Cardiac and respiratory (slightly susceptible)	Metallic (slightly susceptible)
Suitability for therapy monitoring	Suitable	Not suitable	Unclear	Very suitable	Dependent on situation
Availability	Widely available	Widely available	Moderately available	Moderately available	Limited availability
Costs	Approximately €100	€300–400	€500–800	€800–1200	€600–800
Limitations	Completely operator-dependent analysis	Frequent contraindications	Noisiness for patients	Pathological conditions mimicking pattern of focally increased uptake, difficulty to discriminate aseptic inflammation from infectious process (insufficient clear interpretation criteria)	Limited visibility of smaller infections or vegetations (<1 cm) because of limited anatomical resolution

Gomes A. Lancet Infect Dis 2017; 17: 1-14

Muchas gracias

- Ana Alvarez Uría
- Juan Carlos López-Azor García

Grupos de Apoyo al Manejo de la Endocarditis Infecciosa en España

SaludMadrid
Comunidad de Madrid