Ponente: **Manuel Martínez-Sellés**

Servicio de Cardiología HGUGM

11.¿En qué paciente y en qué momento debe realizarse una RMN o TAC cardíaco?

12.¿Cuándo está indicado realizar una gammagrafía cardíaca con leucocitos marcados?

Tomografía Computorizada (TC)

- **Fiabilidad para detectar daño intracardíaco:**
  - Extensión perivalvular
  - Pseudoaneurismas
  - Abscesos
  - Fístulas
- **↑sensibilidad complicaciones (peri)valvulares**
- **Gran resolución espacial**

SEICAV
Sociedad Española de Infecciones Cardiovasculares

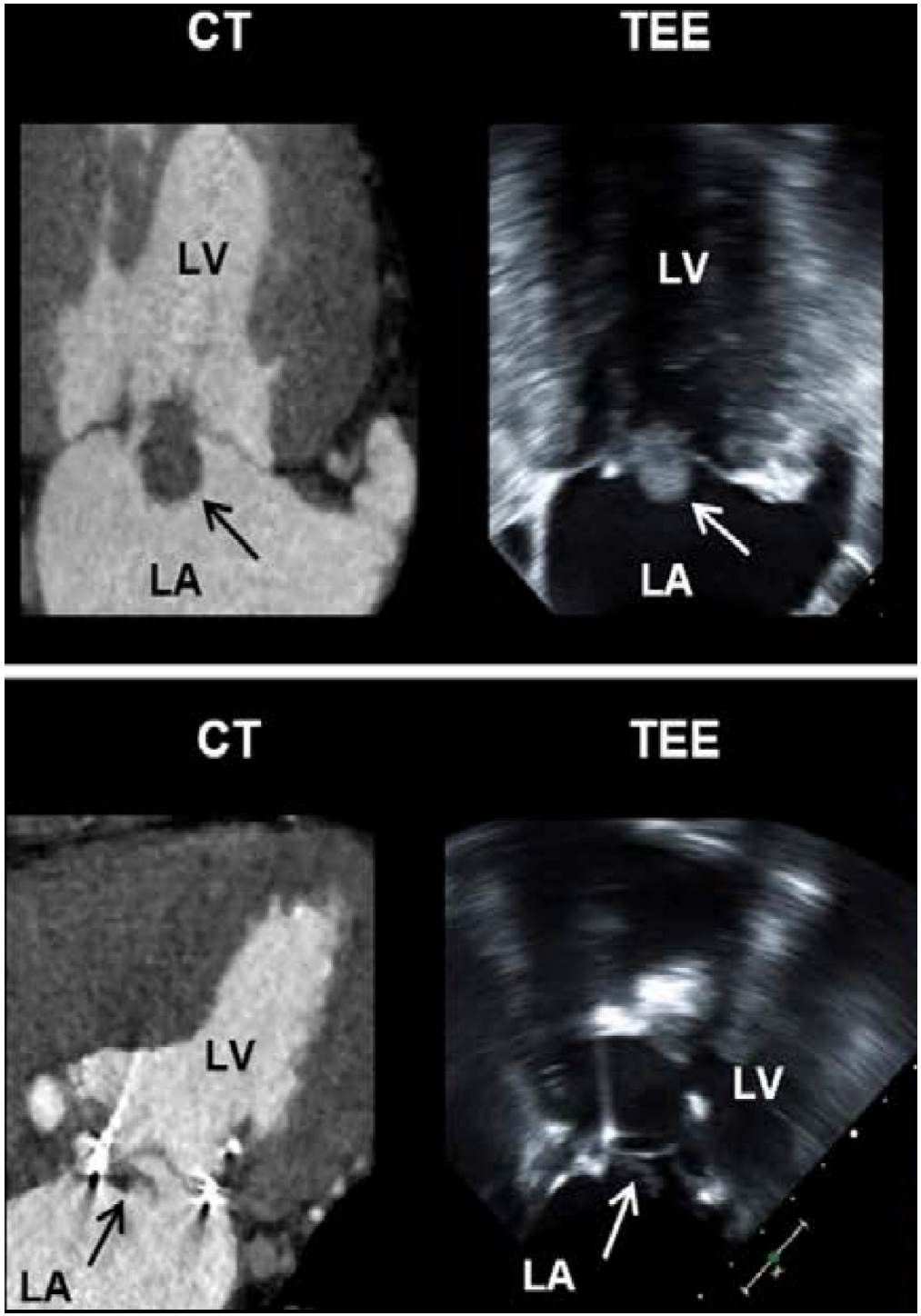

Kim.
Circ Cardiovasc Imaging. 2018

SEICAV
Sociedad Española de Infecciones Cardiovasculares

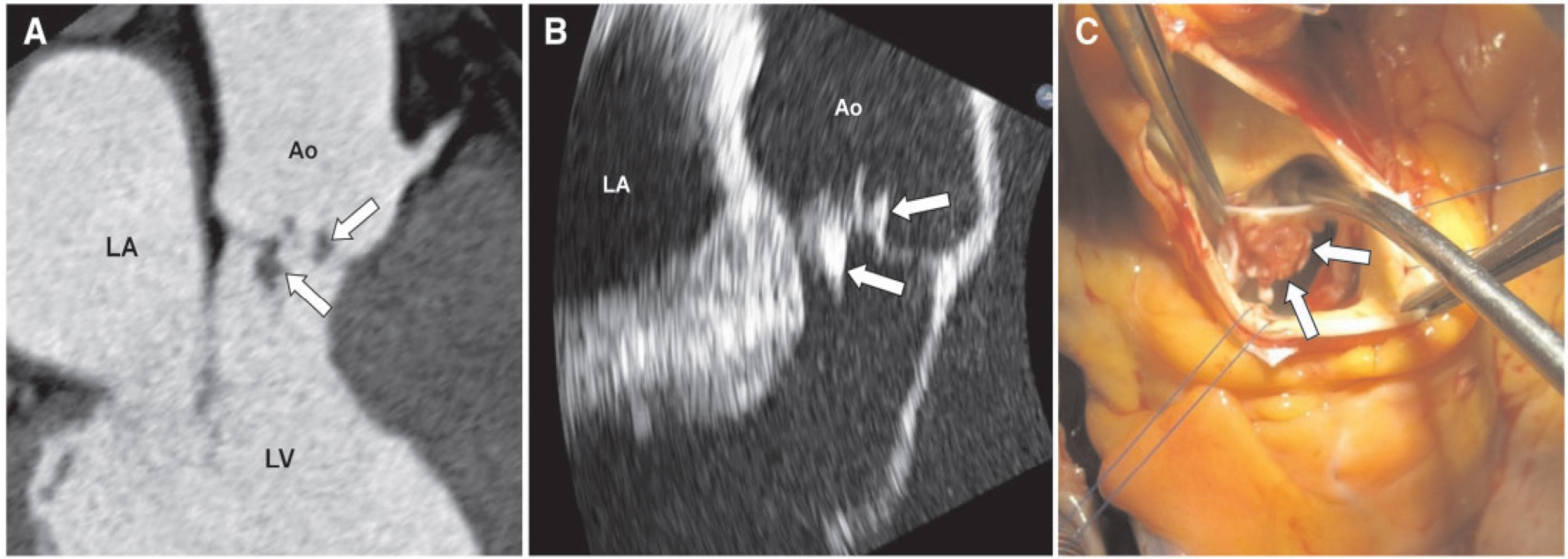

A 60-year-old man with infective endocarditis. (*A*) A three-chamber view of the aortic valve with CT showing low-density vegetation (arrows) attached to the right and left coronary cusps. (*B*) A three-chamber view of the aortic valve on echocardiography showing echogenic vegetation (arrows) in the same areas identified by CT. (*C*) Vegetation (arrows) was noted in the right and left coronary cusps during surgery.

Koo. Eur Heart J Cardiovasc Imaging. 2018

SEICAV
Sociedad Española de Imagen Cardiovascular

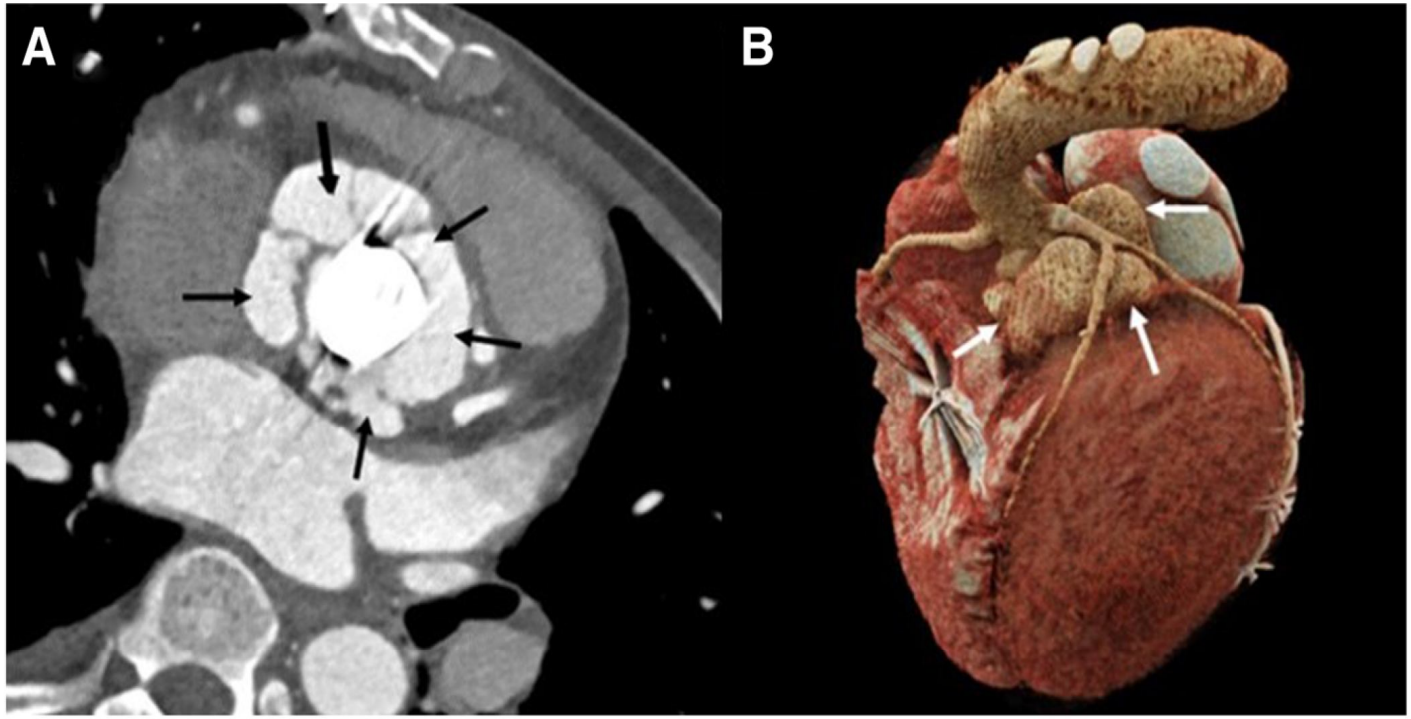

A 43-year-old man with a mechanical aortic valve. An aortic valve view (**a**) and cinematic reconstruction image (**b**) of cardiac CTA showing multiple paravalvular pseudoaneurysms (arrows). Noted the left anterior descending artery was located just above the pseudoaneurysm which demonstrated clearly by cardiac CTA. The pseudoaneurysm could not be detected on TTE due to the shadowing of the mechanical aortic valve

Chaosuwannakit. J Cardiothorac Surg. 2019

SEICAV
Sociedad Española de Infecciones Cardiovasculares

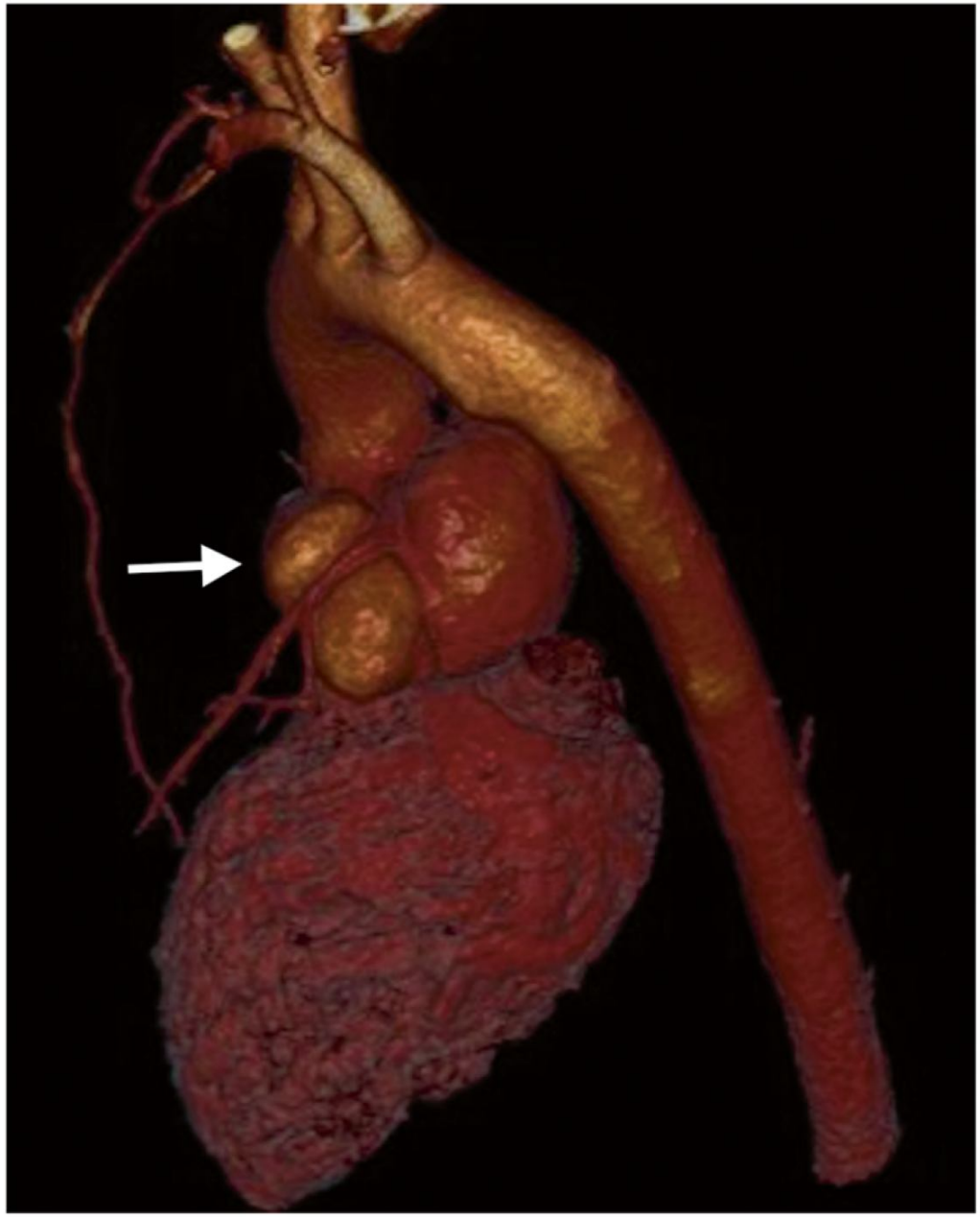

Hryniewiecki T. Eur Radiol. 2019

Pseudoaneurysm of the left ventricular outflow tract (arrow)

SEICAV
Sociedad Española de Infecciones Cardiovasculares

TC: situaciones particulares

- **Derecha:** Pulmón embolismo séptico, absceso e infarto
- **Aórtica:** Válvula y Aorta tamaño, anatomía y calcificación
- **Contraindicación para eco transesofágico**
- **Valorar enfermedad coronaria**

SEICAV
Sociedad Española de Infecciones Cardiovasculares

TC: Algoritmo de coronariografía no invasiva

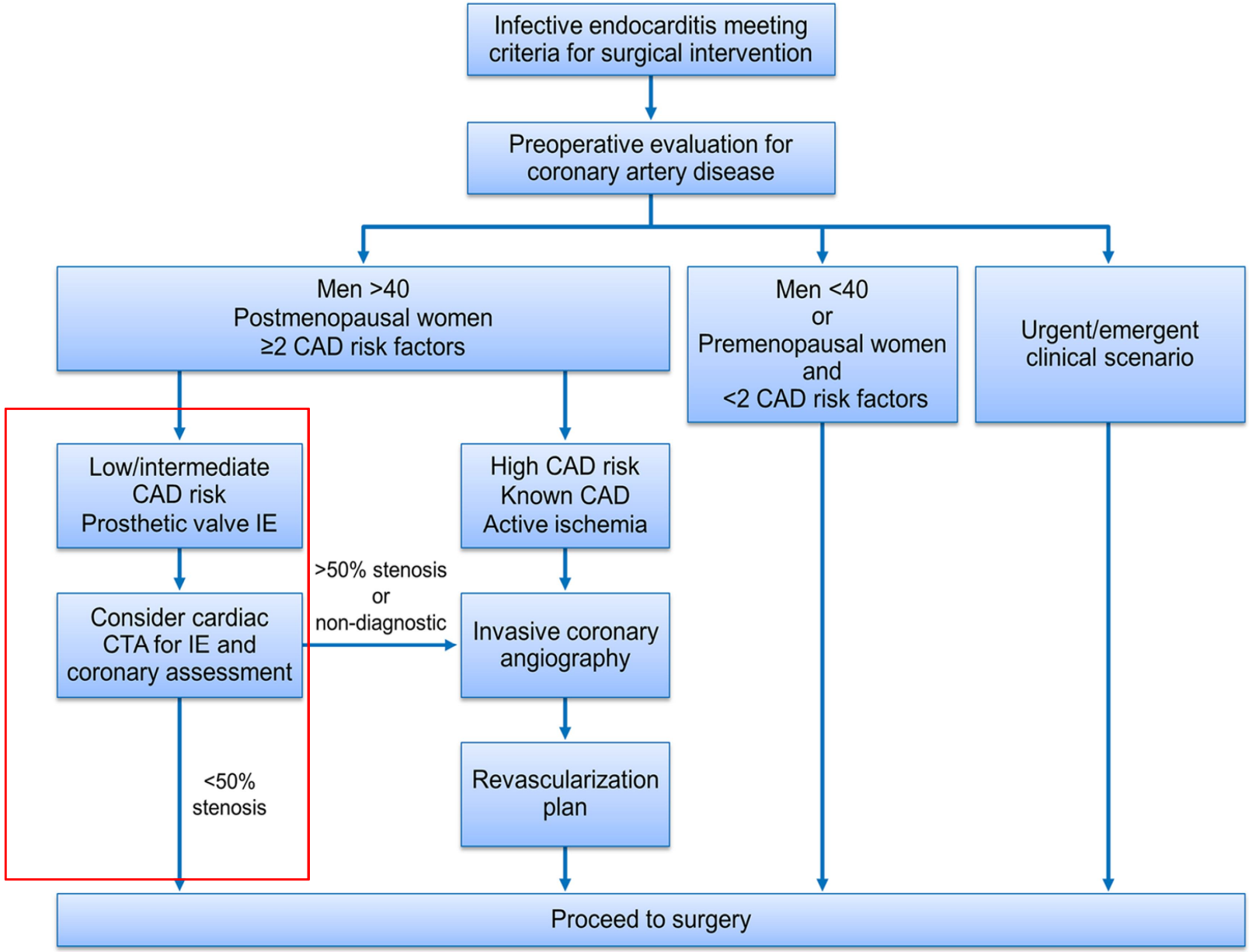

Sims. Int J Cardiovasc Imaging. 2018

Cardio Resonancia Magnética

- Otra alternativa para detectar vegetaciones
- Extensión paravalvular y afectación endotelial
- Pocos datos sobre su utilidad

SEICAV
Sociedad Española de Infecciones Cardiovasculares

Medicina Nuclear Cardíaca

- **Pruebas de imagen negativas o no concluyentes**
- **No diagnóstico microbiológico**
- **Fase temprana, sobre todo en prótesis valvulares**
- **Dispositivos (MP, DAI y RSC)**
- **¿Monitorización respuesta TTo AB?**
- **Precaución al interpretar:**

- cirugía cardíaca reciente
- trombos activos
- placas ateroscleróticas blandas
- Vasculitis
- tumores cardíacos primarios
- metástasis cardíacas
- reacciones a cuerpos extraños

SEICAV
Sociedad Española de Infecciones Cardiovasculares

Las técnicas son complementarias

	TEE	ECG-gated MDCTA	ECG-gated MRI	^{18}F-FDG PET/CT	Leucocyte scintigraphy with SPECT/CT
Contraindications	Oesophageal pathology	Pregnancy, iodinated contrast allergy, renal insufficiency (eGFR <60 mL/min per 1·73m^2)	Pregnancy, most ICDs and pacemakers, gadolinium allergy, arenal insufficiency (eGFR <30 mL/min per 1·73m^2), claustrophobia	Pregnancy, uncontrolled diabetes	Pregnancy, low leucocyte count
Patient preparation	4–6 h fasting	2 h fasting, intravenous contrast	Intravenous contrast	≥6 h fasting, 24 h low-carbohydrate, fat-allowed diet	Laborious preparation involving drawing and reinjection of leucocytes
Monitoring of unstable patients possible	Good	Moderate	Moderate	Moderate	Moderate
Anatomical *vs* functional	Anatomical images, functional data (motion)	Detailed anatomical images	Detailed anatomical images, functional data (oedema)	Functional data (molecular)	Functional data (molecular)
Anatomical resolution	Good	Very good	Good	Good	Sufficient
ECG gating required	Not applicable	Yes	Yes	Yes	No
Duration	30 min	15 min	≥30 min	80 min (60 min preparation, 20 min scan time)	24 h (four visits, two scans)
Radiation dose	None	High (10 mSv)	None	Moderate (4 mSv)	Moderate (4 mSv)
Quantification possibilities	Possible	Not possible	Excellent	Good	Possible
Diagnostic accuracy	Sensitive and specific	Sensitive and specific	Unclear	Sensitive	Specific
Susceptibility to artifacts	Metallic (very susceptible)	Metallic (moderately susceptible)	Metallic (moderately susceptible), cardiac and respiratory (moderately susceptible)	Cardiac and respiratory (slightly susceptible)	Metallic (slightly susceptible)
Suitability for therapy monitoring	Suitable	Not suitable	Unclear	Very suitable	Dependent on situation
Availability	Widely available	Widely available	Moderately available	Moderately available	Limited availability
Costs	Approximately €100	€300–400	€500–800	€800–1200	€600–800
Limitations	Completely operator-dependent analysis	Frequent contraindications	Noisiness for patients	Pathological conditions mimicking pattern of focally increased uptake, difficulty to discriminate aseptic inflammation from infectious process (insufficient clear interpretation criteria)	Limited visibility of smaller infections or vegetations (<1 cm) because of limited anatomical resolution

Gomes. Lancet Infect Dis. 2017

Algoritmo en válvulas nativas

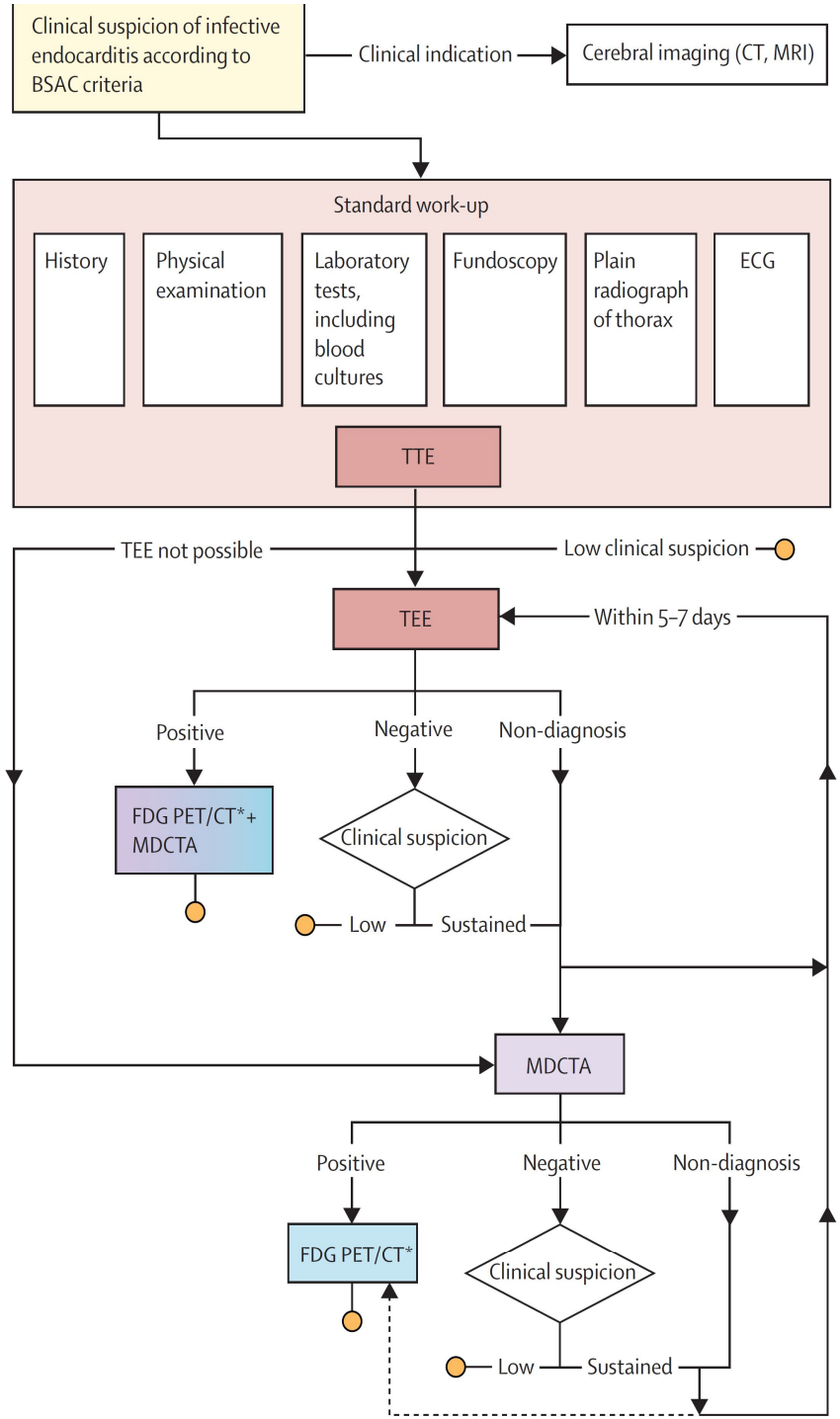

Gomes. Lancet Infect Dis. 2017

Algoritmo en protésicas

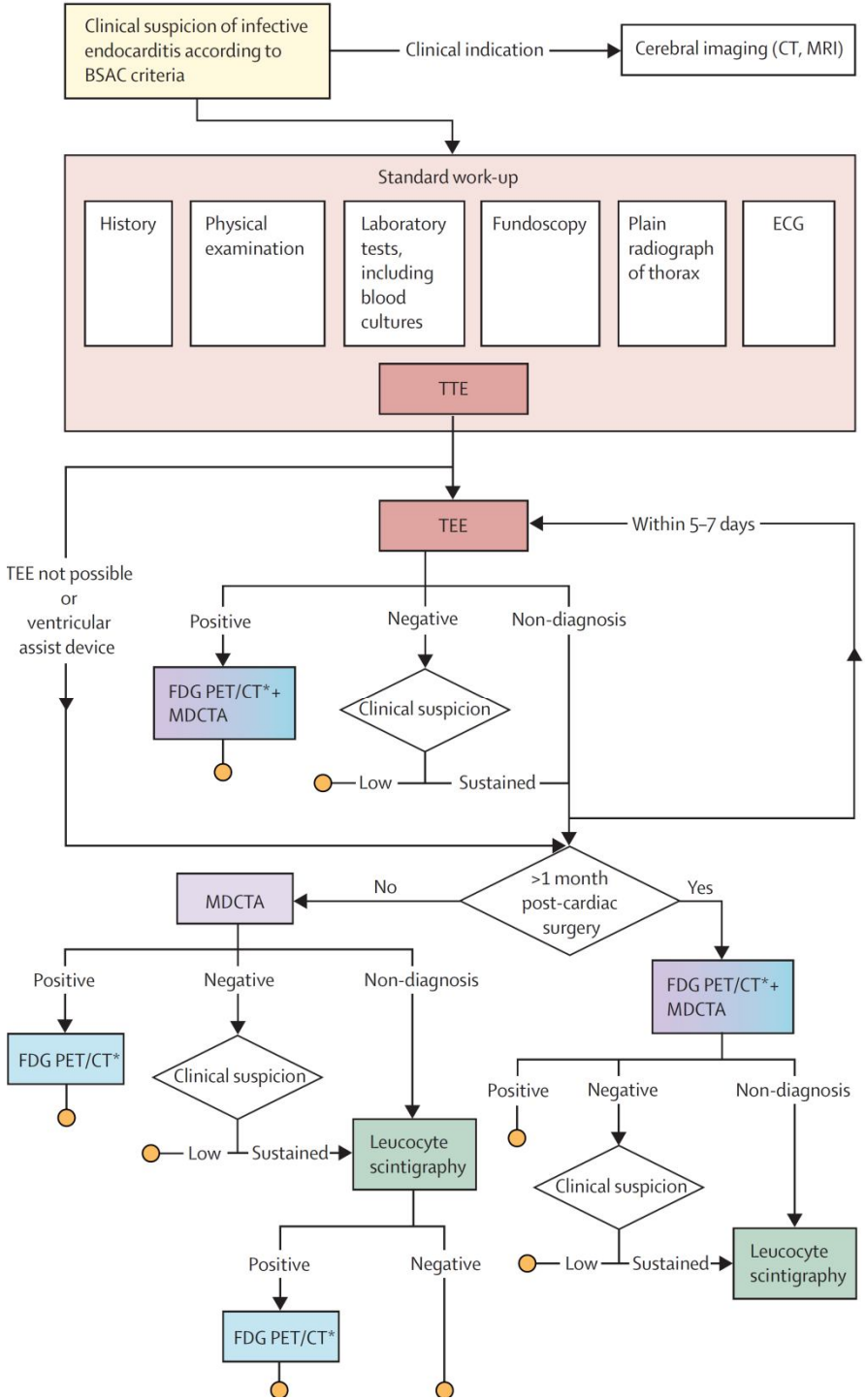

Gomes. Lancet Infect Dis. 2017